

Masterclass in Oral Diseases

Oral Cancer

with

Prof Willie F. P. van Heerden¹

Dr Andre W van Zyl²

Prof Wynand P. Dreyer³



Oral Cancer - A Clinical Update

¹ Willie F. P. van Heerden

Professor emeritus, Dept of Oral and Maxillofacial Pathology, UP: Pathcare Vermaak Laboratories, Pretoria
BChD, MChD, FC Path(SA), PhD, DSc, MASSAf

² Andre W. van Zyl

MChD (Oral Medicine & Periodontics)
Private Practice, Hermanus, South Africa

³Wynand P. Dreyer

Professor emeritus, Oral Medicine and Periodontics, Stellenbosch University. Specialist in Oral Medicine and Periodontics. BDS (Wits), HDD (Wits), PhD (Stellenbosch), FCD(SA)OMP

Introduction

Oral cancer remains one of the most life changing cancers. Early diagnosis of such lesions can assist in ensuring a successful outcome whereas the late diagnosis could lead to debilitating surgery and often a low 5-year survival rate.¹ The oral health care worker routinely examines the oral cavity and should therefore be in a position to recognize oral cancers at an early stage. However, such lesions are often missed during routine dental treatment or mis-diagnosed as denture induced trauma or the result of a sharp tooth edge. In such cases, after removal of the identified cause, the lesion should heal within 2-3 weeks, at most. Therefore, such patients must be followed-up and, if the lesion does not heal timeously, it should be considered as potentially harmful and examined by means of a biopsy to ensure a diagnosis. Delays in ensuring a definitive diagnosis may impact negatively on the survival/prognosis of the patient. Thus, any ulcer, unidentified lump or white/red lesion should be biopsied if it does not disappear within 2-3 weeks. Moreover, all patients who fall in a high-risk group (over 40 years of age; tobacco and alcohol users) should be thoroughly examined at every opportunity for potentially malignant lesions or the presence of incipient oral cancer.¹ E-cigarette use (vaping) has become popular due to the fact that it is considered to be a safer option than cigarettes. There is, however, no hard evidence that this is indeed the case.² Until the matter has been critically assessed and the long-term effect of vaping on the oral tissues is known, it should be treated as a high risk habit.

Oral cancer has a higher incidence in developing countries and varies from the sixth to the eight position in the incidence of all cancers.³ Oral health care workers are in the position to save lives and should never underestimate the importance of this duty, nor neglect their professional responsibility in this regard.

Oral cancer or oral squamous carcinoma?

The oral cavity is lined by stratified squamous epithelium; hence cancerous transformation of this epithelium is correctly termed a squamous cell carcinoma. The term oral cancer (OC) is frequently used, especially in the lay press, as a synonym for oral squamous cell carcinoma (OSCC). This is obviously incorrect as oral cancer refers to any malignancy of the oral cavity. Oral cancer may be one of several other oral malignancies such as adenocarcinomas of salivary gland origin, haematological malignancy or any one of the lymphomas, or a mesenchymal malignancy such as rhabdomyosarcoma (skeletal muscle malignancy). However, squamous cell carcinoma is by far the most common malignancy of the oral cavity (more than 90%), contributing to the generalised use of the term "oral cancer".^{1,3}

Clinical variants

OSCC may present in a diversity of different forms, some linked to a specific histological subtype. The diagnosis of OSCC should always be confirmed histologically as there are clinical similarities with benign, infective and traumatic lesions. This is especially true for early OSCC lesions which may present clinically as a potential malignant lesion, the most common being leukoplakia (white lesions) (Fig 1)

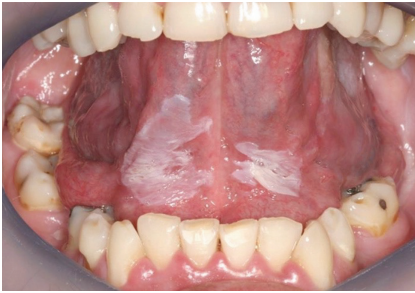

Figure 1: White lesions of the ventral aspect of the tongue and floor of mouth must be examined histologically. It is a high-risk area for OSCC.

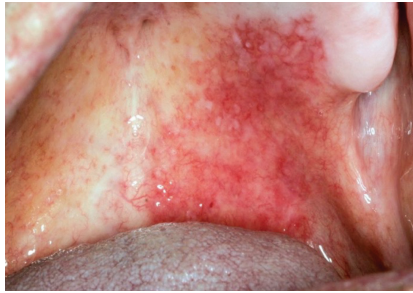

Figure 2: Red lesions on the palate may be easy to identify, but red lesions on floor of the mouth or posterior region of the soft palate are more difficult to discover. The lesion depicted in this photograph was diagnosed histologically as OSCC.

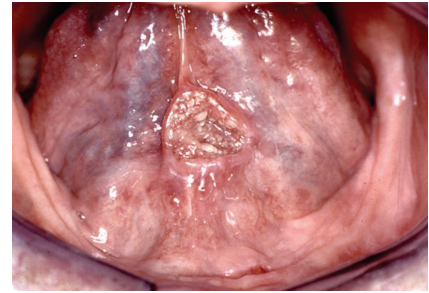


Figure 3: A small malignant ulcer in anterior floor of mouth. These ulcers may show induration and are generally not fixated in its early stage. Palpate the lesion and move it from side to side to determine if it is fixated.

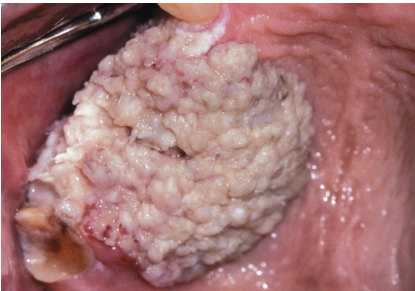

Figure 4: Wart-like (verrucous) carcinoma of the palatal area with a pronounced white surface.

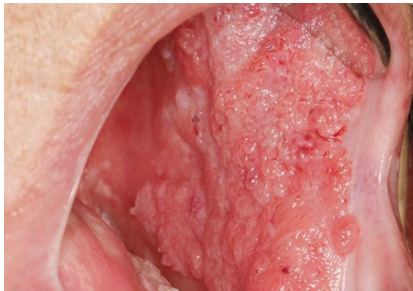

Figure 5: Extensive Papillary OSCC of the cheek with a cobblestone appearance. This lesion had been present for a while and could have been diagnosed earlier. Notice the abnormal growth and the danger sign of bleeding.

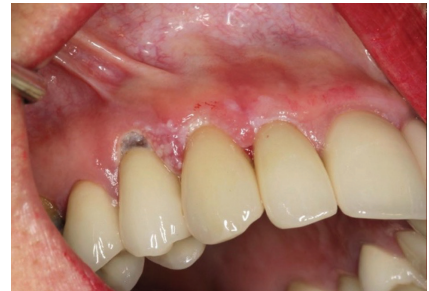

Figure 6: Although this gingival carcinoma may have a small footprint, its treatment will involve extensive resection and loss of teeth. This is often misdiagnosed as either periodontal infection or a candidal infection.

or erythroplakia (red lesions) (Fig 2). Clinical erythroplakia lesions have a high probability of being OSCC histologically and a recent systematic review shows that 42.8% of oral erythroplakias are already a carcinoma at the time of the first biopsy.⁴

Most OSCCs are unfortunately diagnosed late and has a negative effect on the prognosis of the patient. These cancers most often present as non-healing ulcers and are referred to as “malignant ulcers” and usually present with indurated, rolled borders with a necrotic base. They are characteristically painless (Fig 3). All oral ulcers that do not heal after 2-3 weeks should be biopsied.

Verrucous carcinoma is typically seen in older men, often associated with pipe smoking and present as an exophytic lesion with a warty, white surface (Fig 4). These cancers have an excellent prognosis, but they should be thoroughly examined histologically to detect the transformation to a classical OSCC which will negatively influence the prognosis.^{5,6}

Papillary squamous cell carcinoma is another exophytic

variant of OSCC which usually presents as a diffuse lesion with a papillary and/or cobblestone surface (Fig 5). This type also has a better prognosis than the typical OSCC.⁷

Squamous cell carcinoma (SCC) of the gingiva presents as a white leukoplakic area with a granular appearance (Fig 6). Such lesions are frequently misdiagnosed as a Candida infection or a non-malignant periodontal inflammatory condition.⁸

The oral health care worker is in an ideal position to diagnose SCC of the lip at an early stage. It initially presents as a white or red lesion often with crust formation (Fig 7).

Examination of patient and lesion

To examine the oral cavity one must follow a systematic approach to ensure no area of the oral cavity is missed. It can be done in less than 2 minutes and should be repeated at every dental visit. It is recommended to cover the following areas, in your order of preference:

- Ask the patient to stick out the tongue, grab the tip of tongue using a gauze swab and ask the patient to relax

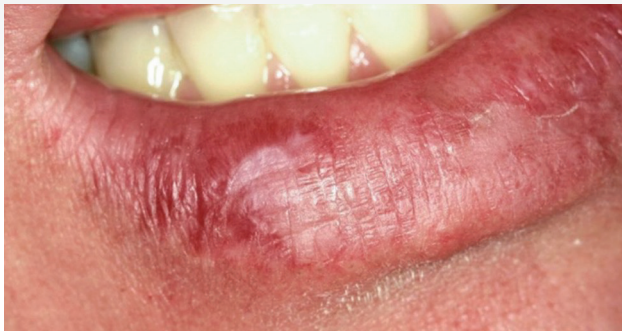

Figure 7: Early lip carcinoma appearing as a white/red crusted area. An astute dental practitioner should always examine the lip as part of a comprehensive oral examination.

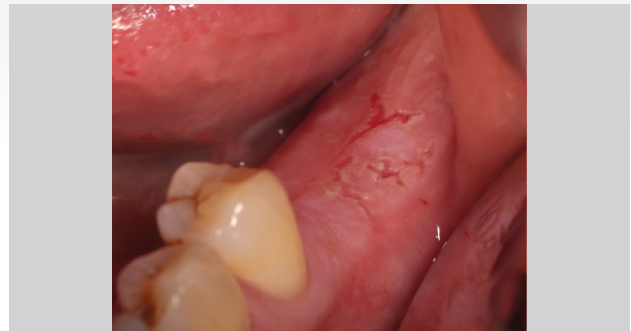

Figure 8: White lesion with small ulcerative areas. The patient reported a burn with hot food a few days prior to examination. This lesion must be followed up for at least 2-3 weeks to see if it heals.

the tongue completely and gently pull the tongue out and sideways. Make sure the lateral sides of tongue are visually inspected from the posterior foliate papillae to the tip of the tongue. A dental mirror is used to push the tongue away from the teeth to allow visual inspection of the entire floor of the mouth, from its posterior to its anterior aspect. Once the tongue is released, push the tip of the tongue posteriorly to enable visual inspection of the anterior floor of the mouth. This is the highest risk areas for OSCC and should be examined thoroughly at every opportunity.³

- The dorsum of tongue should be examined visually and palpated with the fingers to determine the presence of any lump or ulcer.
- Cheeks, vestibules, and inner lip surfaces should be examined by pulling the tissues away with the help of a dental mirror and then palpate, using a stroking movement of the finger, over the entire vestibule from one side to the other - for both the maxillary and mandibular vestibules.
- Depress the posterior part of the tongue, using the dental mirror, and at same time ask the patient to say "AHH" which will create a gagging reflex and allow visual inspection of the oro-pharynx-tonsillar area.
- Inspect the gingiva (both facial and lingual aspects) and palatal tissues, which must include probing the gingiva with a periodontal probe.
- Lastly, examine the lips for any crusting, white/red lesions, or ulcers.

Examination of the patient must include palpation of neck, in the sub-mental and sub-mandibular areas, for any lymphadenopathy.

Clinical Tip: If a solitary white lesion or ulcer is found, ask the patient about any history of placing aspirin in the mouth,

or of an accidental burn with hot food.

Figure 8 shows a white lesion with ulcerations posteriorly and, after enquiring about the possibility of the local application of painkiller or of a burn episode, she reported that she had burnt herself with hot food, a few days earlier. The lesion must be monitored over a period of two to three weeks for clear signs of healing and, if not, a biopsy would be done.

Clinical Tip: All white lesions should be wiped firmly with a gauze swab to see if it can be wiped off as candidiasis and even an aspirin burn can be wiped off. If it cannot be wiped off, it should be biopsied.

Examination of the lesion must include:

- Photographs to show the lesion and, by holding a periodontal probe next to lesion, the scale can be shown.
- Palpation of the lesion is necessary to feel the consistency and to identify induration (an increased tissue density that feels hard).
- Fixation of a lesion in soft tissue, other than hard palate (i.e. the lesion cannot be moved by lateral pressure) is a negative sign and may indicate deep infiltration of the cancer.
- Any surface bleeding should be noted as this is an ominous sign and is often seen in ulcerative OSCC.

Biopsy of a suspected malignant lesion

Whenever a lesion is suspected to be malignant:

- An incision biopsy should be done. Do this on the anterior border of tumour. This has the advantage of easier access for the biopsy and will not disturb the posterior margins that may negatively influence the surgical removal of

the tumour when referred to the surgeon tasked with the removal of the cancer.

- Do not attempt to completely remove the lesion as this may remove the margins the surgeon will need to see when planning the surgical excision of the cancer.
- Please refer to MC in Oral Cancer, August-September (Vol 13 No.4) and October-November (Vol 13 No. 5) 2023 for further guidelines and examples of biopsy techniques.

Request for histology - how to?

Once an appropriate biopsy has been taken, the tissue must be submitted to a histopathology laboratory. Preferably refer the biopsy of the oral cavity to a laboratory where the diagnosis can be made by a qualified oral and maxillofacial pathologist. The tissue should be placed in a container with 10% buffered formalin. Make certain that the tissue is fully covered by the formalin and that the tissue is not stuck to the screw cap of the container.

All specimens should be accompanied by an appropriate request form. This should state all the patient details like age, gender, and site of biopsy. It should also be specified if it is an incisional or excisional biopsy as this will influence the pathology report. All cases of suspicious malignant lesions should be done as an incisional biopsy, unless performed by a qualified surgeon who may attempt to remove the lesion, with clear margins, if small enough.

It is important to add relevant clinical information like smoking history, possible alcohol use or other habits that may be of importance as possible carcinogens, like the use of betel quid or chewing tobacco. It is always helpful to include a clinical image which is, with the availability of mobile phone technology, much easier to do than in the past.

Referring the patient for definitive treatment

As stated in the MC on Oral Biopsies, you should identify the surgeon closest to you who can perform oral cancer surgery. The patient should also be informed that referral will be necessary if the lesion needs follow-up treatment. Referral can be to a maxillo-facial and oral surgeon who performs oral cancer surgery, or an ENT or a general surgeon who specializes in head and neck surgery of this nature. Contact the relevant surgeon to find out more and to make sure that you have all the necessary logistics in place before doing a biopsy that may require follow-up surgery. If you are in a city, you may elect to refer the patient, for the biopsy, to a Specialist in Oral Medicine and Periodontics or to a Maxillo-Facial and Oral Surgeon.

Conclusion

Most dentists regularly perform extraction and surgical removal of teeth, and even implant surgery in many cases. There can thus be no excuse for not performing biopsies for oral lesions/diseases.

The important aspect of this is to refer the biopsy tissue to an oral and maxillofacial pathologist. As stated before, all pathology labs should have an in-house oral and maxillofacial pathologist on call. Just contact the laboratory, they collect, and you can mark it for the attention of the oral and maxillofacial pathologist. You can phone them beforehand to find out who this is and address it to that person.

It is the duty of oral health care providers to become involved in the management of oral lesions. Contact your local medical practitioner, if you practice in rural areas, and inform them that you can perform intra-oral biopsies under local anaesthesia, if required.

Oral cancer can be treated more successfully through early diagnosis.³

References

1. Le Campion A, Ribeiro CMB, Luiz RR, da Silva Junior FF, Barros HCS, Dos Santos KCB, et al. Low Survival Rates of Oral and Oropharyngeal Squamous Cell Carcinoma. *Int J Dent*. 2017;2017:5815493.
2. Chhina MS. Are e-cigarettes a safer alternative to reduce incidences of oral cancer? *Evidence-Based Dentistry*. 2023.
3. Chen SW, Zhang Q, Guo ZM, Chen WK, Liu WW, Chen YF, et al. Trends in clinical features and survival of oral cavity cancer: fifty years of experience with 3,362 consecutive cases from a single institution. *Cancer Manag Res*. 2018;10:4523-35.
4. Lorenzo-Pouso AI, Lafuente-Ibáñez de Mendoza I, Pérez-Sayáns M, Pérez-Jardón A, Chamorro-Petronacci CM, Blanco-Carrión A, et al. Critical update, systematic review, and meta-analysis of oral erythroplakia as an oral potentially malignant disorder. *J Oral Pathol Med*. 2022;51(7):585-93.
5. Xiao HD, Bifulco CB. 2 - Cellular and Molecular Pathology. In: Bell RB, Fernandes RP, Andersen PE, editors. *Oral, Head and Neck Oncology and Reconstructive Surgery*; Elsevier; 2018. p. 57-78.
6. Wang N, Huang M, Lv H. Head and neck verrucous carcinoma: A population-based analysis of incidence, treatment, and prognosis. *Medicine*. 2020;99(2).
7. Karthik KP, Balamurugan R, Sahana Pushpa T. Oral papillary squamous cell carcinoma (OPSCC): a rare presentation in the palate. *J Oral Med Oral Surg*. 2020;26(2):16.
8. Hanifa FA, Zazo A, Fares MK, AlHashemi M, Bazkke B, Haddad B, et al. Managing misdiagnosed gingival squamous cell carcinoma (GSCC) with occult symptoms: A report of two cases. *Annals of Medicine and Surgery*. 2021;69:102820.