

Masterclass in Clinical Practice

Endodontics

with

Prof Peet van der Vyver

Dr Martin Vorster



Identification and management of Radix Entomolaris



Scan to view video
of Case Report 1

References 1-15 are available on request from:

Email: dentsa@iafrica.com

Website: www.moderndentistrymedia.com

Introduction

According to Swartz, Skidmore and Griffen, mandibular first molars have a significantly lower success rate compared with other teeth.¹ Missed canals and the failure to remove all the microorganisms and pulp remnants from the root canal system are probably the main reasons for persistent infection around endodontically- treated molars. It is therefore important that clinicians have an awareness and good understanding of the variations in root canal morphology of the mandibular first molar.

Permanent mandibular first molars in Caucasian populations are generally two rooted teeth (one mesial and one distal root) with two mesial and one distal root canals.² The two mesial root canals can end up in two distinct apical foramina or they can merge together at the root tip end into one apical foramen.³

The number of roots for the mandibular first molar teeth may also vary. Carabelli⁴ was the first to report on mandibular first molars with supernumerary roots. The third root was located on the disto-lingual side and was called Radix Entomolaris (RE). In very rare cases, the mandibular first molar can also present with an additional root at the mesio-buccal side and is called Radix Paramolaris.³

Prevalence of RE

The presence of RE in the mandibular first molar is associated with certain ethnic groups. In populations with Mongoloid traits (for example Chinese, Eskimo and American Indians) the frequency can range from 5-30%.⁵⁻¹⁰ However, in Eurasian and Indian populations it is less than 5% and in African populations less than 3%.¹¹ Radix Entomolaris can be found on first, second and third mandibular molar teeth, occurring least frequently on second molars. Studies have also reported a bilateral occurrence with a frequency of 50-67%.¹²

Morphology of RE

The coronal third of the disto-lingual root of RE can be fixed partially or completely to the distal root. Based on the curvature in a buccal-lingual orientation, the separate RE variants can be classified into three types according to De Moor et al.¹³ Type I refers to a straight root/root canal. Type II refers to an initially curved entrance, which continues as a straight root/root canal. Type III refers to an initial curve in the coronal third of the root canal and a second curve beginning in the middle and continuing to the apical third.¹³

Radiographic Diagnoses of RE

A major limitation of conventional radiographic images is to compress three-dimensional (3D) anatomy into a two-dimensional (2D) image or shadow- graph. In an attempt to overcome this drawback of conventional radiography in order to detect the presence of RE, it is helpful to take additional exposures changing the horizontal angulation of the main x-ray beam. Wang et al.¹⁴, demonstrated that 25-degree mesial radiographs were significantly better than 25-degree distal radiographs for RE visibility and determination of optimum diagnosis.

According to Clark's rule (Also known as SLOB rule or Waltons projection), an object that moves in the same direction as the cone is located toward the lingual.¹⁵ Conversely, an object that moves in the opposite direction from the cone is located towards the buccal. Therefore, the RE image that moves distally is superimposed on the distobuccal root image that moves towards the mesial, when taking radiographs with small distal angulations.

Cone-Beam Computed Tomography (CBCT) provides dentistry with a practical tool for non-invasive and 3D reconstruction imaging for the use in endodontic applications and morphologic analyses. CBCT imaging allows for visualizing a new dimension, eliminate superimpositions, provide additional information for diagnosis and therefore enables a more predictable management of complex endodontic conditions compared with intraoral radiographs alone. CBCT imaging allows ascertaining the identification, exact location, curvature and angulation of the RE in order to prevent iatrogenic events that might occur in relation

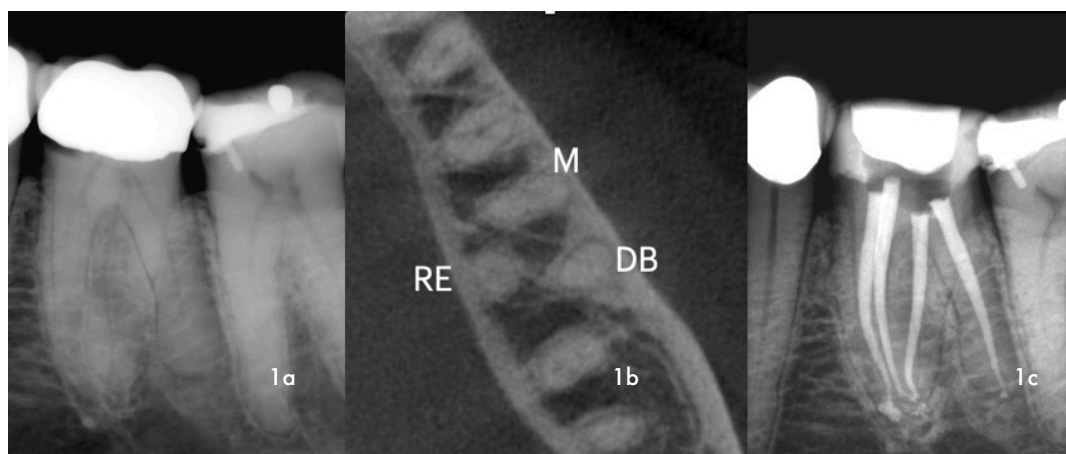


Figure 1: (a) Pre-operative radiograph of mandibular, left first permanent molar that was restored with a ceramo-metal crown, showing evidence of decay on the mesial gingival margin (b) CBCT- midroot axial view revealed the presence of a mesial root (M), distal (D) and Radix Entomolaris on the lingual aspect (RE) (c) A 30 degrees, mesial angulated view of the four obturated root canal systems.

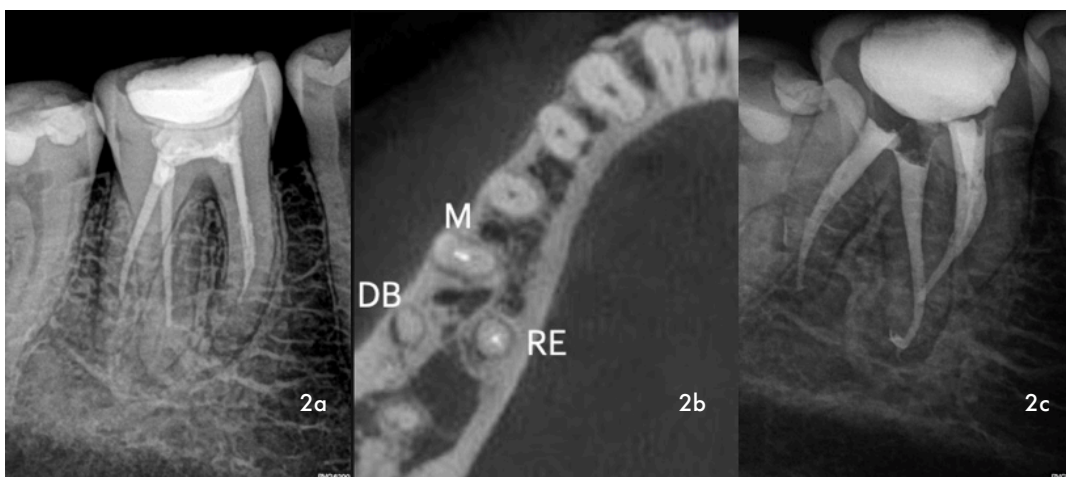


Figure 2: (a) Pre-operative radiograph of mandibular, right first permanent molar that was poorly root treated 2 years previously (b) CBCT- midroot axial view shows the presence of a mesial root (M), distal (D) and Radix Entomolaris on the lingual aspect (RE) (c) A 30 degrees, mesial angulated view of four obturated root canal systems.

to canal curvature like instrument separation, perforation and ledge formation.

Case Report 1

The patient, a 45-year-old female presented with pain and discomfort on her mandibular left first molar, previously restored with a ceramo-metal crown. A pre-operative radiograph revealed evidence of extensive decay on the mesial margin as well as unusual root morphology (Figure 1a). The ceramo-metal crown was removed, caries excavated and a temporary crown placed. A CBCT, axial coronal slice confirmed the presence of two roots (mesial and distal)(Figure 1b). A CBCT, axial coronal slice confirmed the presence of two roots (mesial and distal) (Figure 1b). Another axial slice in the midroot area, revealed the presence of distal root bifurcating into two separate roots. The additional root, branching off on the lingual aspect, confirmed the presence of Radix Entomolaris (Figure 1c). Note the curvature in the apical part of the RE that was maintained during canal preparation and obturation.

Case Report 2

The patient, a 38-year-old female presented with discomfort on her mandibular right first molar that was root canal treated approximately 2 years ago. A periapical radiograph revealed an incomplete root canal treatment and evidence of an additional distal root (Figure 2a). A high resolution CBCT scan confirmed the diagnosis of Radix Entomolaris (Figure 2b). Figure 2c depicts the final result after re-treatment. Note again the curvature in the apical part of the Radix Entomolaris root.

Conclusion

CBCT technology as well as proper angulation when acquiring radiographic images proves helpful in locating canals in especially first mandibular molars with a high incidence of anatomical variations. A thorough understanding of the prevalence of RE, its anatomical variations as well as radiographic diagnosis will provide the clinician with a better understanding of its complexity in order to ensure successful treatment outcomes.