

# Masterclass in Clinical Practice

## Endodontics

with

Prof Peet van der Vyver<sup>1</sup>

Prof Martin Vorster<sup>2</sup>



## How to manage C-Shaped canal configurations in mandibular molars

<sup>1</sup> Peet van der Vyver,  
BChD (Pret); Dip. Odont (Aest Dent);  
Dip.Odont (Endo); MSc Odont (Endo), PhD (Endo)

<sup>2</sup> Martin Vorster,  
BChD (Pret); PGDipDent (Endo); MSc(Dent), PhD

### Introduction

C-shaped root canal configuration is an anatomical variation of root fusion and type of taurodontism commonly seen in mandibular second molars with a prevalence ranging from 2.7% to 45.5% depending on different population groups. These complexed root canal systems are connected by a slit or web with varying anatomy along the root length which often makes adequate debridement a major obstacle.

Fan et al (2004) suggested a modified 5-type categorization of C-Shaped canals with an evident distinction between types: Type I (C1; continuous "C" shape), Type II (C2; semi column morphology), Type III (C3, two or three discrete canals), Type IV (C4, only one round or oval canal in related cross-section), and Type V (C5; absence of visible canal lumen)(Figure 1).

Clinical guidelines for the management of C-Shaped canal configurations will be discussed below by means of a clinical case report. The patient, a 35-year-old female presented with irreversible pulpitis on her mandibular second molar, previously restored with a very deep Class I composite restoration.

### Radiographic Diagnosis

C-shaped canals cannot not be readily identified through 2-dimensional periapical radiographs (Figure 2). Cleaning, shaping and obturation procedures are therefore challenging without proper diagnostic information. The application of cone-beam computed tomography (CBCT) in endodontic practice may help clinicians to effectively diagnose and plan the treatment of a C-Shaped root canal system.

### Location and negotiation of canals

Calcifications in the pulp chamber may obscure the C-shape of the canal system. In such cases, several orifices may be probed which might link up on further instrumentation. Modifications in the access cavity designs may also be required for teeth with C-shape configuration to facilitate location and negotiation of the complete canal system. When the orifice is continuous C-shape or arc-like Mesio-buccal-Distal (MB-D), the number of canals may vary from one to three. When the orifice is oval or flat, the number of canals may be one or two and when the orifice is round, there is usually only one canal below the orifice. Modification of the pulp chamber or removal of calcifications can be achieved with ultrasonic instrumentation as indicated in figure 4.

### Cleaning and shaping

Canal negotiation to full working length is likely to be difficult and time consuming in these cases. Coronal enlargement

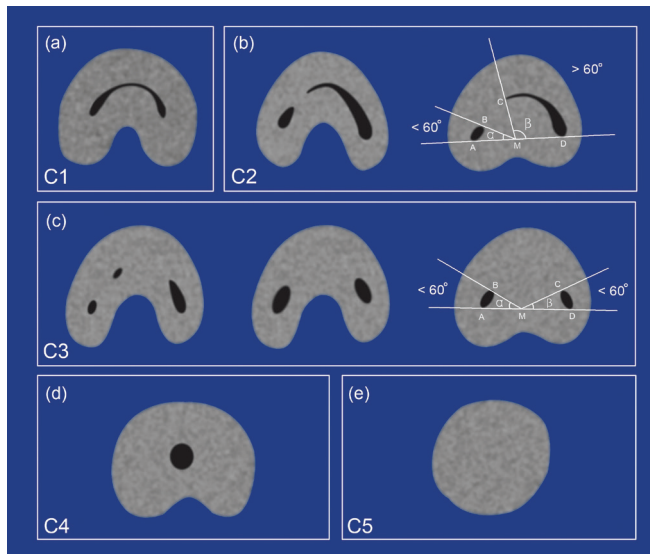


Figure 1: Classification of C-shaped root canals. (a) C1: root canal in the form of an uninterrupted C. (b) C2: root canal semicolon-shaped, with angle a smaller and angle b larger than 60°. (c) C3: root canal in the form of separate canals, with angles a and b smaller than 60°. (d) C4: a single round or oval root canal. (e) C5: absence of a root canal lumen (adapted from Fan et al, 2004).

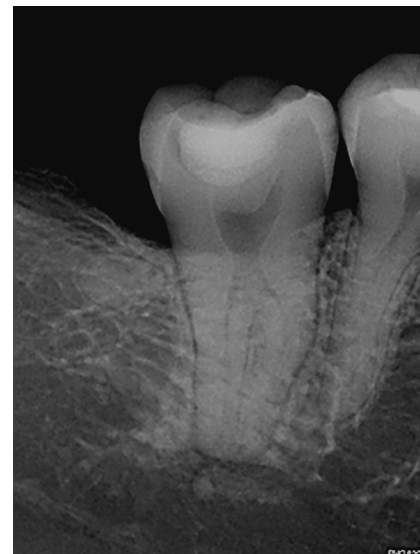

Figure 2: (Periapical radiograph of mandibular second molar.

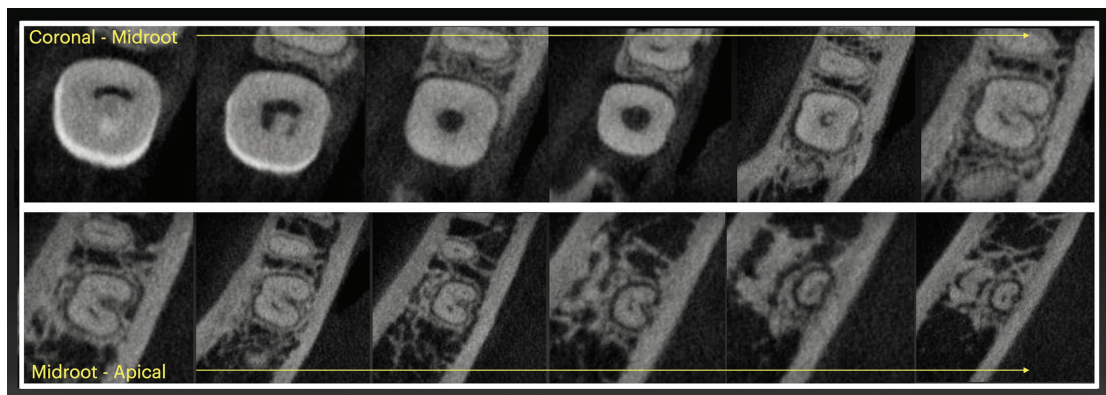


Figure 3: Axial slices of CBCT scan of mandibular second molar illustrating the pulp chamber and root morphology from coronal to apical sections of the tooth.

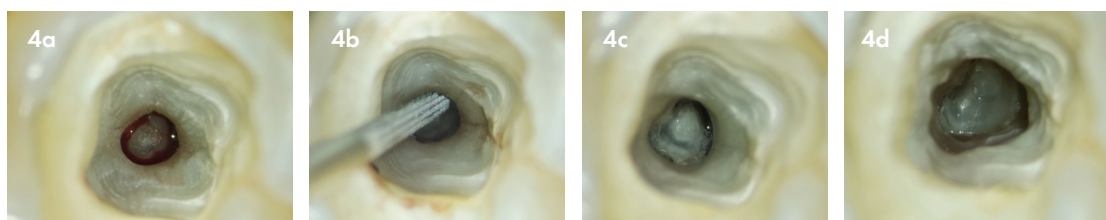


Figure 4: High magnification view of pulp chamber under Zumax 3200 Pro microscope (a) level at which root canals bifurcate; (b) pulp chamber modification with a Start.X no 3 tip (Dentsply Sirona); (c) C shaped canal configuration visible; (d) C shaped canal configuration and canal orifice location.

and careful negotiation with size 08 C+ and 08 K-files is standard protocol as canal systems are usually partially blocked or obliterated (Figure 5). Nickel-titanium rotary and reciprocation instruments seem to be safe for preparation of C-shaped root canal systems in molars. However, enlargement to an apical dimension greater than size 30 (0.06 taper) is not recommended.

Due to the large area of canal space, it is doubtful that

intracanal preparation instruments reach and debride the entire root canal outline. This highlights the importance of proper irrigation procedures and the use of chemical agents for disinfection in the treatment of C-shaped root canal systems. Activation of heated sodium hypochlorite with either EndoActivator, Eddy Irrigation tip or EndoVAC system is highly advisable in treating C-shaped root canal systems.

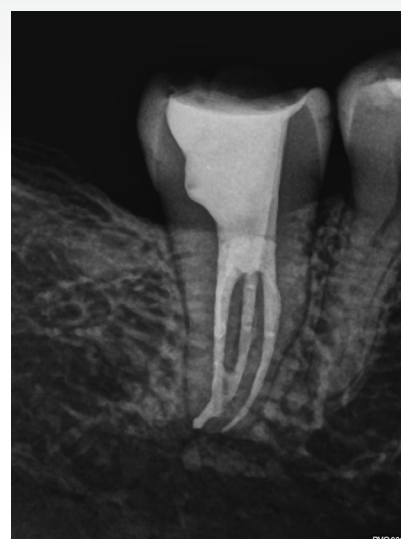
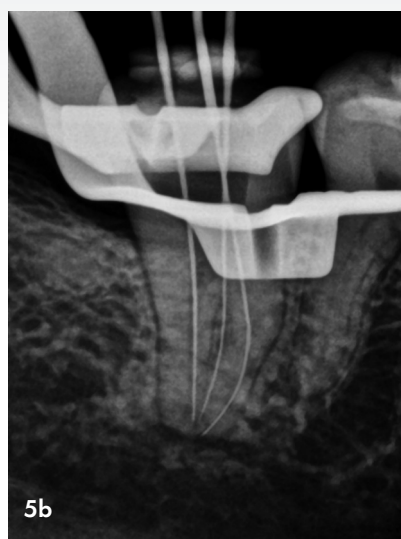
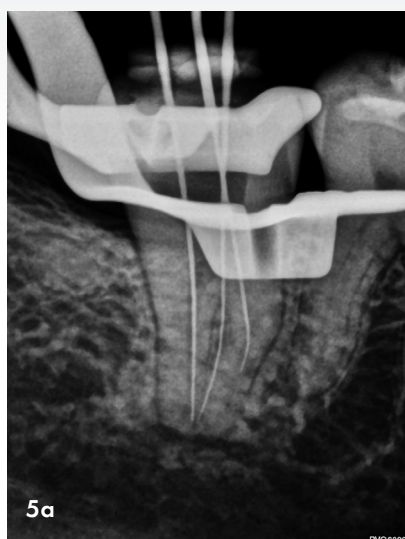


Figure 5.(a) After orifice location the distal and mesio-lingual canal was prepped to full working length and patency ensured. The mesio-buccal canal presented with an obstruction in the apical third of the root canal system; (b) The canal system was unblocked using a 08 C+ K-file followed by negotiation to full working length using a conventional 08 K-file.

Figure 6. Postoperative obturation result using a bioceramic sealer, gutta-percha points and GuttaSmart System (Dentsply Sirona).

### Obturation

A hermetic and void-free obturation is essential for successful root canal therapy. Lateral condensation technique is widely used due to its low cost, but requires the use of several additional gutta-percha points specifically in irregular and wide forms like C-shaped canal configurations.

Thermoplasticized gutta-percha obturation techniques (Figure 6) are efficient in filling canal irregularities or wide canals which require a high mass of gutta-percha and is the recommended technique for canal obturation. Bio-ceramics, another alternative for endodontic obturation, have gained popularity over the last few years. Research indicate that these biocompatible sealers show improved sealing ability, antibacterial and antifungal activity and can be applied with great success in the endodontic treatment and obturation of C-shaped canals.

### Conclusion

A thorough knowledge of canal anatomy, careful canal negotiation with the aid of C+ K-files and a hermetic seal free of voids are important aspects in the endodontic treatment of complex C-shaped canals. A strong emphasis should also be placed on proper irrigation using heated sodium hypochlorite in conjunction with adjunct activation devices in these often challenging cases.

### Reference

Fan B, Cheung GS, Fan M, Gutmann JL, Bian Z. C-shaped canal system in mandibular second molars: Part I: Anatomical features. J Endod. 2004;30:899–903.



Scan QR code to see the detailed clinical management of the clinal case outlined in this article using the latest ProTaper Ultimate rotary file system, AH Plus Bioceramic Sealer and GuttaSmart systems for canal obturation.