

Masterclass in Clinical Practice

Prosthodontics with Paul P. van Zyl¹



Occlusal bite splint therapy: Analog and Digital workflow in full occlusal coverage bite splints

¹ Paul P. van Zyl
BChD, MChD (Prosthodontics)
Private Practice, Cape Town, South Africa

Introduction

Occlusal bite plates or splints have been used since the early 1950's to treat a combination of signs and symptoms associated to Temporomandibular Dysfunction (TMD) disorders and tooth destruction due to parafunctional habits like grinding or clenching of the teeth (bruxism).¹

These bite plates come in various designs and are made from different materials. All have a place, and a single design cannot be recommended for all the different situations contributing to specific signs and symptoms.

Indications

- A. TMD related to
 - 1. Muscular spasms
 - 2. Disc derangements
 - 3. Disease (arthralgia, arthritis, arthrosis)
- B. Occlusal protection and maintenance during bruxism²
 - 1. Natural teeth
 - 2. Ceramic restorations
 - 3. Implant borne restorations
- C. Snoring and sleep disorder appliances

Designs

A. Full coverage.

Full occlusal contact in Centric Relation (CR) with built in anterior guidance to avoid balancing and non-balancing contacts in protrusion and lateral mandibular movement. This allows opening of the inter-articular space commonly used in the treatment phase of TMD, but also long term protection of the occlusal surfaces against para-functional habits.

i. Maxillary: Figs. 1, 2

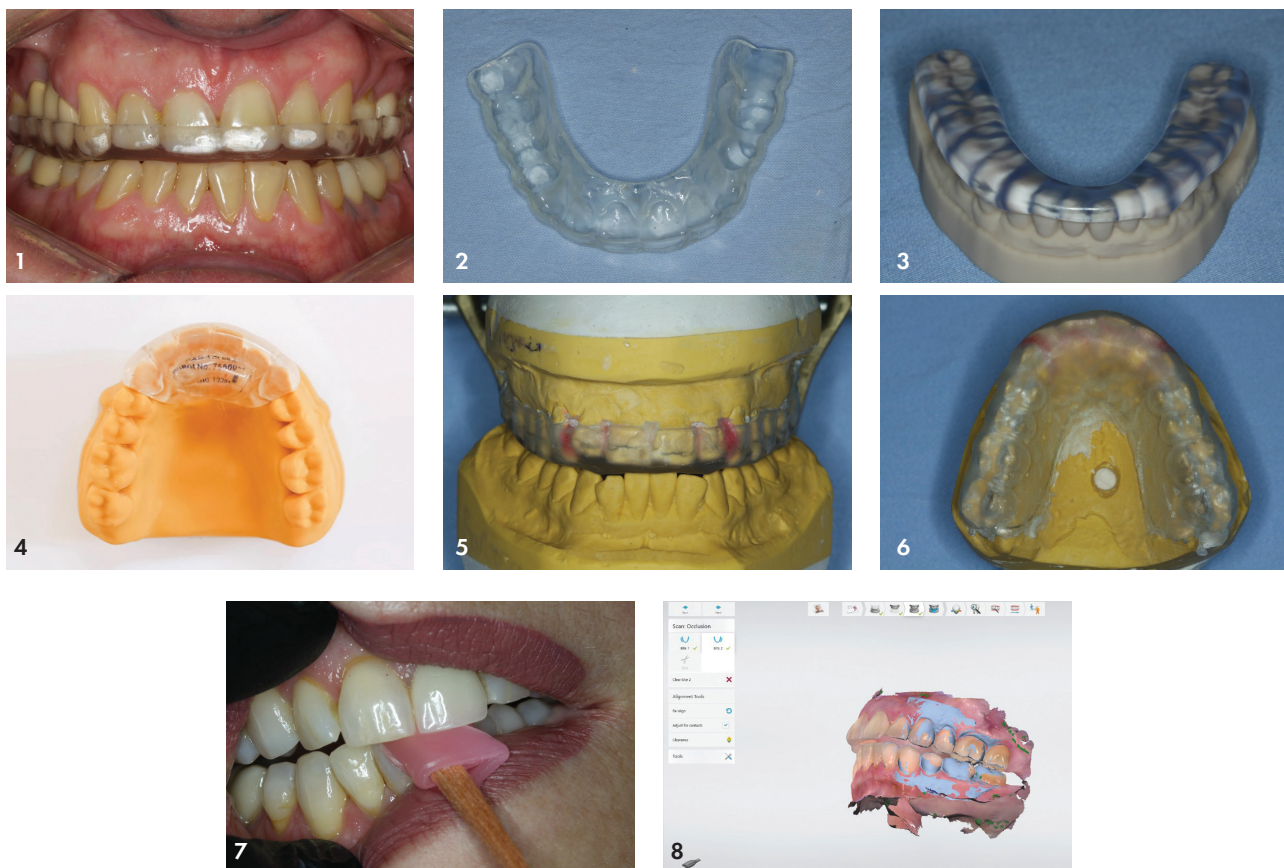
The first designs were known as the Michigan Splint, described in 1966 (Ramfjord and Ash) as a full maxillary occlusal splint. This is my preferred design and can be made following the described analog or digital pathways.¹

ii. Mandibular: Fig. 3

Full occlusal coverage also known as the Tanner device. Similar workflows are followed as for the maxillary bite splints. This design is preferred by some clinicians, mainly due to comfort which becomes important if the bite splint needs to be worn during the day.

B. Anterior coverage

Only on the front 6-8 teeth. This design has its place for management of acute TMD symptoms, or where anterior repositioning of the mandible is required. It is however used commonly due to the ease of fabrication but should be used with caution as long-term protection against effects of bruxism or parafunctional habits. Posterior over-



eruption may cause an anterior open bite, damage to the condyle or coronoid process and other internal components of the TMJ. Commonly used is the BiteSoft® product which has a locked in incisal position. This should not be used for long term occlusal protection. (Fig. 4). If this design is used a hard PMMA material with a flat (free) incisal contact area is recommended. It should be replaced with a full coverage appliance after symptoms have subsided.

C. Anterior repositioning

Any design with occlusal indentations to guide the mandible anteriorly to disengage the condyle anterior to CR position. This bite splint should be used when internal derangement of the TMJ components have been confirmed. These may cause clicking and/or discomfort. The derangement can be recaptured using this appliance but must gradually be changed to a bite splint which have even contacts in CR.

Materials

A. Hard.

These are usually made from Poly Methyl Met-Acrylate (PMMA), which are traditionally chemically cured by mixing polymer and monomer components. This material can be polished smooth but shows roughening surface with wear. The use of wire clasps are recommended to ensure predictable retention.³

PMMA can also be digitally milled but newer digitally printable vinyl and resin materials with varying consistencies

have become available (KeySplint Soft™ or Hard). These are my preferred materials with the KeyStone Soft™ being softer than PMMA, but not rubbery or with a springboard effect like the ethylene-vinyl acetate (EVA) mouthguard materials. It is proven to resist wear and stays smooth in comparison with other materials and patients report superior comfort.^{4,5,6}

B. Soft

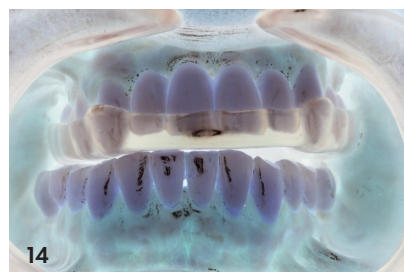
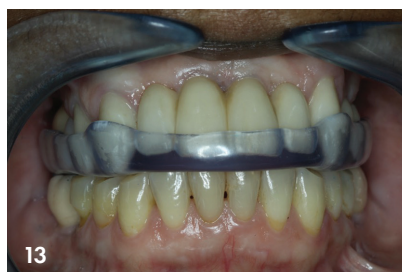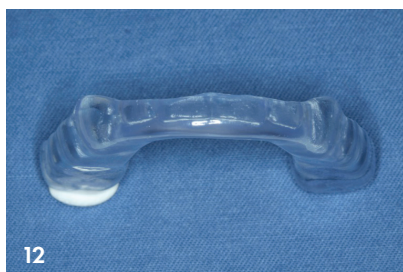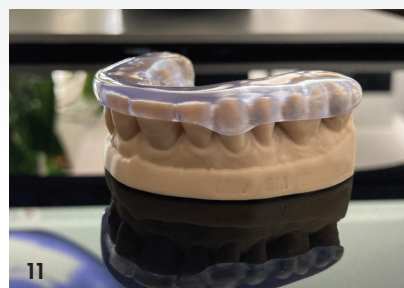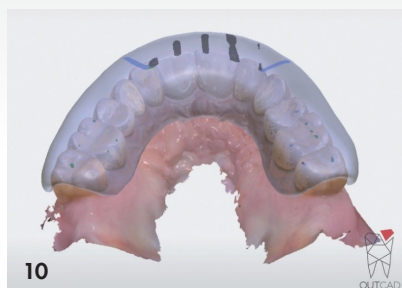
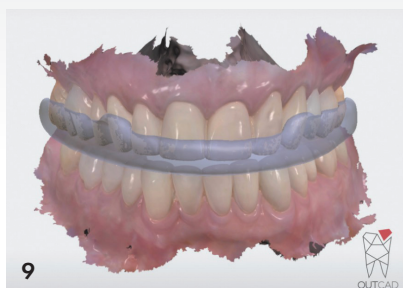Mostly made from EVA copolymer (night-guard®). Easy to manufacture but clumsy and big design with springboard effect strengthening a bruxism or clenching habit.⁷

C. Dual laminate

Thermoforming hard co-polyester with varying thicknesses of a soft layer attached to it. I prefer a very thin, soft layer (2mm) layer with a hard layer to which PMMA can be processed to create the desired design and occlusal contacts (Erkodur®). This is proven to be comfortable and eliminates wire clasps to ensure acceptable retention. Thicker than 2mm soft layers becomes clumsy with a thinner hard layer which tend to crack and craze with functioning or occlusal adjustment.

4. Analog workflow using a hard/soft and added PMMA appliance

Impressions are made of the upper and lower using a rubber or alginate material. When using alginate, the stone models should be cast immediately to limit dimensional distortion. The slightest distortion results in difficulty fitting the appliance



and a non-passive or “tight” feeling is regularly a problem. A wax wafer bite in the open position you are planning the bite splint to be at is key to accurate occlusal surfaces from the laboratory.

The bite splint is manufactured by thermoforming the Ekodur® 2mm dual laminate on the cast. Clear acrylic is added in the proposed bite and finished. (Figs. 1, 2, 5, 6).

On fitting the appliance, the bite should be checked, adjusting to even contacts in CR and slight disclusion with anterior and lateral mandibular movement.

Digital workflow using the Keysplint® digitally printed appliance

Intra Oral Digital Scans (IOS) are recorded of the upper and lower. In this case the 3Shape Trios 4 Intra Oral Scanner is used. In registering the occlusion, a hard anterior stop is recommended in the open proposed biteplate occlusion. (Figs. 7, 8) This is to prevent movement during the registration of the occlusion. In the illustrated case a wooden dental stick wrapped with pink wax is used. This provides a stable stop which cannot slip or change position during the bilateral bite scan capture.

The bite scan is sent to the laboratory where it is digitally designed, (Figs. 9, 10) and 3D printed (Fig. 11). Note the gingival extensions (Fig. 12) of the appliance at the molars and canines which serves as “clasps” for retention. These appliances have superior retention and passive fit. Patients report back positively in respect of comfort and retention. (Fig. 13)

References

1. Ramfjord SP, Ash M. Reflections on the Michigan occlusal splint, *Jornal of Oral Rehabilitation*, 1994, 21: 491-500.
2. Faus-Matoses V. et al. An 8 year prospective clinical investigation on the survival rate of feldspathic veneers: Influence of occlusal splint in patients with bruxism. *J. Dent*, 2020, 99: 103352
3. Yildiz D, et al. Two-body wear of occlusal splint materials against different anatagonists. *BMC Oral Health*, 2020, 20:174
4. Latta MA. A laboratory evaluation of localizes wear of splint materials. 2020, University of Creighton School of Dentistry sponsored by Keystone industries.
5. Grymak A. et al. Comparison of hardness and polishability of various occlusal splint materials. *Journal of the Mechanical Behaviour of Biomechanical Materials*. 2021, 115, 104270.
6. Benli M. et al. Surface roughness and wear behavior of occlusal splint materials of contemporary and high performance polymers. *Odontology* 2020, 108: 240-250
7. Ebru I. et al. The hemodynamic effects of occlusal splint therapy on masseter muscle of patients with myofacial pain accompanied by bruxism. *Jnl of Craniomandibular and sleep practice* 2020: Vol 38 No 2,99-108

Acknowledgements

1. Aesthetic Studio Dental Laboratory.
2. OUTCAD Dental. Digital Dental Design.