

Immediate placement of a new fully tapered tissue level implant

Mario Rocuzzo¹

Initial situation

In September 2019, a 53-year-old non-smoking male patient came for a consultation after the fracture of his maxillary right first premolar (Fig. 1). The patient presented with minimal periodontal problems, including multiple gingival recessions. The radiographic image confirmed the presence of a large periapical radiolucent area and some distal interproximal bone loss (Fig. 2). A thorough examination was carried out and revealed caries into the root and involvement of the distal furcation (Fig. 3). Upon clinical examination, the amount of healthy dentine was considered insufficient for a stump preparation for a conventional crown.

Moreover, the patient was unwilling to undergo orthodontic extrusion of the tooth. Additionally, an apically repositioned flap, after endodontic treatment, would have most likely produced a very long crown. Subsequent to the clinical evaluation, the patient gave his informed consent for the extraction of tooth #14 and immediate implant placement.

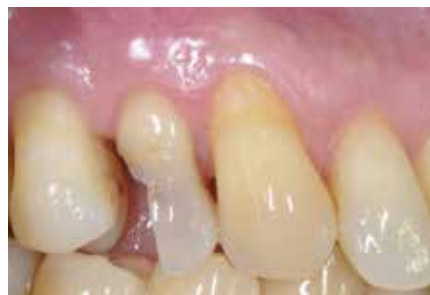

Figure 1.

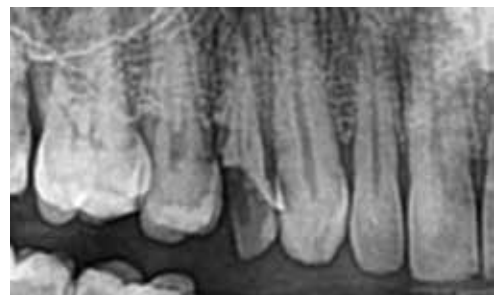


Figure 2.

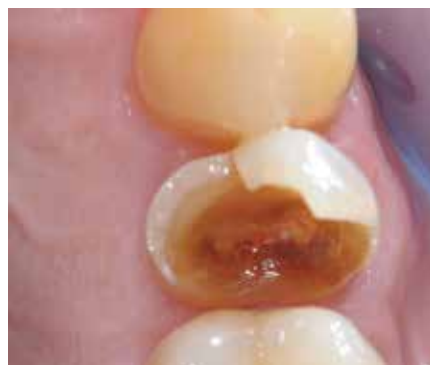

Figure 3.

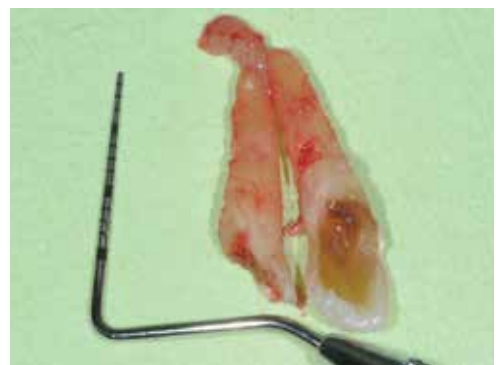


Figure 4.

¹ Mario Rocuzzo, Lecturer at the University of Turin, Italy; Adjunct Clinical Assistant Professor, University of Michigan School of Dentistry, Ann Arbor, US. Private practice specialising in periodontics and implantology, Turin, Italy.

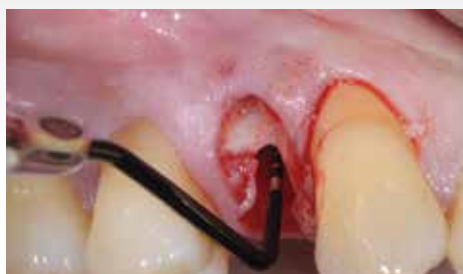

Figure 5.

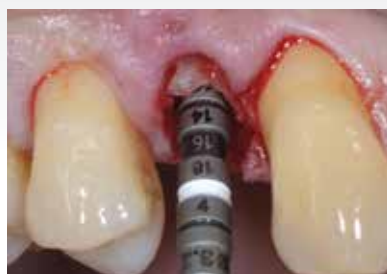

Figure 6.

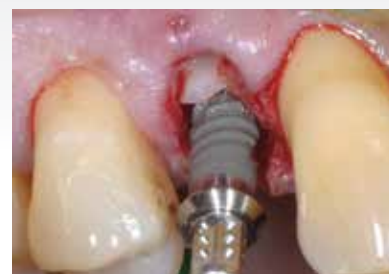

Figure 7.

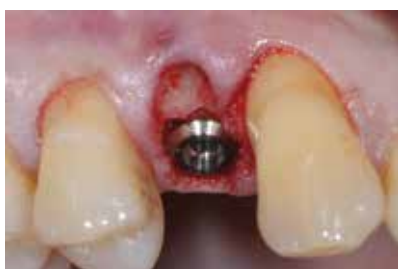

Figure 8.

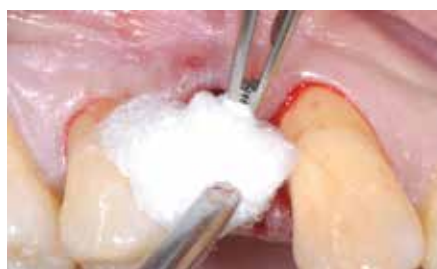

Figure 9.

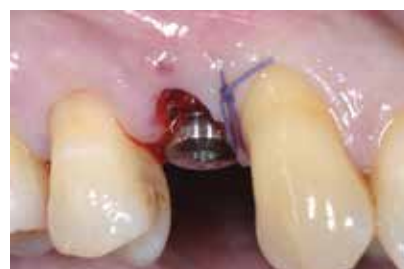

Figure 10.

Surgical procedure

In order to minimise the trauma during treatment, a careful separation of the tooth into two parts was carried out before extracting both roots (Fig. 4). No incisions were made, in order to reduce the risk of soft-tissue dehiscence. Before implant insertion, meticulous cleaning and careful curettage/debridement was carried out. The dimensions of the socket were measured by means of a periodontal probe (Fig. 5). A TLX SP, RT, SLActive®, Roxolid® 3.75x12.00mm implant (Straumann Institut) was placed according to the manufacturer's instructions. The implant was inserted using the handpiece in a self-tapping fashion, and a high primary stability was achieved (Figs. 6 & 7). The implant was positioned according to the International Team for Implantology philosophy of "as shallow as possible, as deep as necessary", the SLActive® surface margin placed at bone level. The use of a reduced-diameter implant allowed the presence of more bone around the implant for greater long-term success. The implant was placed slightly on the palatal side of the alveolar bone crest, leaving sufficient space buccally (Fig. 8).

A flexible composite cone composed of synthetic granules and porcine collagen fibres (collacone® max, botiss biomaterials) was inserted into the buccal portion of the socket to reduce bone remodelling and possible soft-tissue recession (Fig. 9). The mesial papilla was fixed with a 4/0 Vicryl® suture (Fig. 10). The postoperative radiograph confirmed the good positioning of the implant in the vertical dimension (Fig. 11). The patient was instructed not to traumatise the area, to brush very carefully and to rinse with a 0.12% chlorhexidine digluconate solution for one minute three times a day for the same period. The suture was kept in place for one week (Fig. 12). The patient was seen once a

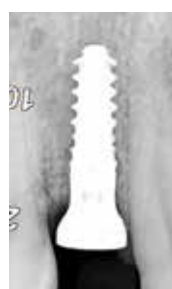

Figure 11.

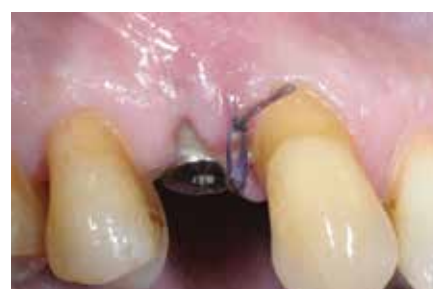

Figure 12.

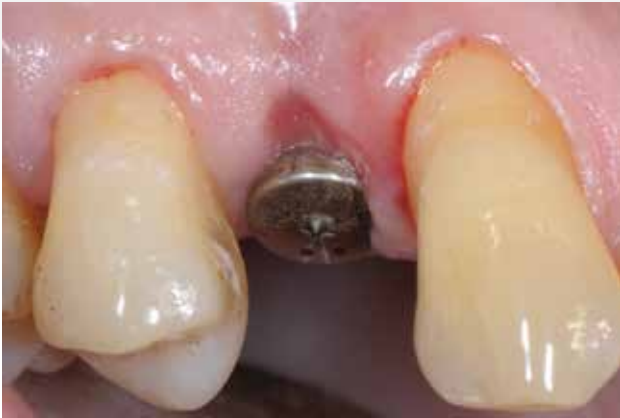

Figure 13.

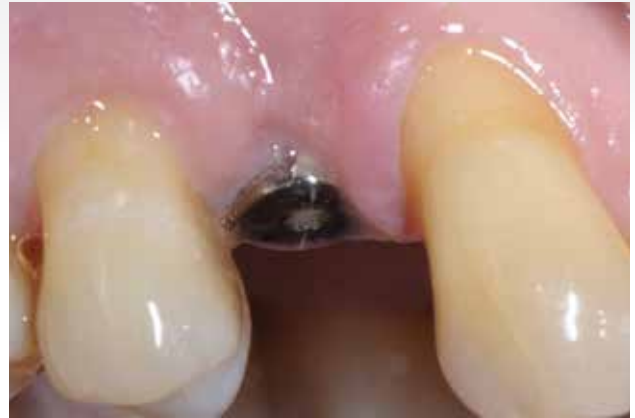

Figure 14.

week for the first month to monitor healing, which proceeded with no complications (Figs. 13 & 14). The patient was then instructed on proper brushing in order to have adequate plaque control without injuring the soft tissue.

Prosthetic procedure

Six weeks after surgery, the peri-implant mucosa appeared to be free from inflammation and had an optimal contour (Fig. 15). After soft-tissue maturation, an impression was taken, and a provisional crown was

delivered (Figs. 16–18). The provisional crown was kept in place for three months in order to facilitate soft-tissue maturation for an ideal final aesthetic restoration. Before the delivery of the definitive metal–ceramic crown, the peri-implant soft tissue was checked with a probe, and the probing depths were found to be physiological (Fig. 19). The patient was asked to follow an individualised supportive periodontal therapy programme for an appropriate clinical and radiographic follow-up.

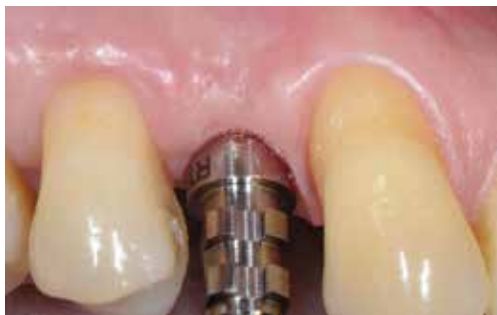

Figure 15.

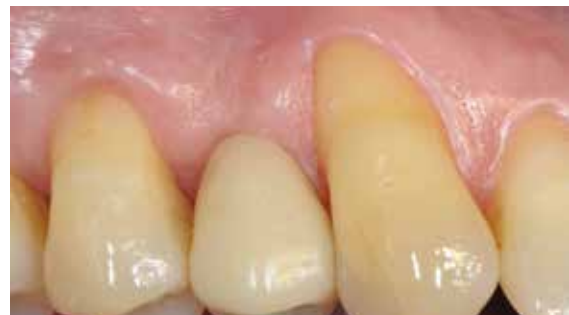

Figure 16.

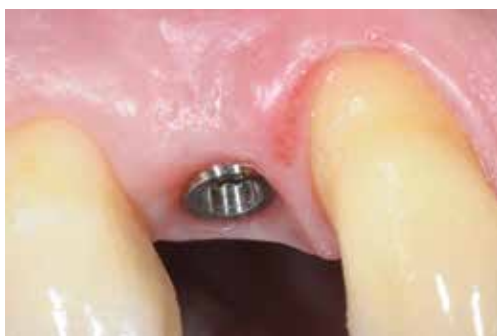

Figure 17.

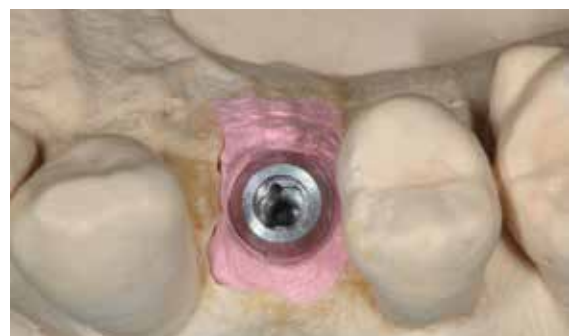

Figure 18.

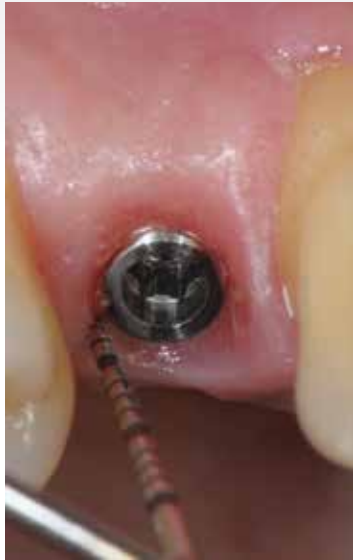

Figure 19.

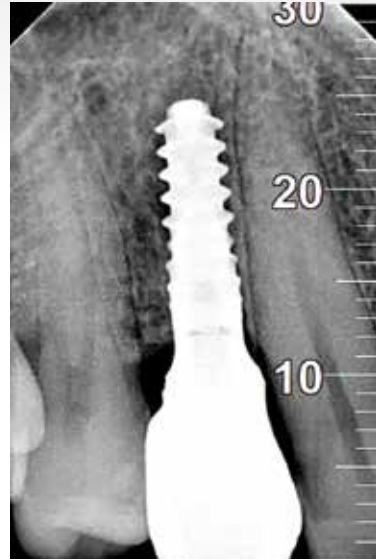


Figure 20.

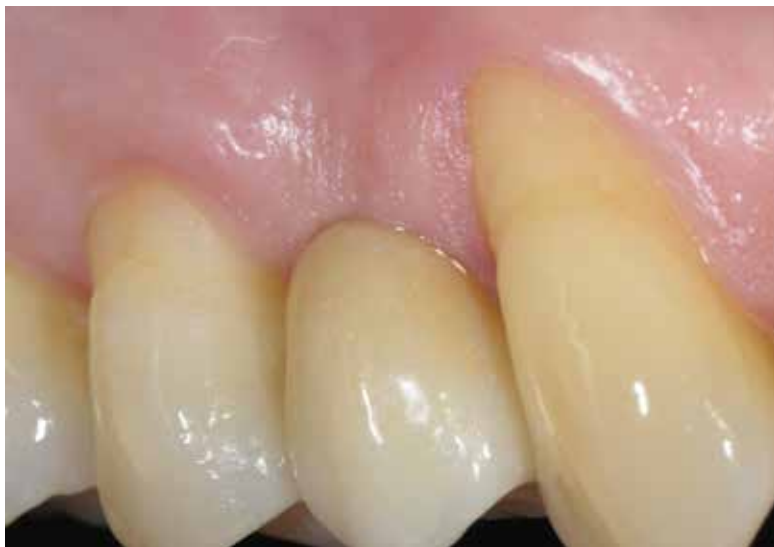

Figure 21.

Treatment outcomes

In July 2020, the radiographic examination confirmed the correct fitting of the crown on the implant and the good level of the interproximal bone crest (Fig. 20). Plaque control was adequate, the pocket depths were physiological and there was no bleeding on probing around the newly placed crown (Fig. 21).

Acknowledgements

The author would like to thank Turin-based master dental technician Francesco Cataldi for carrying out the laboratory procedures.

Reprinted with permission by youTooth