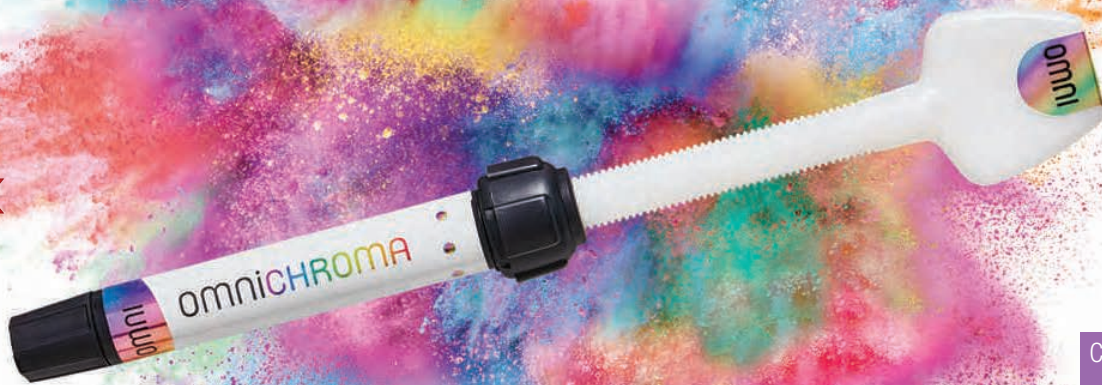

omniCHROMA®

The first universal composite that offers ONE SHADE
to match any patient and almost any case.

The culmination of 35 years of research and development,
Tokuyama Dental is proud to present OMNICHROMA, the world's first dental
composite that matches every tooth with a single composite shade.



[Click Here to view
Full Brochure](#)

[Click Here to view
OMNICHROMA
Video](#)

FEATURES

- Unprecedented shade-matching ability and esthetics
- Shade matches both before and after bleaching
- High polishability inherited from ESTELITE
- Excellent physical-mechanical properties inherited from ESTELITE

INDICATIONS

- Direct anterior and posterior restorations
- Direct bonded composite veneer
- Diastema closure
- Repair of porcelain/composite

Terms & Conditions Apply. Pictures used may be for representation only. E&OE.



Treatment of mandibular first molars with atypical anatomy: a case report

Yurii Riznyk¹ and Svitlana Riznyk²

Abstract

A 30 year old female patient presented with symptomatic irreversible pulpitis of both LR6 and LL6 teeth. Cone beam computed tomography (CBCT) of the region revealed, a middle mesial canal in tooth LR6, and a middle distal canal in tooth LL6. The case was managed with K files (Dentsply Maillefer), K file Nitiflex (Dentsply Maillefer), Protaper Next (Dentsply Maillefer), XP-endo Shaper (FKG) and BT-Race (FKG) under copious irrigation with sodium hypochlorite, ethylenediaminetetraacetic acid and saline. Premixed bioceramic sealer TotalFill (FKG) and gutta percha were used for root canal obturation. The access cavities were restored using glass ionomer cement and resin composite. A 12-month review showed that the teeth were functional within normal periodontal parameters. The favourable clinical and radiographic outcome in this case demonstrated that the treatment approach followed is effective in solving complex clinical challenges.

Keywords: Atypical anatomy, endodontic treatment, mandibular molars, middle distal canal, middle mesial canal.

Introduction

The main objective of endodontic therapy is a thorough debridement of the root canal space followed by complete obturation (Vertucci, 2005). The latest advances in the instrumentation techniques and equipment have enabled us to solve difficult clinical cases in endodontics (Berutti et al, 2009). At the same time, regardless of the continuous improvement in technology, the thorough knowledge of the internal anatomy of the pulp chamber and the root canal system is critical to increasing the rate of clinical success of endodontic treatment (Fava, 2001; Vertucci, 2005). The failure of the treatment could be the result of failure to recognise any unusual canal configuration, as well as prepare and perform the proper obturation of the missed root canals (Leonardo, 1998; Almeida et al, 2015). This assertion may be confirmed by the research of Song et al (2011), who reported that 30% of possible causes of failure in the previous root canal treatment of first lower molars were missed root canals.

In most of the cases, the first mandibular molar has two roots with two root canals in the mesial root and one canal in the distal root (Vertucci et al, 2006; de Pablo et al, 2010). In the endodontic treatment of the first mandibular molar, the main difficulty is the mesial root, which may have an additional middle root canal middle mesial canal (MMC), located in the developmental groove between the mesiolingual (ML) and the mesiobuccal (MB) canals. According to studies, the third canal in the mesial root can be found up to 18% of cases (Pomerantz et al, 1981; Navarro et al, 2007; de Pablo et al, 2010; Versiani et al, 2016). The MMC is categorised into three types fin, independent and confluent (Pomerantz et al, 1981):

¹ Dr Yurii Riznyk, DMD, PhD.
Assistant of the Restorative Dentistry
Department, Danylo Halytsky Lviv
National Medical University, Lviv,
Ukraine.

² Dr Svitlana Riznyk, DMD, PhD.
Therapeutic Dentistry Department, Lviv
Medical Institute, Lviv, Ukraine.

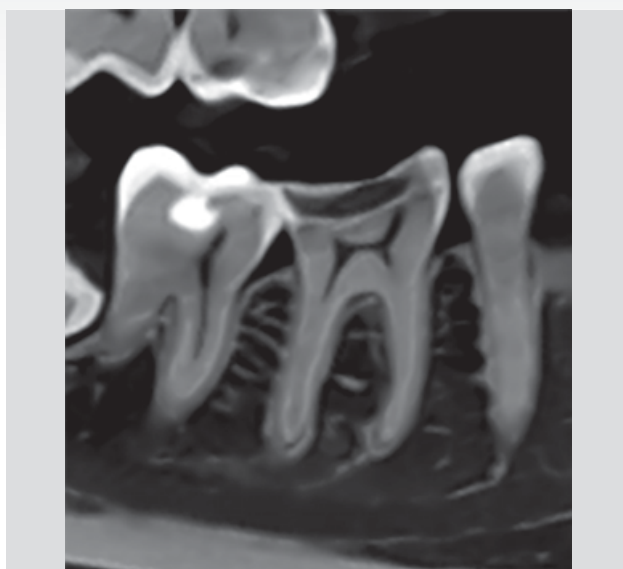

Figure 1.

1. Fin type lacks a separate orifice. It is usually a small linear extension of MB or ML canal

2. A separate orifice and separate apex are specific to this independent type

3. The confluent type is characterised by a separate orifice but it merges with either the MB or the ML canal. It was found in the research that confluent configuration is the most prevalent anatomic configuration (Versiani et al, 2016). Most of the MMC orifices are at the cemento-enamel junction (CEJ) level, however it may also be detected at 1 mm and 2 mm depths from the CEJ and even deeper (Kele & Keskin, 2017), and may need an additional groove preparation.

There are also reports of the presence of three root canals in the distal root, with the incidence of 0.2-3% (Kotthor et al, 2010).

Analysing the morphology of the mesial root, type IV, according to Vertucci classification, was most often identified (52.3%), and type II in 35% of cases (de Pablo et al, 2010). In the distal root, the most often identified was type I (62.7%), and type II (14.5%) (de Pablo et al, 2010).

The usage of the intraoral radiographs, a dental operating microscope, a sharp explorer, and staining with methylene blue dye are commonly accepted principles for primary endodontic treatment (de Carvalho & Zuolo, 2000; Chavda & Garg, 2016). However, radiographs provide a very simple two-dimensional image, hiding the complex structure of root canals, making the evaluation of the morphological

structure of the molars complex and challenging. At the same time, the use of 3D analysis has undeniable advantages in the identification of morphological variations of teeth (Durack & Patel, 2012; de Paula et al, 2013). Nevertheless, the use of this method is limited for the primary endodontic treatment due to the ALARA principle, which states that every effort should be made by professionals to keep the patient's exposure to ionising radiation as low as practically possible (Farman, 2005). In this case report, the preoperative 3D examination, and CBCT one year after the treatment were not performed for the endodontic treatment of teeth LR6 and LR6, but for the examination, diagnosis, planning and evaluation of results of surgical treatment on the mandible. The technique enabled to evaluate the complexity of the morphology of lower molars before the endodontic treatment.

Case report

A 30-year-old female patient was referred to the clinic with the chief complaint of spontaneous pain in the lower right region of the jaw for the previous three days. The patient's medical and family history was non-contributory. On clinical examination, a deep carious lesion was seen in tooth LR6. Thermal testing of the right mandibular first molar caused intense, lingering pain. Percussion and palpation in the region of this tooth were painless and investigations for sinus tract and periodontal involvement were negative.

The preoperative sagittal section of CBCT (Figure 1) revealed radiolucency on the occlusal surface of the crown, approaching the pulp space in the LR6. The coronal sections of CBCT of the mesial (Figure 2) and distal root (Figure 3), revealed two root canals in each of them. The axial section (Figure 4) confirmed MMC in the tooth LR6.

A diagnosis of symptomatic irreversible pulpitis was made, based on the clinical and radiographic examination, and we recommended conservative endodontic treatment. The patient declined alternative treatment methods.

After administration of conductive anaesthesia (Ubistesin 4% 1:100000 (3M Oral Care) and rubber dam isolation of the operative area, we performed access to the pulp chamber using long neck drills and ultrasonic tips. The pulp chamber was rinsed with 6% sodium hypochlorite (NaOCl). We used staining with methylene blue dye and Micro-Opener 15.04 (Dentsply Maillefer) under the optical magnification to examine the pulp chamber floor.

After access preparation and a careful analysis of the floor, we found two root canals in the mesial roots and two root canals in the distal ones. The orifice of the MMC was found

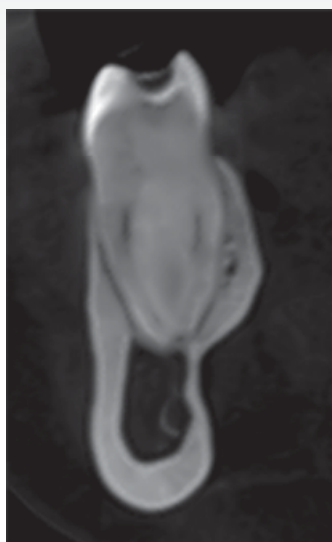


Figure 2.

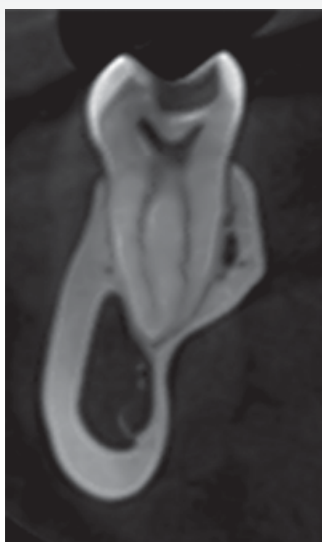

Figure 3.

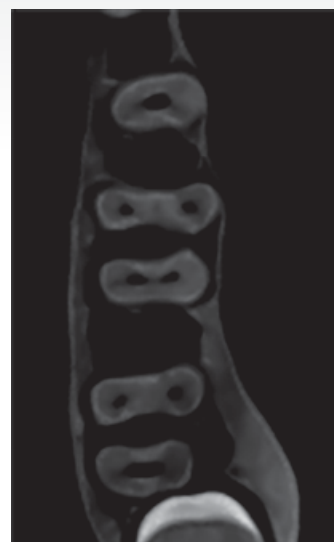

Figure 4.

after developmental groove preparation by the ultrasonic tip in the mesial root between the previously identified ML and MB canals. It is necessary to remember that the diameter of the MMC canal is smaller in comparison with the ML and MB canals, and due to the anatomical danger zones, it requires more careful preparation (De-Deus et al, 2019; Keles et al, 2020).

We negotiated the canals, and established patency at working length with 10 K-file (Dentsply Maillefer) using an I-pex apex locator (NSK, Japan) and confirmed with radiographs. A size 15 K-file Nitiflex (Dentsply Maillefer) was used to perform the glide path.

We then conducted the shaping of the root canals using the Protaper Next X1 (Dentsply Maillefer) instrument, followed by the XP-endo Shaper (FKG), and 35/.04 BT-Race (FKG). At each change of the endodontic instrument, we irrigated

the canals with 6% NaOCl. For better purification of the isthmus, Micro-Debriders (Dentsply Maillefer) were used.

At the end of the preparation, we applied 17% ethylenediaminetetraacetic acid (EDTA) for one minute to remove the smear layer and performed the irrigation with a copious volume of 6% NaOCl. XP-endo finisher (FKG) was used within 15 seconds to activate all of the solutions, applying slow, gentle longitudinal movements of 7-8 mm to cover the entire length of the canal. Before the obturation, we rinsed all canals with saline. All master cones were processed antiseptically, fitted and set on a working length. The canals were partially dried with paper points and obturated by the cold hydrodynamic obturation technique of gutta-percha and premixed bioceramic sealer Totalfill (FKG). We cleaned the pulp chamber in order to remove the excess of gutta-percha and bioceramic sealer, temporarily restored the tooth with resin composite and made the post-treatment radiograph of tooth LR6 (Figure 5). Then we referred the patient for the permanent restoration of tooth LR6.

We were able to evaluate the complexity of the morphology of tooth LR6 and its obturation, with the CBCT (Planmeca ProMax, Finland) of the mandible one year after the treatment (Figures 6-9).

In the medial system, the pulp space separates into three canals and two of them join into one during its course to exit as two root canals (Figure 7), which are the 3-2 type according to the classification of the root canal morphology (Gulabivala et al, 2001; Sert & Bayirli, 2004; Bansal et al, 2018).

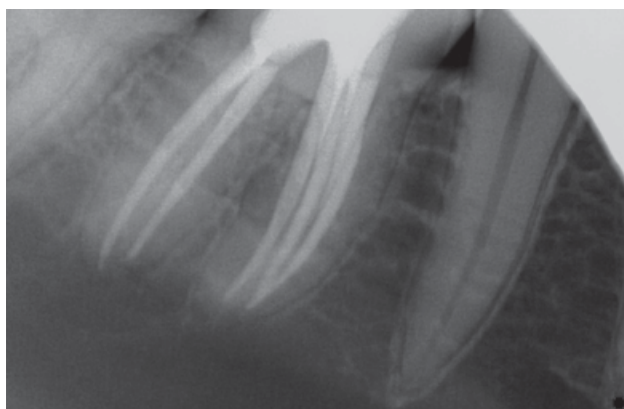


Figure 5.

NOT ALL BIOMATERIALS ARE THE SAME – TAKE A CLOSER LOOK!

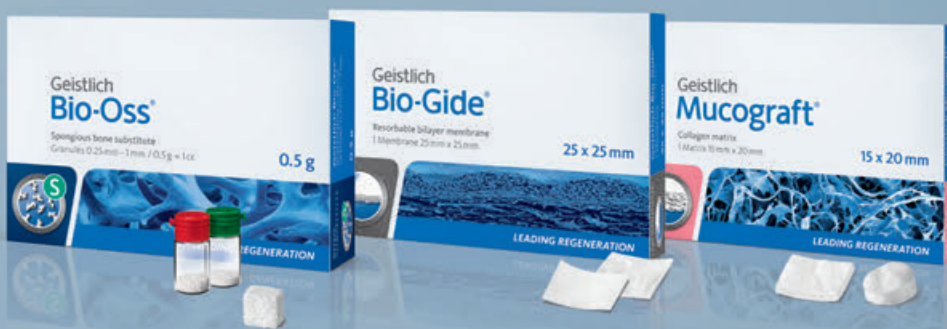YOUR WORLDWIDE
NO.1 REFERENCE

OUTSTANDING
QUALITY

UNIQUE
BIOFUNCTIONALITY

- > 91.9% implant survival rate after 12–14 years¹
- > Well preserved and stabilized buccal bone wall after 5–9 years^{2,3}
- > Long-term volume stability⁴

EXCLUSIVELY
AVAILABLE AT
HENRY SCHEIN



More details about our products:
www.geistlich-biomaterials.com

References

¹ Jung R et al., Clin Oral Implants Res. 2013 Oct;24(10):1065–73

² Buser D et al., J Periodontol. 2013 Nov;84(11):1517–27

³ Jensen SS et al., J Periodontol. 2014 Nov;85(11):1549–56

⁴ Mordenfeld A et al., Clin Oral Implants Res. 2010 Sep;21(9):961–70

 **swiss made**

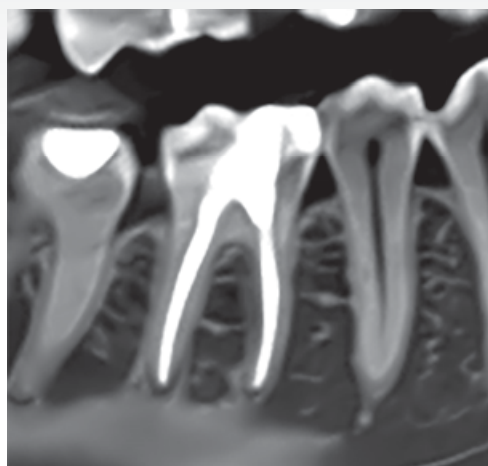


Figure 6.

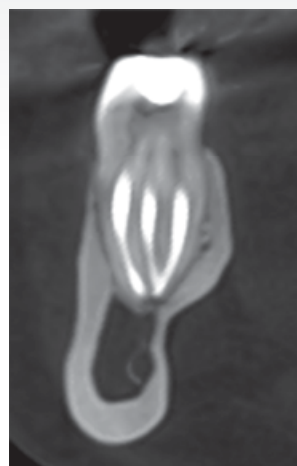

Figure 7.

In the distal system (Figure 8), two canals run separately from orifice to apex, which corresponds to the type 2-2 classification of root canals morphology (Vertucci, 1984; Weine et al, 1988; Bansal et al, 2018). Axial CBCT slice of tooth LR6 confirmed three root canals in the medial and two root canals in distal roots (Figure 9).

After a short while, the same patient was referred to the clinic with the chief complaint of intermittent moderate pain in the lower-left region of the jaw. On clinical examination, we could see a deep carious lesion in tooth LL6. Pulp thermal testing caused intense, extended pain. The percussion test of the tooth LL6 was negative. The tooth was apically painless to palpation. The periodontal probing near LL6 was within the physiological norm.

A preoperative sagittal section of CBCT (Figure 10) revealed radiolucency on the occlusal surface of the crown,

approaching the pulp space in the LL6. The coronal sections of CBCT showed two root canals of the medial root (Figure 11) and two main canals in the distal root (Figure 12). The axial sections (Figure 13) confirmed MDC in the tooth LL6.

All clinical signs indicated symptomatic irreversible pulpitis and conservative endodontic treatment was recommended. As the patient declined alternative treatment methods, we carried out the treatment of tooth LL6 according to the same main principle as mentioned above.

After anesthesia (Ubistesin 4% 1:100000 (3M Oral Care) and rubber dam isolation of the operative area, we gained access to the pulp chamber. We then investigated the bottom of the pulp chamber with Micro-Opener 15.04 (Dentsply Maillefer) under optical magnification. The pulp chamber was antiseptically processed.

As in the previous case, during the examination of the bottom of the pulp chamber, we found two root canals in the mesial roots and two root canals in distal ones. Based on the CBCT data, we made the preparation of the developmental groove in the distal root between the identified DL and DB canals and the orifice of the MDC was found approximately 3 mm below the CEJ.

Afterwards, we negotiated canals, and established patency at working length with 10 K file (Dentsply Maillefer) using an I-pex apex locator (NSK, Japan) and confirmed with radiographs. A size 15 K file Nitiflex (Dentsply Maillefer) was used to perform the glide path. The mechanical instrumentation of the root canals was performed using the 10/.06 BTRace (FKG) instrument followed the XP-endo Shaper (FKG), and 35/.04 BTRace (FKG), with isthmus cleaning with the Micro-Debridors (Dentsply Maillefer). At

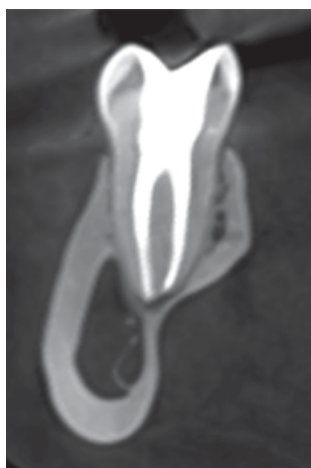

Figure 8.

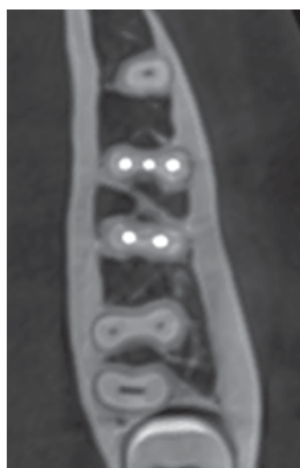


Figure 9.

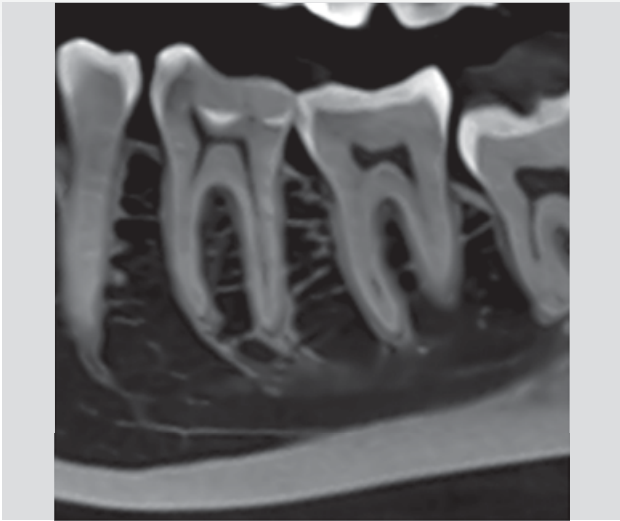


Figure 10.

each change of instrument, we irrigated the canals with a 6% NaOCl. At the final stage of biomechanical preparation, 17% EDTA was applied for one minute succeeded by the copious amount of 6% NaOCl. To activate the solutions we used the XP-endo Finisher (FKG). Before the obturation, all canals were rinsed with saline. We processed all master cones antiseptically, then fitted and set them on a working length.

The canals were partially dried with paper points and we carried out the cold hydrodynamic obturation technique of gutta-percha and bioceramic sealer TotalFill (FKG) to obturate them. The cleaning of the pulp chamber was performed and glass-ionomer cement and resin composite were applied to

temporarily restore the tooth. We took the post treatment radiograph of tooth LL6 (Figure 14). The patient was then referred for the permanent restoration of tooth LL6.

The patient was recalled at six and twelve months postoperatively. At follow-up appointments, the LL6 and LR6 teeth were asymptomatic and functional.

We used the same CBCT (Planmeca Promax, Finland) of the mandible to evaluate the complexity of the morphology of tooth LL6 and its obturation, one year after the treatment (Figures 15-18).

In the mesial system, two separate root canals with separate orifices and two separate apexes (Figure 16) that correspond to type 2-2 morphology of root canals system (Vertucci, 1984; Weine et al, 1988; Bansal et al, 2018).

Distal root canals correspond to type 2-3-1: two canals divide into three and then during its course unite into one (Sert & Bayirli, 2004; Al-Qudah & Awawdeh, 2009; Bansal et al, 2018). Root canals overlap one another on the postoperative radiograph (Figure 14). Axial slice of CBCT tooth LL6 confirmed two root canals in mesial and three root canals in the distal roots (Figure 18).

Discussion

Endodontic treatment of mandibular molars requires a high level of knowledge and clinical skills due to their anatomical variations. In one of the studies it was claimed that the middle mesial canal can be rather the sequelae of instrumenting the isthmus between the mesiobuccal and mesiolingual canals than an extra canal (Mortman & Ahn, 2003). However, according to more recent studies, the true third canal in the mesial root of the mandibular first molar was found up to 18%

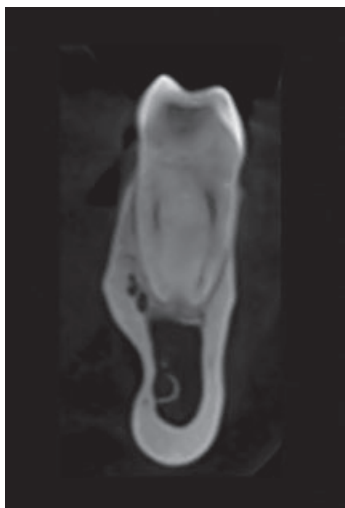


Figure 11.

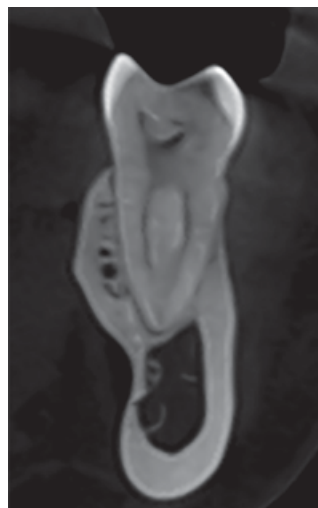


Figure 12.

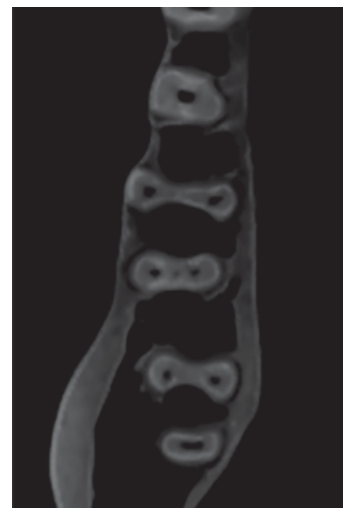

Figure 13.

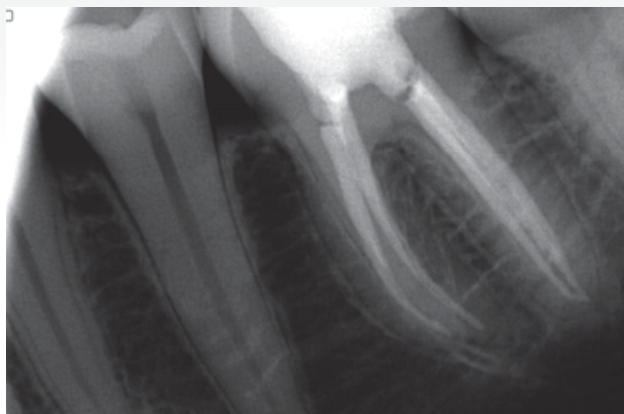


Figure 14.

(Navarro et al, 2007; de Pablo et al, 2010; Versiani et al, 2016), and 0.2-3% in the distal root (Kottoor et al, 2010).

Teeth with atypical canal configuration complicate the process of identifying and accessing root canals in the endodontic treatment. CBCT has the ability to overcome the limitations of conventional radiography such as three-dimensional evaluation of the complex canal anatomy during endodontic treatment (Durack & Patel, 2012; de Paula et al, 2013), but it is necessary to remember that, in usual practice, a post treatment CBCT must be confirmed by appropriate indications and meet with current guidelines regarding ALARA.

The dental operating microscope is necessary for the detection of accessory canals in mandibular molars (de Carvalho & Zuolo, 2000; Karapinar-Kazandag et al, 2010).

At the present stage of the development of endodontics,

it is impossible to carry out a complete cleaning of the root canal system. When flat, or curved root canals with oval cross-sections are considered, the most current rotary nickel-titanium file systems will not adequately clean and shape the canal with favorable results (Metzger et al, 2010).

Therefore, an endodontic file should be used, which adapts to the natural morphology of the root canals and efficiently cleans it. Appropriate shaping and cleaning of the root canal system with the XP-endo Shaper and XP-endo Finisher instruments used for this clinical case have the potential to improve root canal system cleaning (Azim et al, 2016; Azim et al, 2017).

Conclusion

Professionals should always consider morphological variations of the root canal system before the beginning of treatment.

This case report reinforces the importance of using cone-beam computed tomography, to evaluate the complexity of the morphology of teeth before the endodontic treatment.

The favourable clinical and radiographic outcome in this case demonstrated that the treatment approach followed in the present case is effective in solving complex clinical challenges.

References

- Almeida G, Machado R, Sanches Cunha R, Vansan LP, Neelakantan P (2015) Maxillary first molar with 8 root canals detected by CBCT scanning. *Gen Dent* 63(2): 68-70
- Al-Qudah AA, Awawdeh IA (2009) Root and canal morphology of mandibular first and second molar teeth in a Jordanian population. *Int Endod J* 42(9): 775-84
- Azim AA, Aksel H, Zhuang T, Mashtare T, Babu JP, Huang GT (2016) Efficacy of 4 irrigation protocols in killing bacteria

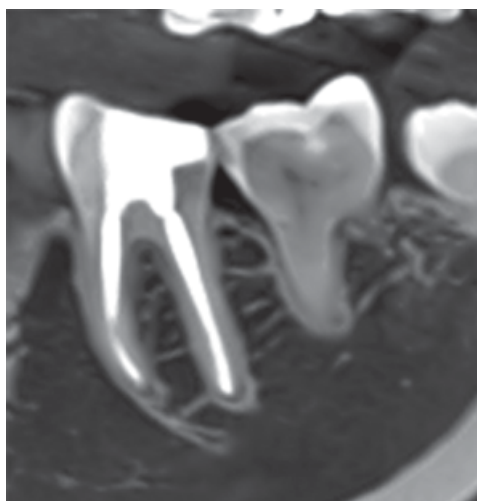

Figure 15.

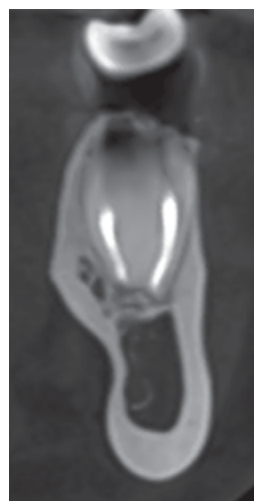

Figure 16.

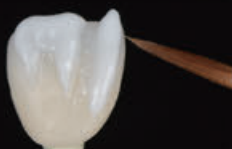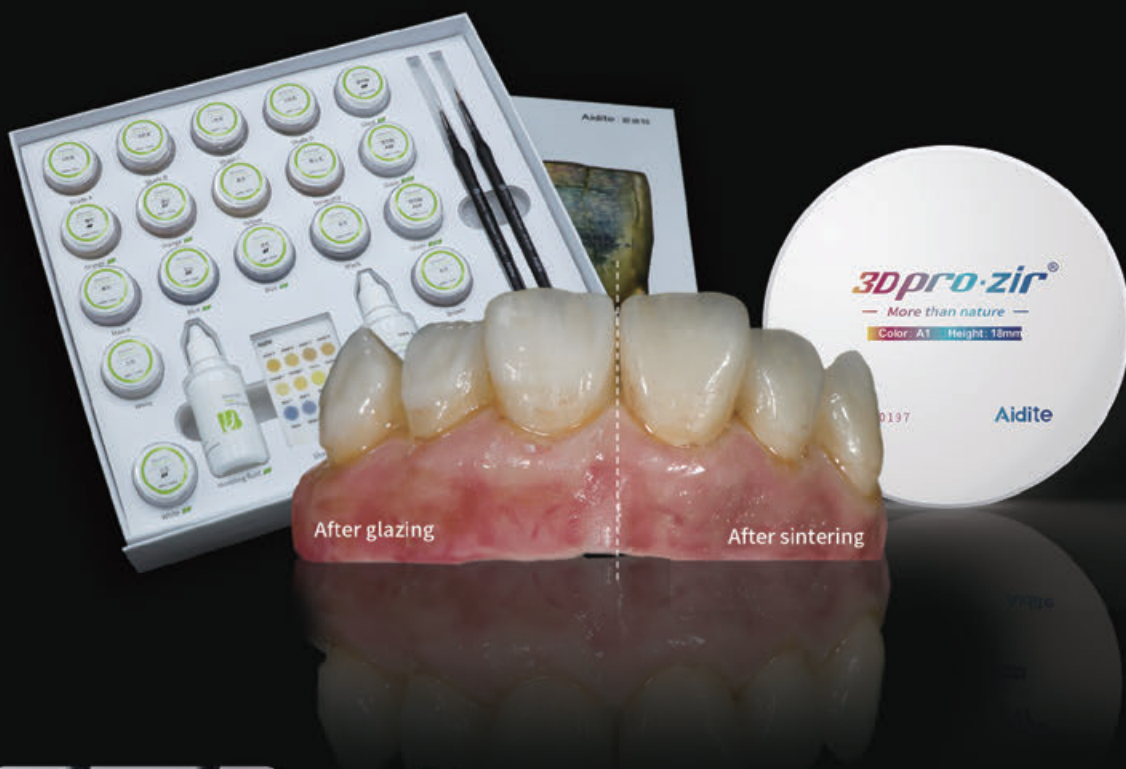Aidite®



Realize reproducible natural teeth

CREATE YOUR BIOMIC CROWN

·Bionic aesthetics ·Multiple Indication ·No ageing



·All in one

A Stain/Glaze suitable for all types of ceramic restorations like zirconia, glass ceramic, porcelain, etc., Universal coloration system for all restorations

·Simple to use

The coloration pastes are simple and user friendly
technicians can utilize the simple system to achieve ideal aesthetic results

·Bionic aesthetics

The composition of 2D paste color in completely mimics the colors of natural teeth
3D pastes can be used to adjust the tooth surfacemorphology and slight contour distinctions.

■ Biomic—Simple Aesthetics for Monolithic Restoration



Local distributor: Add:shope 8A.1 New street, Hoofstraat Paarl, Western Cape, South Africa / Email:deonfdelange@gmail.com / TEL:+27 82 779 5595

Aidite (Qinhuangdao) Technology Co.,Ltd. / Tel :0086-335-8357769 / Email :info@aidite.com

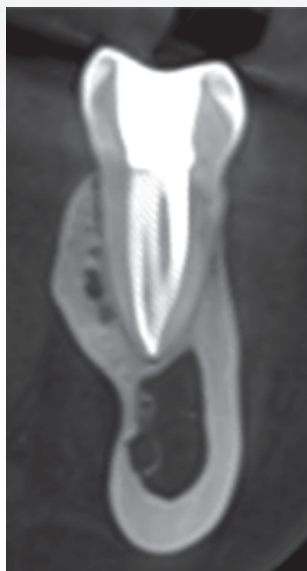

Figure 17.

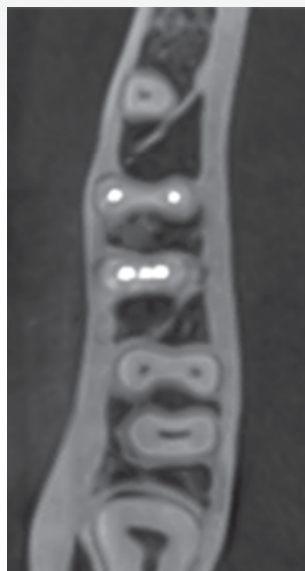

Figure 18.

colonized in dentinal tubules examined by novel confocal laser scanning microscope analysis. *J Endod* 42(6): 928-34

Azim AA, Plasecki L, da Silva Neto UX, Cruz ATG, Azim KA (2017) XP-Shaper, a novel adaptive core rotary instrument: Micro-computed tomographic analysis of its shaping abilities. *J Endod* 43(9): 1532-8

Bansal R, Hegde S, Astekar MS (2018) Classification of root canal configurations: A review and a new proposal of nomenclature system for root canal configuration. *Journal of Clinical and Diagnostic Research* [Internet]. May 12(5):1-5

Berutti E, Cantatore G, Castellucci A et al (2009) Use of nickel-titanium rotary PathFile to create the glide path: comparison with manual preflaring in simulated root canals. *J Endod* 35(3): 408-12

Chavda SM, Garg SA (2016) Advanced methods for identification of middle mesial canal in mandibular molars; An in vitro study. *Endodontology* 28(2): 92-6

de Carvalho MC, Zuolo ML (2000) Orifice locating with a microscope. *J Endod* 26(9): 532-4

DeDeus G, Rodrigues EA, Belladonna FG et al (2019) Anatomical danger zone reconsidered: a micro-CT study on dentine thickness in mandibular molars. *Int Endod J* 52(10): 1501-7

de Pablo OV, Estevez R, Péix Sánchez M, Heilborn C, Cohenca N (2010) Root anatomy and canal configuration of the permanent mandibular first molar: a systematic review. *J Endod* 36(12): 1919-31

de Paula AF, Brito-Júnior M, Quintino AC, Camilo CC, Cruz-Filho AM, Sousa-Neto MD (2013) Three independent mesial canals in a mandibular molar: Four-year followup of a case using cone beam computed tomography. *Case Rep Dent*

Durack C, Patel S (2012) Cone beam computed tomography in endodontics. *Br Dent J* 23(3): 179-91

Farman AG (2005) ALARA still applies. *Oral Surg Oral Med Oral Pathol Oral Radiol Endod* 100(4): 395-7

Fava LRG (2001) Root canal treatment in an unusual maxillary first molar: A case report. *Int Endod J* 34: 649-53

Gulabivala K, Aung TH, Alavi A, Ng YL (2001) Root and canal

morphology of Burmese mandibular molars. *Int Endod J* 34(5): 359-70

Karapinar-Kazandag M, Basrani BR, Friedman S (2010) The operating microscope enhances detection and negotiation of accessory mesial canals in mandibular molars. *J Endod* 36(8): 1289-94

Keleş A, Keskin C (2017) Detectability of middle mesial root canal orifices by troughing technique in mandibular molars: a micro-computed tomographic study. *J Endod* 43(8): 1329-31

Keleş A, Keskin C, Algawasmi R, Versiani M (2020) Evaluation of dentine thickness of middle mesial canals of mandibular molars prepared with rotary instruments: a micro-CT study. *Int Endod J* 53(4): 519-28

Kottoor J, Sudha R, Velmurugan N (2010) Middle distal canal of the mandibular first molar: a case report and literature review. *Int Endod J* 43(8): 714-22

Leonardo MR (1998) Aspectos anatomicos da cavidade pulpar: relações com o tratamento de canais radiculares. In: Leonardo MR, Leal JM editors. *Endodontia: tratamento de canais radiculares*. 3rd edn. pp. 191 Sao Paulo: Panamericana

Metzger Z, Zary R, Cohen R, Teperovich E, Paque F (2010) The quality of root canal preparation and root canal obturation in canals treated with rotary versus Self-adjusting files: a three-dimensional micro-computed tomographic study. *J Endod* 36(9): 1569-1573

Mortman RE, Ahn S (2003) Mandibular first molars with three mesial canals. *Gen Dent* 51(6): 549-51

Navarro LF, Luzi A, Garcia AA, Garcia AH (2007) Third canal in the mesial root of permanent mandibular first molars: review of the literature and presentation of three clinical reports and two in vitro studies. *Med Oral Patol Oral Cir Bucal*. 12(8): 605-9

Pomerantz HH, Eidelman DL, Goldberg MG (1981) Treatment considerations of the middle mesial canal of mandibular first and second molar. *J Endod* 7(12): 565-8

Sert S, Bayirli GS (2004) Evaluation of the root canal configurations of the mandibular and maxillary permanent teeth by gender in the Turkish population. *J Endod* 30(6): 391-8

Song M, Kim HC, Lee W, Kim E (2011) Analysis of the cause of failure in nonsurgical endodontic treatment by microscopic inspection during endodontic microsurgery. *J Endod* 37(11): 1516-19

Versiani MA, Ordinola-Zapata R, Keleş A, Alcín H, Bramante CM, Pécora JD, Sousa-Neto MD (2016) Middle mesial canals in mandibular first molars: a micro-CT study in different populations. *Arch Oral Biol* 61: 130-7

Vertucci F (1984) Root canal anatomy of the human permanent teeth. *Oral Surg Oral Med Oral Pathol*, 58(5): 589-99

Vertucci FJ (2005) Root canal morphology and its relationship to endodontic procedures. *Endod Topics* 10: 3-29

Vertucci FJ, Haddix JE, Britto LR (2006) Tooth morphology and access cavity preparation. In: Cohen S, Hargreaves KM, editors. *Pathways of the pulp*, 9th edn; Louis MO USA: Mosby. pp 148-232

Weine FS, Pasiewicz RA, Rice RT (1988) Canal configuration of the mandibular second molar using a clinically oriented in vitro method. *J Endod* 14(5): 207-13

Reprinted with permission from Endodontic Practice September 2020

