

A full digital workflow with 3D-printed temporary restorations

Anthony Mak¹ and Andrew Chio²

The evolution of digital technologies in dentistry has paved the way for the development of simplified and predictable protocols in field of restorative dentistry. Digital dental technologies have allowed the seamless delivery of complex treatments.

Proper treatment planning protocols are the foundation of any fixed restorations in the arch involving dental implants. The data or information from the CBCT scan and intraoral surface scans (IOS) combined with the use of CAD software allow the simplification of workflows including diagnostic facially driven mock-ups, restoration-driven implant treatment planning and the design and fabrication of surgical guides. The design of the temporary and permanent prosthesis and the design of the master die model can all be done on CAD software and then manufactured either with 3D printing or milling. The prosthetic design can be visualized, planned and even designed prior to the patient even attending for the surgical phase of treatment.

An accurate and predictable outcome of the implant surgery as well as the restorative rehabilitation are realised this way.

The following case study demonstrates a scenario where a complete digital workflow was utilised with two provisionalisation phases to rehabilitate the full upper arch.

Case report

Diagnostic Record Collation and Treatment Planning Phase

A 79-year old patient presented with an unremarkable health history.

Chief complaint:

- mobile teeth
 - occasional discomfort from the areas around his existing upper fixed partial denture
- Examination (both clinical and radiographic) indicated the following (Fig. 1):
- moderate to advanced bone loss affecting many of his upper and lower teeth.

¹ Dr Anthony Mak, BDS (USyd),
Grad Dip
Clin Dent (Oral Implants) (USyd),
Private Practice, Sydney, Australia,
focusing on comprehensive and
implant dentistry.

² Dr. Andrew Chio, BDS (Melb.)
Private Practice, Melbourne, Australia

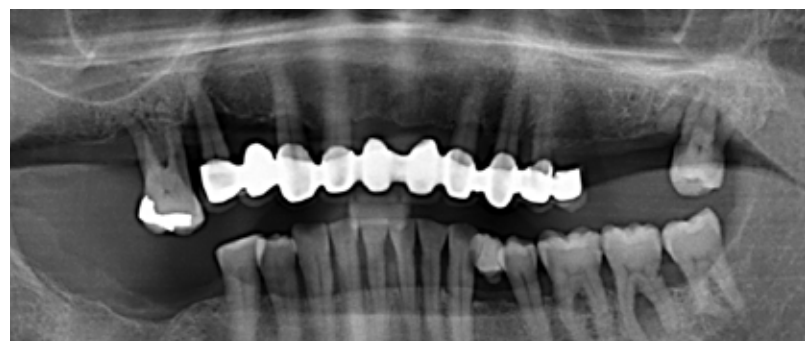
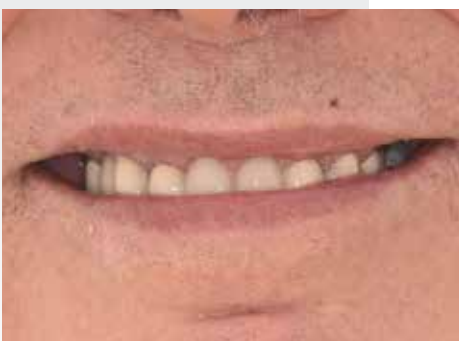
Figure 1: Pre-operative smile and orthopantomogram.

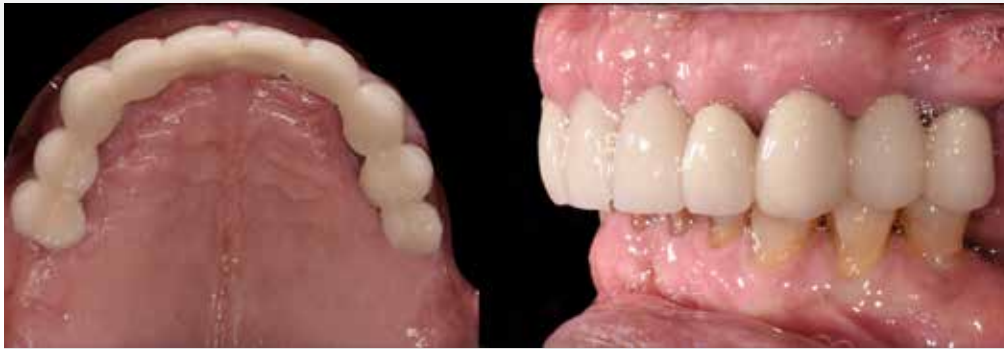

Figure 2: Occlusal and lateral view after periodontal treatment and extraction of tooth 16 and 28.

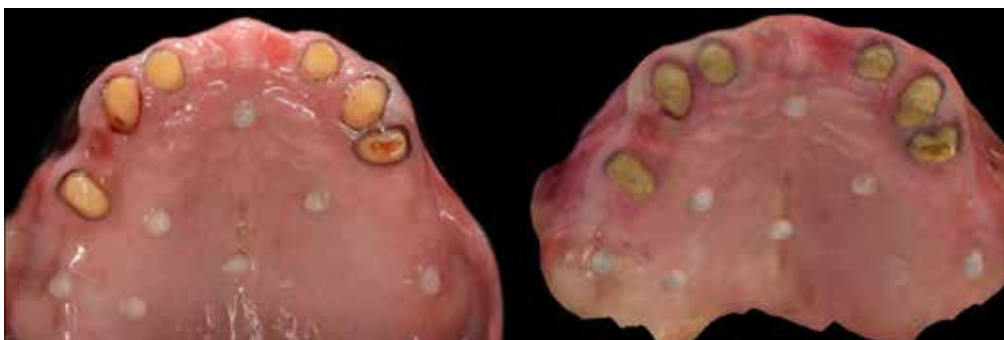

Figure 3: The accuracy of image registration between the CBCT and IOS scans can be improved with radiographic markers (composite blobs). Removing sources of radiographic scatter (in this case, the PFM bridge) also improves the accuracy.

- secondary decay was diagnosed on the abutments of his fixed dental prosthesis.
- Teeth 15, 16 and 28 had a poor prognosis and were planned for extraction.

The goal of the treatment was to rehabilitate the upper arch with a combination of crowns and implant retained restorations to provide the patient with a fixed solution.

In the initial treatment phase, teeth 16 and 28 were extracted and the remaining dentition was periodontally treated (Fig. 2).

After the initial clinical examination and treatment, further information was collated. This included:

- 3D CBCT scanning for the presurgical planning.
- Intra-oral scans (IOS): digital impressions before and after removal of the original PFM bridge were taken, as well as the patient's occlusion (bite). Rough preparation of the tooth abutments were also completed prior to the acquisition of the subsequent IOS scan.

Tip: the accuracy of image registration (superimposition of the IOS and CBCT data) can be enhanced by (Fig. 3):

- the use of radiographic reference markers: a composite such as G-aenial Universal Injectable with a radiopacity of 250% Al, does not result in radiographic scattering during CBCT scans.
- prior removal of the porcelain-fused-to-metal (PFM) bridge: reduction of radiographic scatter caused by the metallic components of the prosthesis

Treatment Plan

Following the collation of the information, the initial treatment plan was formulated and involved:

- Guided surgical placement of implant fixtures in the 16, 14, 11, 21 and 25 sites. A bone graft was also planned in the 11 site due to bony defects. A two-stage surgical protocol was chosen for proper integration of the implants in the 11 and 21 site.
- Immediate provisionalization with a 3D-printed temporary bridge (GC Temp PRINT) from 15 to 24. The existing shape and contours of the current failing bridge were copied from the pre-operative IOS to create the temporary bridge.

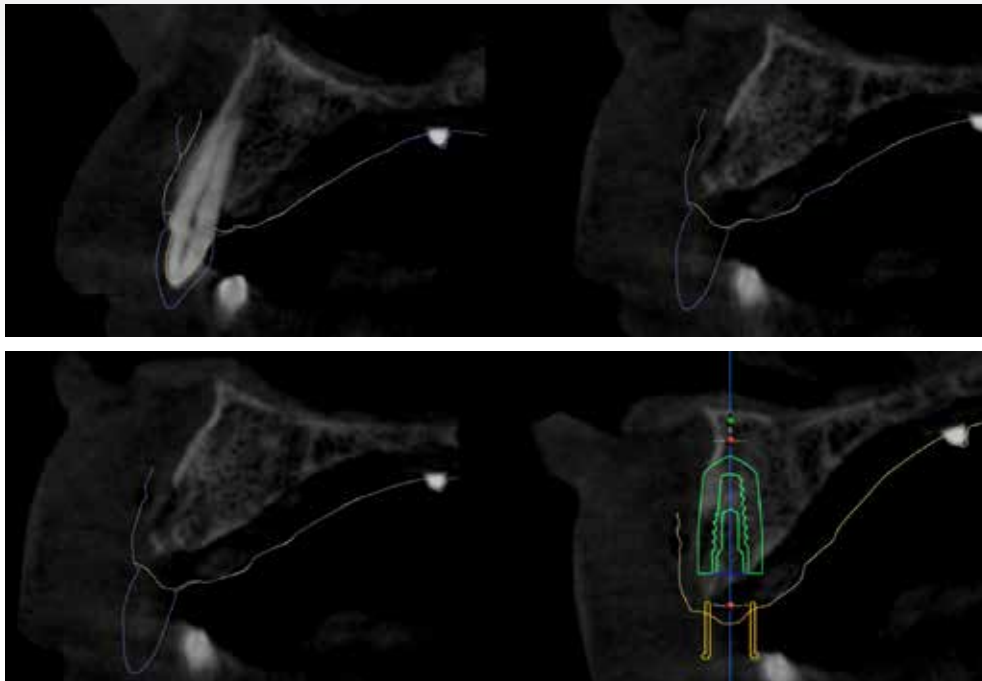


Figure 4: Intraoral surface scans (IOS) before and after removal of the original PFM bridge superimposed on the CBCT scan: this facilitates the planning of implant placement from a restorative perspective (restoration driven implant placement).

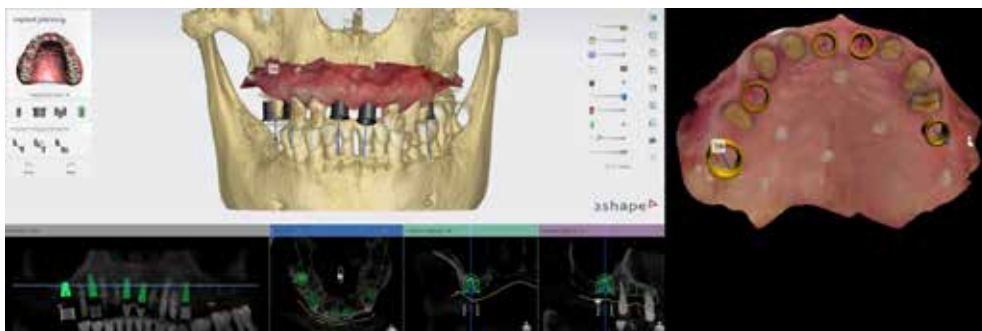


Figure 5: Planning of implant placement. A surgical guide is designed based on the desired implant position.

- After implant integration, a second phase of provisionalization was foreseen with individual temporary restorations (GC Temp PRINT) on the implants and natural teeth. This allowed:
 - Verification of aesthetics and occlusion
 - Soft tissue management
 - Extraction of tooth 15.
 - It was planned to use lithium disilicate and monolithic zirconia for the permanent restorations on both the natural teeth and implant abutments.

Digital Implant Planning and Surgical Guide Fabrication

Digital data from the three scans – the CBCT and the IOS before and after bridge removal - were accurately merged. This enabled virtual planning of the number, position, angulation and access position of the implant fixtures following a restoratively driven protocol (Fig. 4).

Based on the planned implant positioning (Fig. 5), a surgical guide was designed with the dedicated software. Master sleeves from the guided surgical system were placed

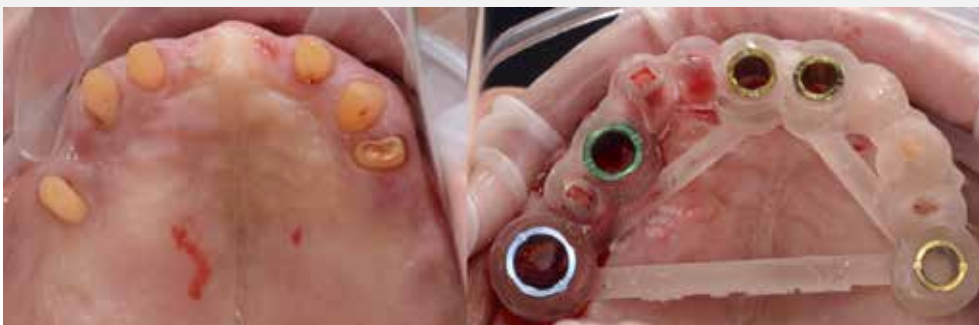

Figure 6: Five implant fixtures were placed using a fully guided surgical protocol.

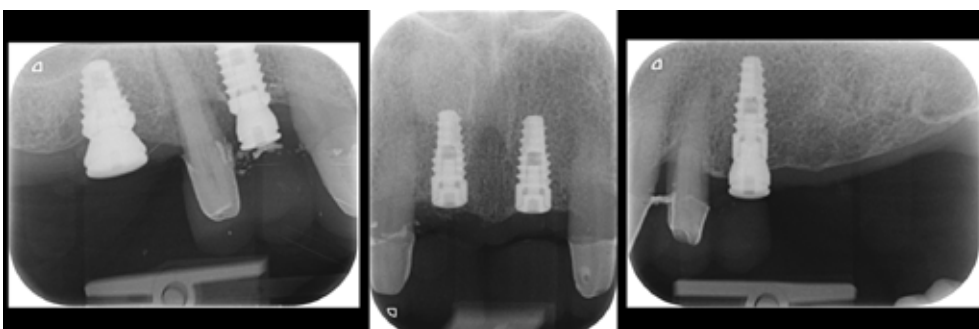


Figure 7: A flap was raised in the 11 region as buccal bone grafting was required due to a bony defect.

and fixed to the printed guide/framework.

The design of the previous PFM was also copied and replicated in the digital planning of the temporary bridge. It was then printed using the Asiga Max UV and GC Temp PRINT (medium shade) set at 50µm on the 3D printer.

Guided Implant Surgery and First Provisionalization Phase

The following clinical procedures were then completed on the day of implant surgery:

- All five implant fixtures were placed following a fully guided surgical protocol with the surgical guide (Fig. 6) and primary stability was confirmed.
- A flap was raised in the 11-21 region, a bone graft with

bovine cancellous particulate was placed and covered with a porcine collagen membrane. Cover screws were placed and primary closure was established after a relieving incision and closed with PTFE sutures. At the other implant sites (16, 14 and 25), healing abutments were placed (Fig. 7).

- The 3D-printed temporary bridge was then cemented with GC Fuji TEMP LT on the remaining natural teeth (Fig. 8). A healing period of 16 weeks allowed complete osseointegration of the implant fixtures. During this period, tooth 24 (upper left first premolar) developed signs and symptoms of pulpal necrosis. Hence, it was endodontically treated (Fig. 9).

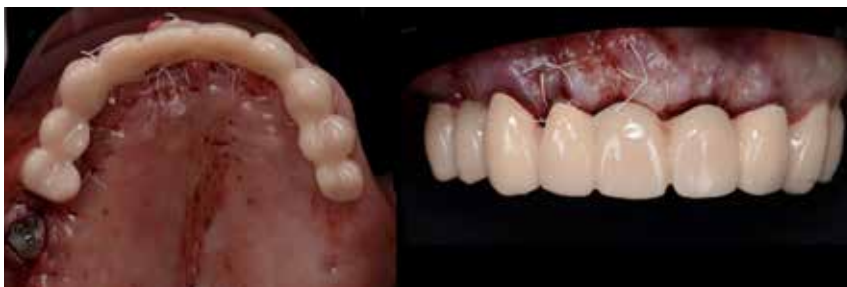

Figure 8: Immediate post-operative following guided implant surgery and temporary cementation of the provisional fixed bridge printed from GC Temp PRINT (medium shade).

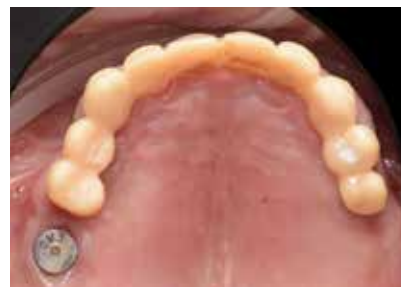

Figure 9: During the healing phase, tooth 24 developed pulpal necrosis and was endodontically treated.

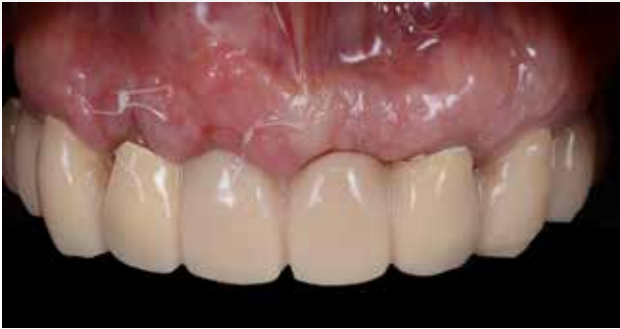

Figure 10: View at 10 days after implant surgery.

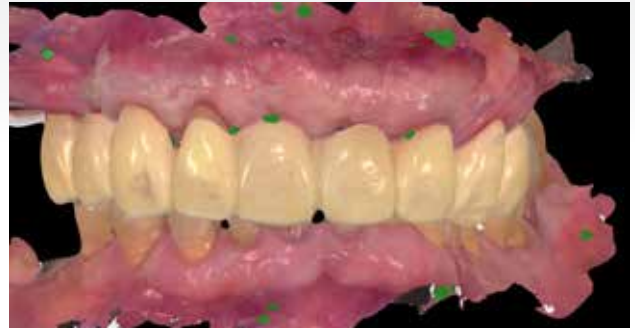

Figure 11: Pre-operative surface scan.

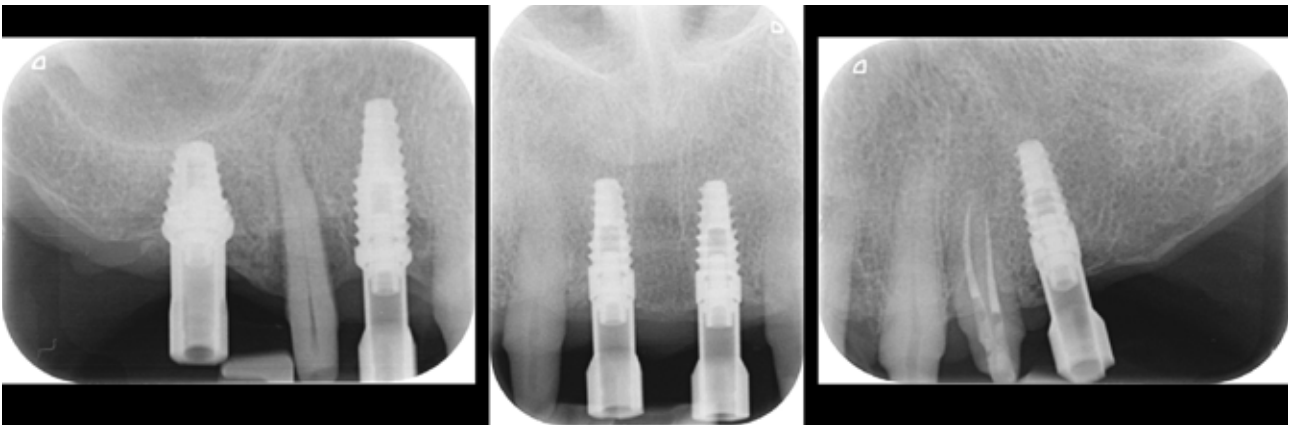


Figure 12: Periapical radiographs to verify the seat of the digital scan bodies.

Second Provisionalization Phase after Implant Integration.

Once the 16-week healing phase was completed and the fixtures were integrated, the restorative phase could be initiated. The patient confirmed that he was happy with the shape and occlusion of the initial temporary bridge (Fig. 10). The aesthetic and occlusal scheme could therefore be replicated in the second phase of provisionalization.

A pre-preparation IOS was taken with the healing abutment and temporary bridge in situ (Fig. 11).

The temporary bridge was then removed and preparation of the abutment teeth finalized and re-margined to the healed gingival tissue levels.

Stage 2 implant surgery on the 11 and 21 sites was completed using a soft tissue diode laser. The implants were exposed and cover screws removed.

An emergence profile scan was taken immediately after the healing abutments were removed to record gingival contours around the implant before any collapse of the tissues. Next, the full upper arch was scanned with digital

scan bodies in place to capture the implant position accurately (Fig. 12).

All other prosthodontic records including the bite registration and the opposing arch were also captured with the intra-oral scanner before placing the temporary bridge back. All IOS were taken following the "Mak optimised scan strategy" (MOSS), allowing accurate stitching of IOS images. In soft tissue "pink" areas, the availability of landmarks is often limited; MOSS uses a specific scan path with or without markers for an enhanced scan accuracy and was especially designed for cases with few teeth to correlate to.

All the digital data was then sent to the ceramist for the fabrication the second set of provisional restorations. Provisional restorations were printed with GC Temp PRINT and characterised with OPTIGLAZE color (GC). Temporary abutment cylinders were utilised for the implant-retained restorations. The contours of the 11 and 21 implant-retained provisionals as well as the pontic of 15 were designed and fabricated to shape the soft tissues for optimal support and

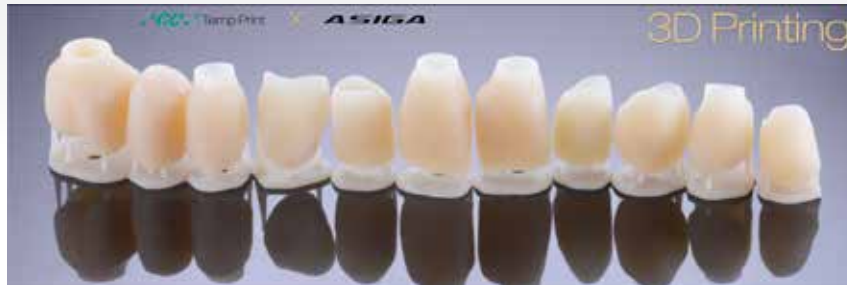

Figure 13: Second set of provisional restorations printed with GC Temp PRINT (medium shade) using the Asiga Max UV 3D printer.

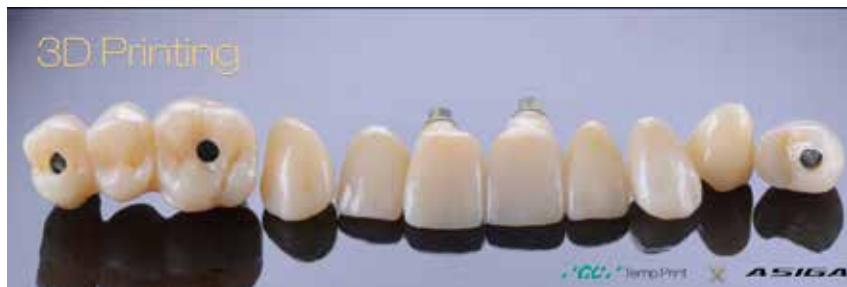

Figure 14: Completed provisional crowns, implant retained crowns and bridge, characterised with OPTIGLAZE color (GC) – Dental technician: Brad Groblar, Oral Dynamics, New Zealand.

(Figs. 13-15).

Following removal of the temporary bridge, all the abutments were cleaned and the tooth 15 was extracted (Fig. 16). The provisional implant restorations, fabricated

with direct screw access were torqued to the manufacturer's recommendation. All other temporary printed restorations were cemented with FujiTemp (GC) (Figs. 17-19).

The soft tissues were prosthetically shaped and allowed to

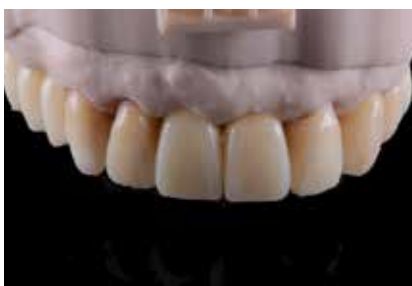
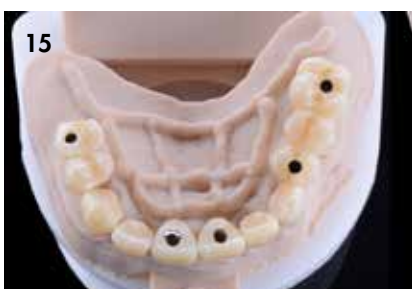
Figure 15: Completed provisionals fitted onto the printed models to allow the refinement of the contact points and occlusal contacts.

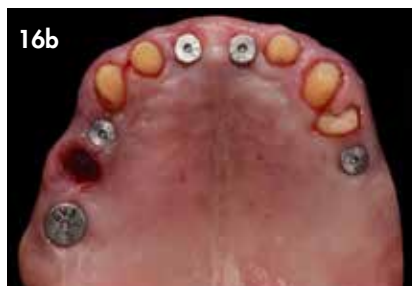
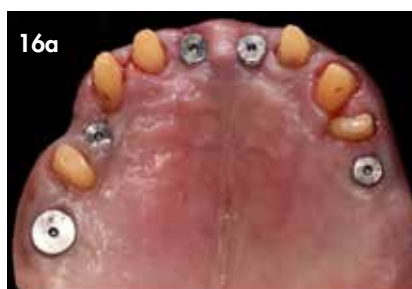
Figure 16: (a) After removal of the temporary bridge from the first provisionalization phase. (b) Tooth 15 was extracted.

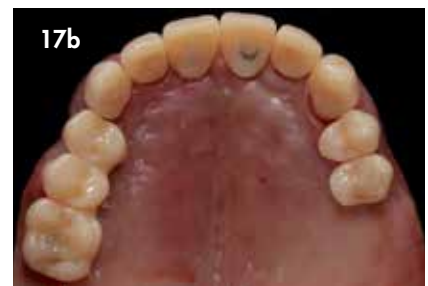
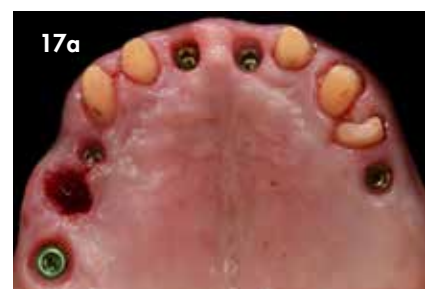
Figure 17: (a) Healing abutments were removed and (b) the second set of temporary restorations was placed.

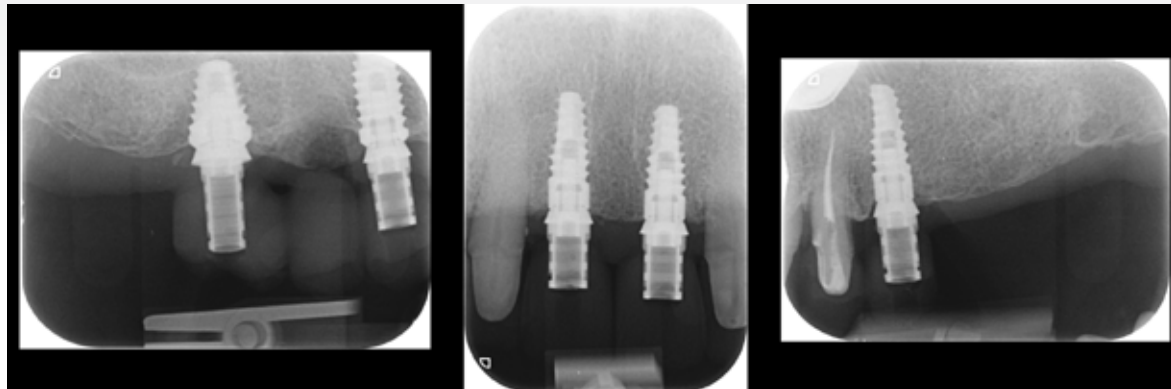


Figure 18: Periapical radiographs to verify the seat of the implant-retained provisional restorations.

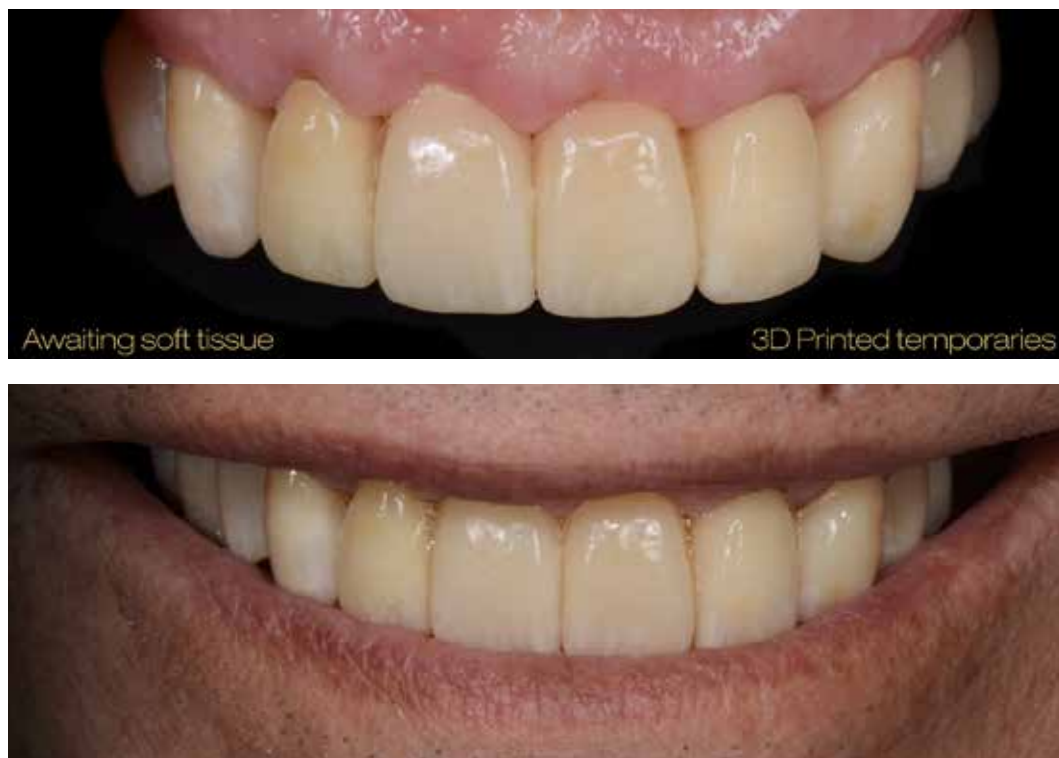

Figure 19: Immediate post-operative view of the inserted provisionals.

heal for a period of 3 months before the finalisation of the rehabilitation with the definitive restorations.

Conclusion

The case presented illustrates how advances in digital technologies can provide clinicians with the tools for diagnosis, treatment planning, the execution and provision

of dental restorative procedures in a truly transformative way.

Simplification of clinical protocols, increased accuracy over conventional analogue techniques and improved patient comfort and outcomes are compelling reasons of the benefits of a full digital workflow in the field of restorative and implant dentistry.

Reprinted with permission by GC get connected.