

Bonding of ceramic veneers

Olivier Étienne¹ and Bérangère Cournault²

In recent years, the use of aesthetic bonded ceramic restorations has been favoured because of the aesthetic demand of our patients as well as our profession's concern to promote minimally invasive procedures¹. Among these restorations, veneers are mostly associated to the aesthetic improvement of the smile and the techniques of tissue preservations².

The fragility and detachment of these fine pieces of ceramics remain the main sources of apprehension of practitioners despite excellent results reported in the many clinical studies published to date^{3,4}. Admittedly, a low rate of failure is still relevant, but the understanding of the phenomena and the clinical criteria influencing the result either positively or negatively enabled to systematise the entire procedure in a better way. Among the criteria reported as determinants, the respect of an exclusive enamel bonding is essential. Indeed, the enamel can be easily etched and its composition, mainly mineral, does not make adhesion difficult as hydrated dentine can do. Hence, when the bonding system is wisely selected, the ceramic-enamel bond can reach adhesion values greater than the natural dentinoenamel junction.

In order to preserve the enamel tissue of the vestibular surfaces, several authors have proposed clinical procedures based on the analysis and preliminary composed aesthetic treatment plan. The use of silicone keys to control the reduction⁵ to the transfer the treatment plan through a mock-up^{6,7} are approaches that limit the preparation to the bare minimum. Then, the respect of a strict bonding protocol ensures the durability of the final result.

Clinical evaluation and aesthetic project

The initial consultation enables to take note of the patient's wishes and to confront them with the clinical and radiographic criteria. The aesthetic therapeutic decision may depend on desires such as shape modification, colour alteration, restoration of a large caries or correction of malpositions. The clinical case described below relates to a patient with oligodontia and microdontia, eager to improve her smile and to overcome the lack of permanent posterior teeth. The initial analysis (Figure 1) shows a "childlike" appearance of the smile, characterised by small anterior upper teeth associated with the presence of several diastemas.

¹ Prof. Olivier Étienne is Assistant Professor and Head of the Prosthetics Unit of the Faculty of Dental Medicine in Strasbourg (France). He is Doctor of Odontological Sciences (PhD) and devotes his research to surface characteristics and their interaction with biological tissues.

² Dr. Bérangère Cournault is a dentistry student in the 6th year at the Faculty of Dental Medicine in Strasbourg (France).

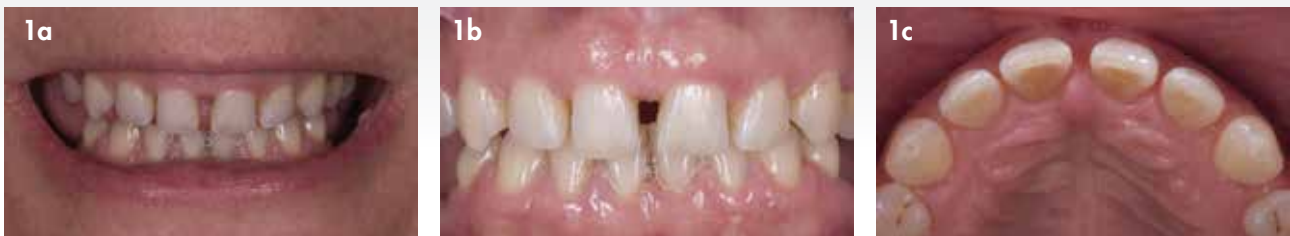

Figure 1: The 45-year-old patient presented with oligodontia and microdontia, characterised by the presence of many diastemas in the smile. The distribution of the teeth on the arch has been optimised by the previous orthodontic treatment which enables to envision the realisation of ceramic facets. Front view of the smile (a), intraoral view of the smile (b) and occlusal view (c).

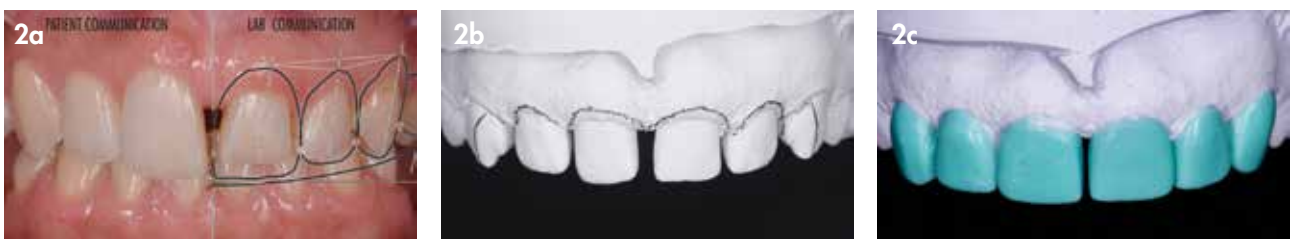

Fig. 2: (a) The aesthetic analysis associated with an aesthetic project (smile design) enables the efficient guidance of the dental technician towards the construction of the desired wax-up. (b) The future gingival contour was drawn on the plaster (c) Then, it was covered by the modeling wax.

The aesthetic treatment plan resulting from the preceding analysis must allow effective communication with the patient as well as the dental technician. We found the use of a virtual project from a Photoshop Smile Design (PSD) approach ideal to fulfil both the communication to the patient

and the technician (Fig. 2a). This way, the technician was able to carry out a preparatory wax-up (Fig. 2b, 2c), which was then transferred to the mouth through a mock-up of bis-acryl temporary resin. In this case, the PSD project made it possible to present the two treatment options to the patient:

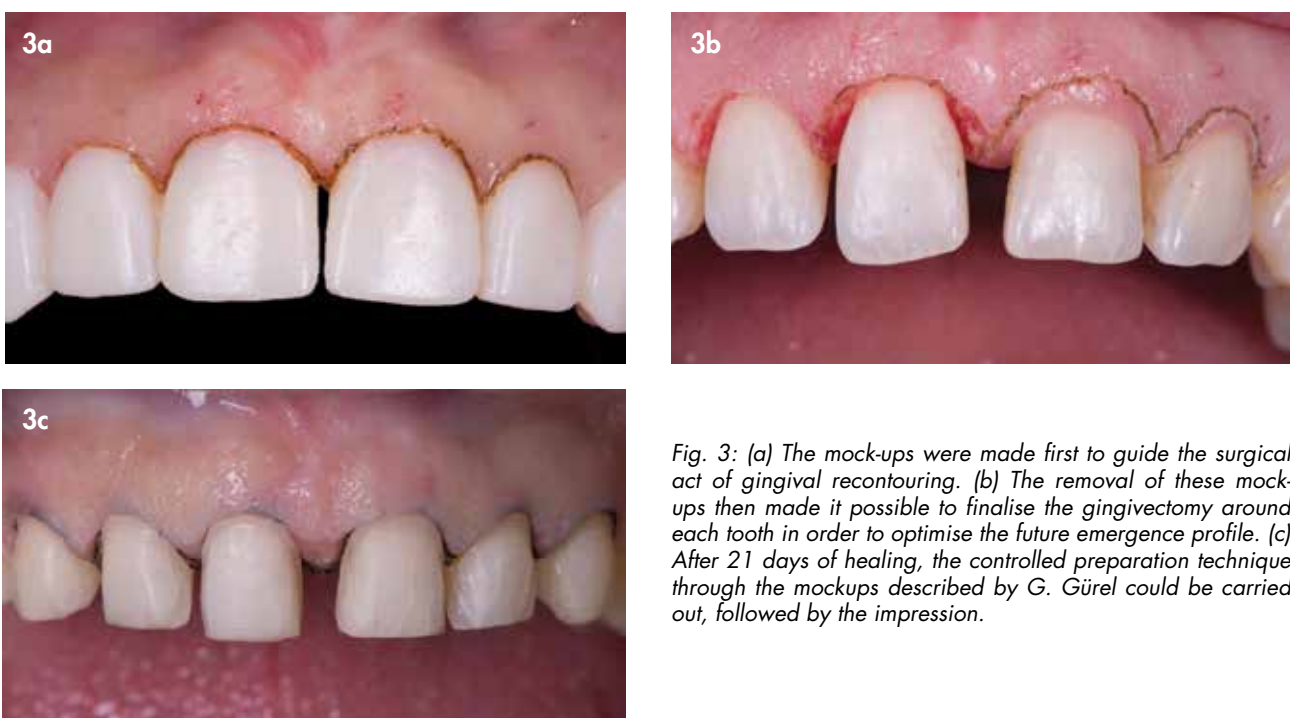


Fig. 3: (a) The mock-ups were made first to guide the surgical act of gingival recontouring. (b) The removal of these mock-ups then made it possible to finalise the gingivectomy around each tooth in order to optimise the future emergence profile. (c) After 21 days of healing, the controlled preparation technique through the mockups described by G. Gürel could be carried out, followed by the impression.

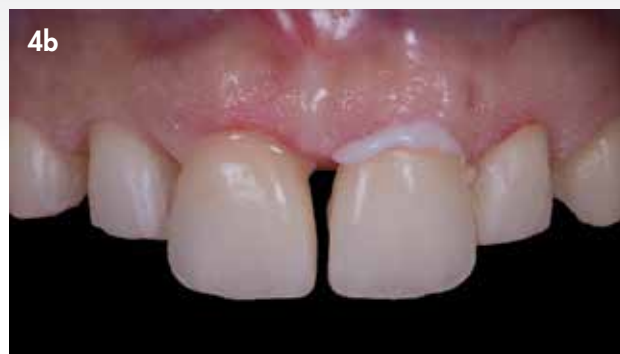
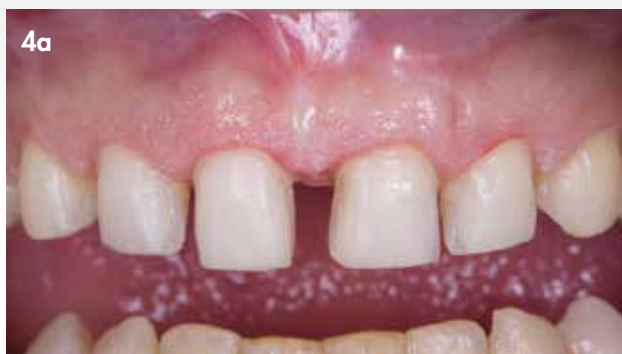
Fig. 4: (a) After removal of the provisional veneers, the dental surfaces were cleaned before trying all veneers with G-CEM Try-in Paste. When veneers are thin (<0.6mm), the colour of the bonding resin can influence the aesthetic result. (b) It is interesting to do several glycerine fitting trials to judge the final result. Here, 11 was tried with a try-in paste "A2" while 21 was tried with a try-in paste "Bleach". The brightness of 21 was preferred and therefore chosen.

partial preservation of the central diastema or complete closure of the diastema. Our common preference was to partially preserve the central diastema.

Enamel preparation

Once the mock-up was made, it served as a guide for the necessary gingivo-plasty (Fig. 3a, 3b). After gingival healing, the preparation could be started. The use of techniques to guide the preparation depth is essential. To do this, specific burs allow the practitioner to maintain enamel for the bonding, as long as a depth of 0.4 to 0.8 mm is respected. Horizontal, vertical and cervical depth marks were prepared on the buccal surface of the teeth, before starting the preparation.

The cervical limit was placed juxta-gingivally to facilitate the placement of the rubber dam during the luting later on. The proximal limits connected below the contact point to position the dento-restorative joint in a non-visible area, regardless of the angle of view. The contact point was

preserved at first and then faded by an abrasive matrix tape. Finally, the free edge was reduced when it was worn, altered or dyed.

The preparation was rounded and finished with a fine-grit bur (yellow coded), or even using sonic or ultrasonic instruments, to ensure a more reliable reproduction during the impression (Fig. 3c).

Try-in and luting

The aesthetic validation was done in the chair using the dedicated try-in pastes (G-CEM Try-In Pastes), allowing the practitioner to evaluate the possible impact of the colour of the cement on the final colour of the veneer (Fig. 4a, 4b). This criterium is particularly essential when the veneer is thin and/or made of feldspar ceramic without reinforcement⁸. When all the aesthetic criteria initially desired were respected, the restorations could be luted. Firstly, the intaglio surfaces of the glass ceramic veneers (reinforced lithium disilicate) were etched with hydrofluoric acid for 20 seconds, then rinsed

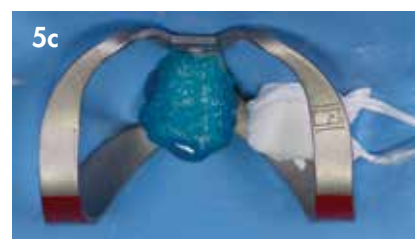
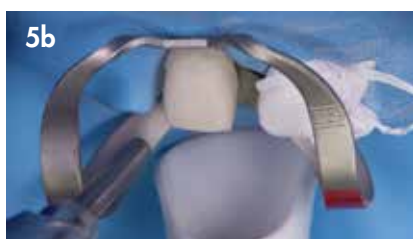

Fig. 5: (a) After rubber dam placement, the enamel of the prepared tooth was rinsed with water, to eliminate the water-soluble fitting paste. (b) Next it was sandblasted with alumina. (c) The surface was etched for 30 s with orthophosphoric acid, rinsed and dried.

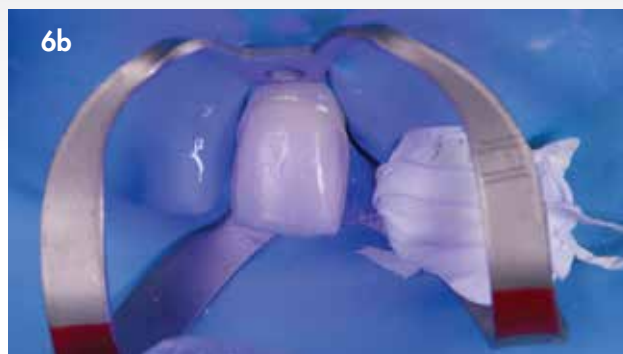
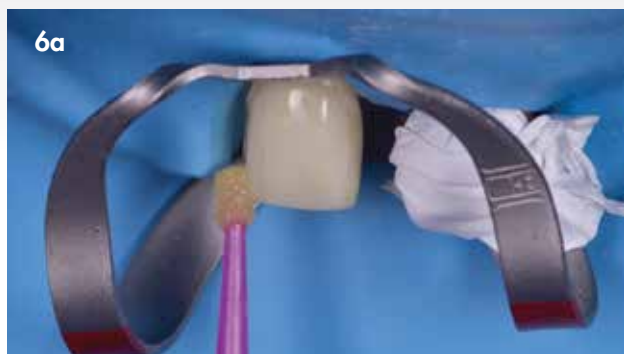


Fig. 6: (a) The universal adhesive G-Premio BOND was applied vigorously over the entire enamel surface, before being spread with oil-free air. (b) The adhesive was then immediately light-cured. Its low thickness (no more than 10 µm) does not pose any risk of difficulty to insert and seat the veneer.

and dried before being covered with a primer (G-Multi PRIMER) and left one minute minimum until evaporation.

The placement of a rubber dam guaranteed isolation from ambient humidity and sulcular fluid. The dam was supplemented by a Teflon tape which ensured the protection of neighbouring preparations on which the different products

could be deposited (Fig. 5a).

After rinsing the try-in paste away with water, an alumina micro-blasting guaranteed a cleaned surface and generated a macro-roughness, enhancing the adhesion (Fig. 5b).

The choice of the adhesive approach was based on scientific evidence concluding that the best adhesion values

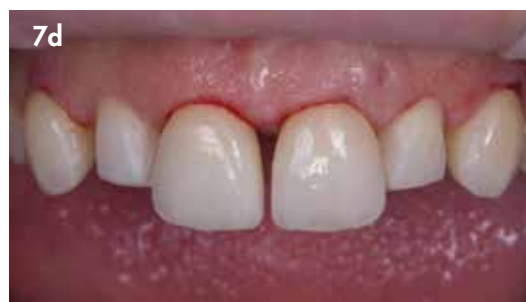
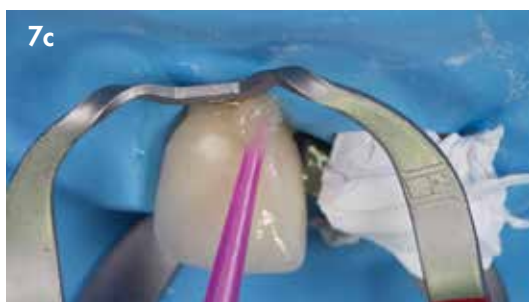
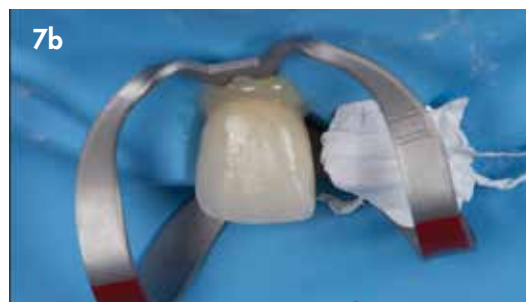Fig. 7: (a) Each veneer was pretreated with hydrofluoric acid (20 s) and rinsed and dried before applying a coat of G-Multi PRIMER. After one minute, the veneer was dried and then coated with G-CEM Veneer light-cure resin cement in the selected colour. (b) It was positioned on the preparation before (c) removing the resin excess by wiping. This option made it possible to obtain an adhesive joint without microleakage unlike the tack-cure technique. The veneer was firmly held onto the tooth during the entire light-curing procedure. (d) When the six anterior teeth are involved in the treatment, the recommended sequence is to bond first 11 and 21, then 13 and 23, ending with 12 and 22.

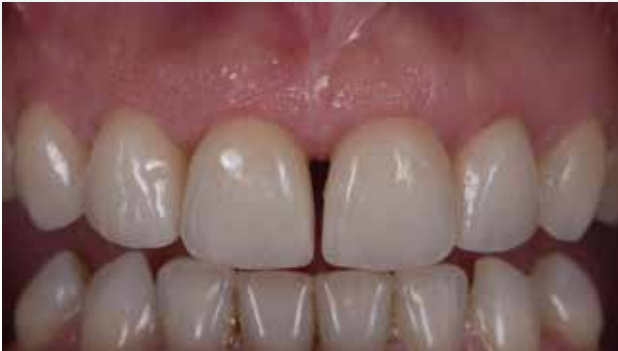

Fig. 8: After a week of healing, the periodontium refound its position. The redesigned gingival contours gave the illusion of a natural emergence profile.

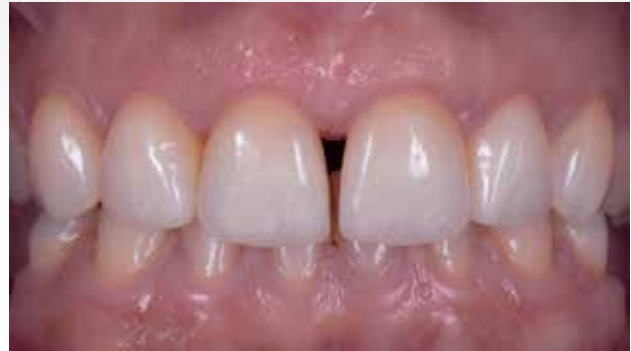

Fig. 9: Result after 6 months.

between enamel and ceramic are observed when the protocol includes enamel etching⁹ (Fig. 5c).

The adhesive was scrubbed vigorously onto the enamel surface (Fig. 6a) before being spread by a strong dry air blow as recommended by the manufacturer. This step also contributes to the evaporation of the solvents contained in the adhesive. Finally, immediate light-curing of the hybrid layer obtained at this stage is strongly recommended (Figure 6b).

References

1. Etienne O, Anckenmann L. Restaurations esthétiques en céramique collée. Paris: Editions CdP; 2016.
2. Etienne O. Facettes en céramique. Memento, editor. Paris: Ed. CdP; 2013.
3. Peumans M, De Munck J, Fieuws S, Lambrechts P, Vanherle G, Van Meerbeek B. A prospective ten-year clinical trial of porcelain veneers. The journal of adhesive dentistry. 2004;6(1):65-76.
4. Gurel G, Morimoto S, Calamita MA, Coachman C, Sesma N. Clinical performance of porcelain laminate veneers: outcomes of the aesthetic pre-evaluative temporary

(APT) technique. Int J Periodontics Restorative Dent. 2012;32(6):625-35.

5. Belser U, Magne P, Magne M. Ceramic laminate veneers: continuous evolution of indications. J Esthet Dent. 1997;9(4):197-207.

6. Magne P, Belser UC. Novel porcelain laminate preparation approach driven by a diagnostic mock-up. J Esthet Restor Dent. 2004;16(1):7-16; discussion 7-8.

7. Gurel G. Predictable, precise, and repeatable tooth preparation for porcelain laminate veneers. Pract Proced Aesthet Dent. 2003;15(1):17-24.

8. Vaz EC, Vaz MM, de Torres EM, de Souza JB, Barata TJE, Lopes LG. Resin Cement: Correspondence with Try-In Paste and Influence on the Immediate Final Color of Veneers. J Prosthodont. 2018.

9. De Munck J, Van Landuyt K, Peumans M, Poitevin A, Lambrechts P, Braem M, et al. A critical review of the durability of adhesion to tooth tissue: methods and results. Journal of dental research. 2005;84(2):118-32.

Reprinted with permission by GC get connected