

Minimally invasive veneers with hybrid ceramics

Andreas Kurbad¹

Aesthetic corrections with veneers should be minimally invasive and limited to the enamel and, despite the thin layer thickness in the mouth, develop a natural play of shade and light. The multichromatic CAD/CAM hybrid ceramic blank VITA Enamic MultiColor (VITA Zahnfabrik) has an integrated shade and translucency gradient with six finely graduated layers. The natural appearance of the tooth can be reconstructed almost at the touch of a button. Characterisation with stains can usually be omitted. The dual ceramic-polymer network structure of the hybrid ceramic allows narrow wall thicknesses of up to 0.2 millimeters, while remaining very edge-stable. These are the best conditions for restoring two upper middle incisors, as shown in this case report.

The aesthetic challenge

A 45-year-old female patient presented in the office and was dissatisfied with the aesthetic effect of her front teeth. The middle incisors had presumably lost incisal edge contour and length, due to abrasive and erosive processes. In addition, the anterior teeth were clearly discolored.

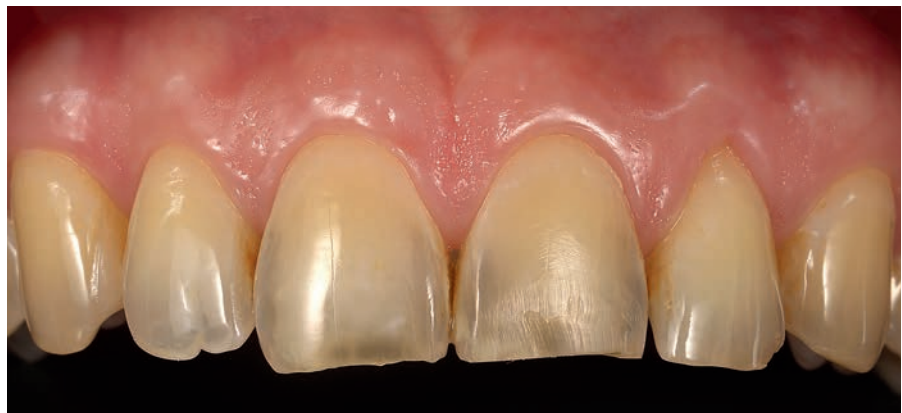

Figure 1: Initial situation: Erosion and abrasion led to a shortened incisor and the loss of the morphology of teeth UR1 and UL1.

¹ Dr Andreas Kurbad
Private practice focussing on cosmetic
dentistry and implantology, Viersen,
Germany.

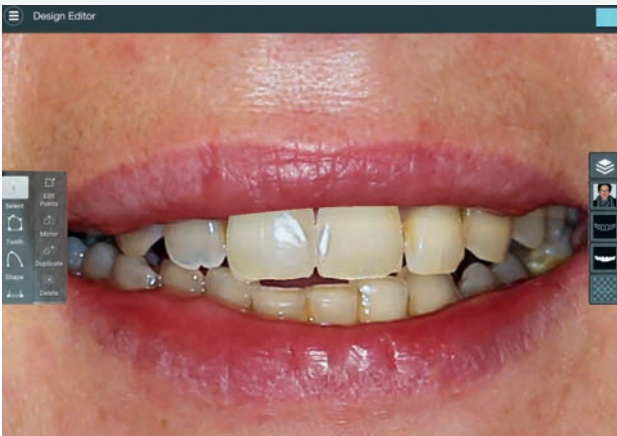


Figure 2: With the Smile Designer Pro software, ideal middle incisors were designed.

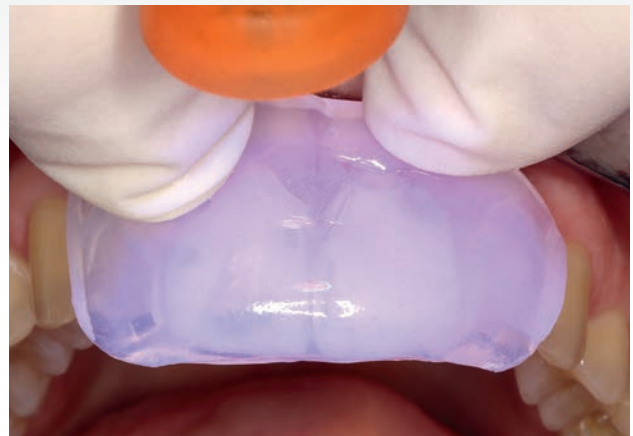

Figure 3: With a transparent silicone key and light-curing composite, the mock-up was fabricated intraorally.

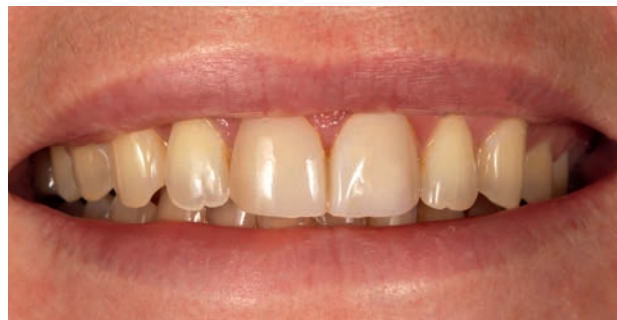

Figure 4: The mock-up corresponded to the aesthetic expectations of the patient.

The patient wished to restore a natural appearance to these teeth using minimallyinvasive therapy. For targeted therapy, the situation was scanned with the Cerec Omnicam, and photos were taken. The Smile Designer Pro software simulated the extension of the incisal edge and the recontouring of the morphology. On this basis, a clinical mock-up was created which satisfied all participants.

CAD/CAM-supported fabrication

The mock-up was scanned intraorally to be included in the virtual design in the CEREC software as a biogeneric copy. Due to the vestibular loss of substance on teeth UR1 and UL 1, the preparation was performed in a very minimally invasive manner with a micro chamfer, applied in the cervical area. The clinical situation was now rescanned so

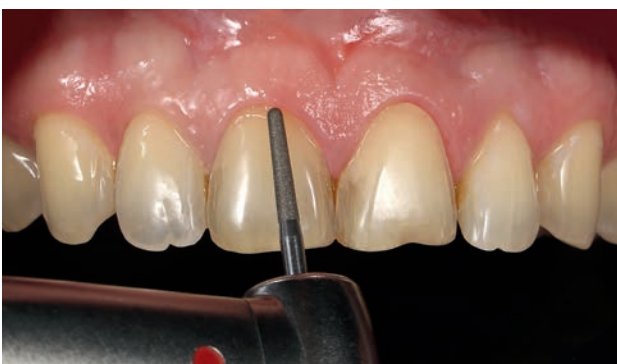

Figure 5: The minimally invasive preparation during the application of a micro chamfer in the cervical area.

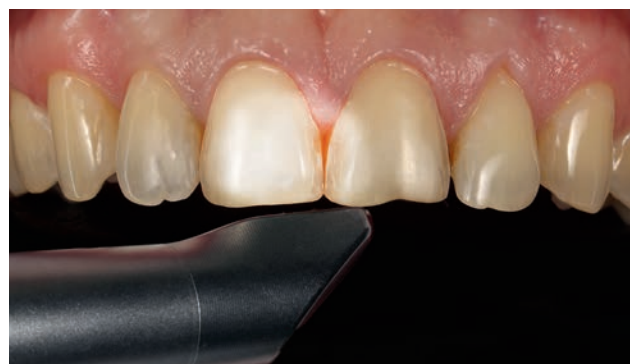

Figure 6: The clinical situation was scanned with the Cerec Omnicam.

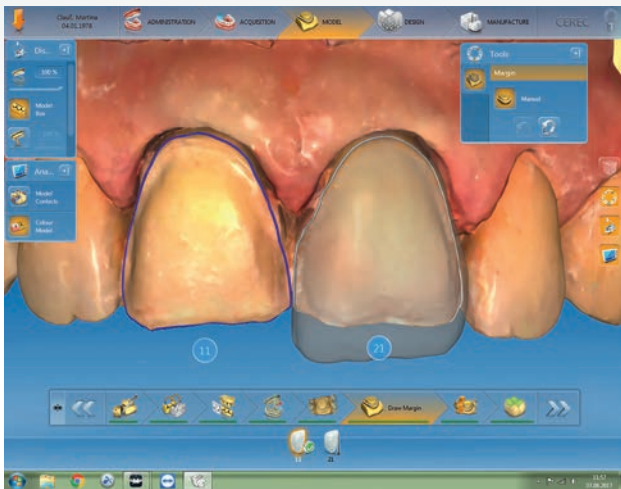

Figure 7: The design of the hybrid ceramic veneer in the Cerec software.

that the virtual construction of the veneers and their CAD/CAM-based fabrication could take place. When working with rotating diamond tools, the focus was mainly on the surface texture. Finally, the veneers were polished to a high gloss and were incorporated in the same session.

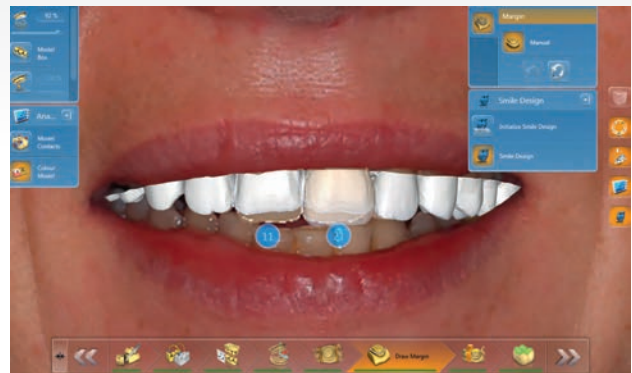

Figure 8: With the Cerec Smile Design Application, the restorations can be evaluated together with the lips.

Seating and final results

After clinical try-in, the two restorations were fully adhesively incorporated. The dominant feldspar ceramic network (86 wt%) of the hybrid ceramic veneer was etched in a proven manner with hydrofluoric acid and




Figure 9: The sheer veneers made of VITA Enamic MultiColor immediately after grinding out.

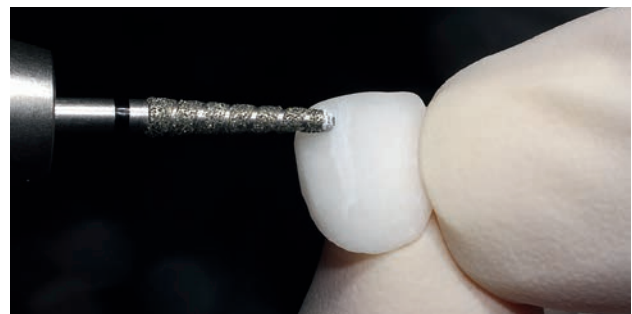


Figure 10: The incorporation of texture and morphology with the rotating diamond tool.

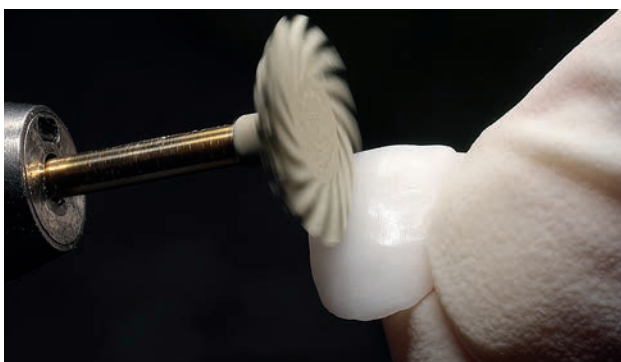

Figure 11: A simple high-gloss polish was enough to finish the restorations.

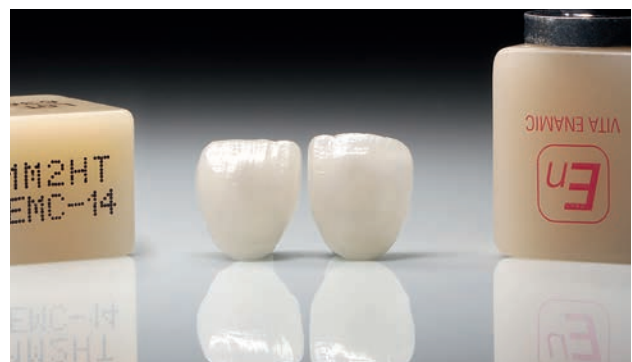

Figure 12: The finished veneers just before the clinical try-in.

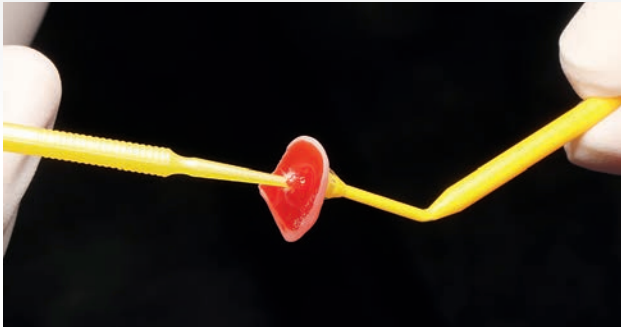


Figure 13: Conditioning with hydrofluoric acid creates a micro-retentive surface.

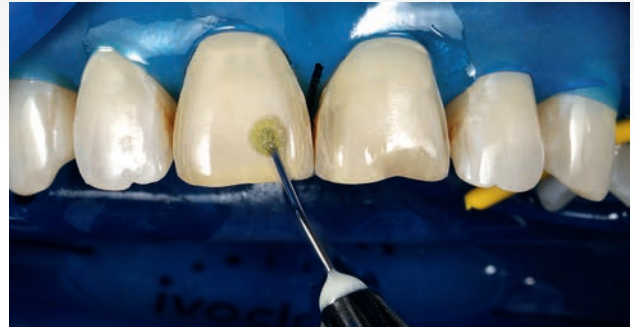

Figure 14: A light-curing one-component adhesive was applied to the tooth surfaces.

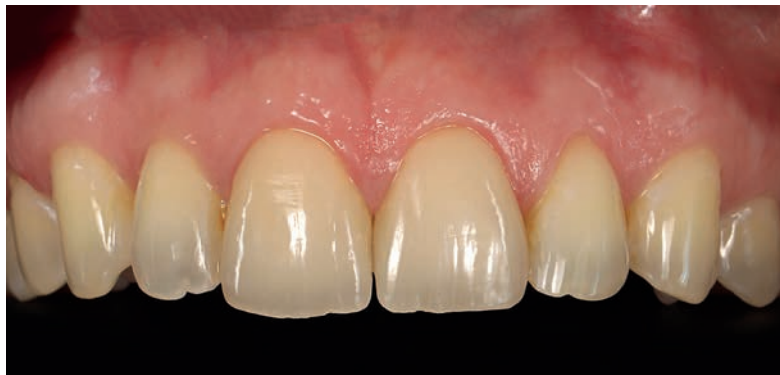

Figure 15: Both veneers integrated completely and naturally into the aesthetic zone.

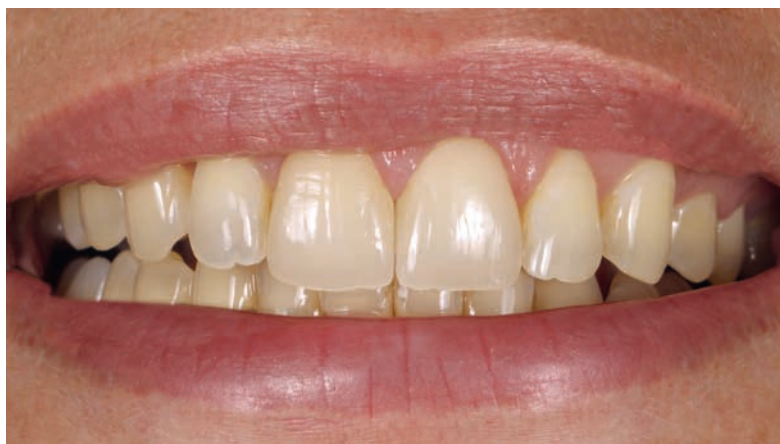

Figure 16: Result: The curve of the incisal edges harmonised with the curve of the lips.

then silanised. The conditioning of the enamel was carried out with phosphoric acid and a light-curing single-component adhesive. After incorporation with a shade-matched composite cement, the hybrid ceramic veneers fit harmoniously into the aesthetic zone. Thanks to the rapid production without any crystallisation or sintering

firing and the integrated shade gradient, the two central incisors could be efficiently and aesthetically restored. The patient was highly satisfied with the minimally invasive and fast result.

Reprinted with permission by Private Dentistry.