

# Pulp revascularisation in a traumatised and necrotic tooth

Ricardo Machado,<sup>1</sup> Gustavo Almeida,<sup>2</sup> Thâmara Silva Santos,<sup>3</sup> Brunna Presmini Barbosa,<sup>4</sup> Guilherme Augusto Moreira<sup>5</sup> and Alberto Porto Junior<sup>6</sup>

The greatest difficulties in carrying out root canal treatments in teeth with pulp necrosis and incomplete root formation lie in the limited efficiency of transoperative cleaning and in the great possibility of overfilling. This is mainly due to the divergence in the root canal walls and lack of apical constriction (Thomson, Kahler, 2010; Forghani, Parisay, Maghsoudlou, 2013).

Successive changes of intracanal dressings using calcium hydroxide pastes are performed to reduce the difficulties imposed by treating teeth with pulp necrosis and incomplete root formation, by boosting disinfection and inducing apexification (Silveira et al, 2015). However, the major disadvantage of this therapeutic strategy is that the procedure implies a long treatment period; hence, there is a real possibility of fracture and reinfection (Cvek, 1992; Andreasen, Farik, Munksgaard, 2002; Rosemberg, Murray, Namerow, 2007; Hawkins, Torabinejad, Retamozo, 2015; Valera et al, 2015).

Mineral trioxide aggregate has been suggested as an alternative, to eliminate long treatment periods (Pradhan et al, 2006; Raju, Yadav, Kumar, 2014; Badole et al, 2015). However, both calcium hydroxide pastes and mineral trioxide aggregate are normally used only to induce apexification. Neither is able to effectively induce root formation and termination of dentine deposition on the side walls of the root canal (Valera et al, 2015; Pradhan et al, 2006; Raju, Yadav, Kumar, 2014; Badole et al, 2015; Bose, Nummikoski, Hargreaves, 2009). Consequently, there has been a steady search for new alternatives.

Pulp revascularisation is a process by which the root canals of necrotic teeth with incomplete root formation are mostly disinfected using copious irrigation with an antibacterial solution and application of a combination of antibiotics, such as ciprofloxacin, metronidazole, minocycline, and amoxicillin (Hoshino et al, 1996; Sato et al, 1996; Kahler et al, 2014), or calcium hydroxide pastes (Soares Ade et al, 2013; Nagata et al, 2014). In another visit, intracanal bleeding is stimulated to produce a blood clot to act as a matrix for the restoration of the vascular nerve bundle. Cervical sealing is then performed (Iwaya, Ikawa, Kubota, 2001; Banchs, Trope, 2004; Chueh, Huang, 2006; Lovelave et al, 2011).

This article presents a case where pulp revascularisation was opted for instead of inducing apexification, after a trauma in the upper right lateral incisor. The 12-month follow-up evidences the success of the treatment performed.

## Case report

A 10-year-old male patient was seen at the Endodontics Specialization Course of the Brazilian Dental Association, Brazil, accompanied by his caregiver. The patient reported that he had suffered a dental injury in the anterior maxillary region about two years prior, but had only begun to feel pain, swelling and fistula in the region a few weeks before the visit. No relevant systemic diseases were reported. The clinical examination included palpation exams, tooth mobility analysis, cold thermal tests (Endo Ice, Hygenic, Akron) and periodontal probing in the incisors and canines of the region. All of these examinations and tests were within normal limits, except for the upper right lateral incisor, which did not respond to thermal tests and showed grade II mobility.

<sup>1</sup> Ricardo Machado is professor of multidisciplinary clinic I and II (endodontics) and supervised stage in multidisciplinary clinic I (endodontics) at the School of Dentistry, Paranaense University – UNIPAR, Francisco Beltrão, Paraná, Brazil.

<sup>2</sup> Gustavo Almeida is professor of endodontics at the Brazilian Dental Association – ABO, Ilhéus, Bahia, Brazil.

<sup>3</sup> Thâmara Silva Santos is specialist in endodontics at the Brazilian Dental Association – ABO, Ilhéus, Bahia, Brazil.

<sup>4</sup> Brunna Presmini Barbosa is an undergraduate student at the School of Dentistry, Paranaense University – UNIPAR, Francisco Beltrão, Paraná, Brazil.

<sup>5</sup> Guilherme Augusto Moreira is an undergraduate student at the School of Dentistry, Paranaense University – UNIPAR, Francisco Beltrão, Paraná, Brazil.

<sup>6</sup> Alberto Porto Junior is professor of endodontics at the Brazilian Dental Association – ABO, Ilhéus, Bahia, Brazil.

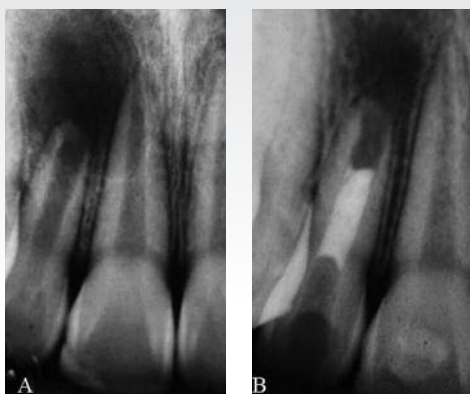


Figure 1a: Initial radiograph.

Figure 1b: MTA used as cervical barrier and GIC used as a temporary restorative material.

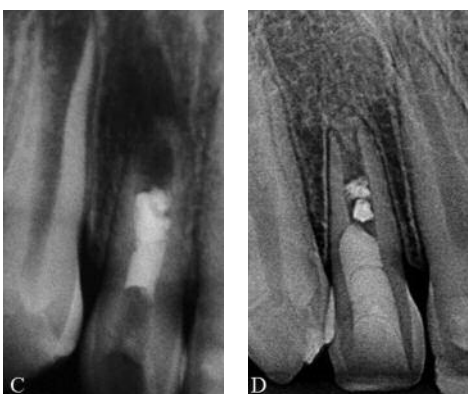

Figure 1c: Five-month follow-up.

Figure 1d: One-year follow-up radiograph showing total healing and considerable absorption of mineral trioxide aggregate.

Radiographic examination revealed the presence of apical periodontitis in the upper right lateral incisor, as well as incomplete root formation (Figure 1a). The diagnosis of chronic periapical abscess was made by associating the information obtained from the clinical and radiographic examinations.

In the first appointment, it was decided that only semi-rigid splinting would be performed to stabilise dental mobility. Patient contact was lost, and the splinting was removed only two months later.

In the second appointment, endodontic access was performed after anaesthesia (2% lidocaine and epinephrine 1:80.000) and placement of the rubber dam, using 1016HL and 3083 drills (Dentsply Maillefer). Only one canal orifice was located. The working length was determined by means of an electronic foramen locator (Elements Apex Locator, Sybronendo) and instrumentation was performed according to the crown down technique, using K-files from the third series (Dentsply Maillefer). Irrigation was performed using 2% chlorhexidine gel and 2.5ml of saline solution (Fórmula & Ação) at each change of files. Then, antibiotic paste consisting of ciprofloxacin (200mg) and metronidazole (500mg) was placed. A microhybrid composite resin (Z100, 3M Espe) was used as a temporary sealing material.

Twenty-nine days later, after anaesthesia (2% lidocaine and epinephrine 1:80.000) and placement of the rubber dam, the microhybrid composite resin used as a temporary sealing

material and the antibiotic paste were removed with a 1016HL drill (Dentsply Maillefer) and profuse irrigation was performed with saline solution and 2% chlorhexidine gel (Fórmula & Ação), respectively. The canal was dried with paper points (Tanari) and bleeding was stimulated with a 30 k-file (Dentsply Maillefer), eventually stabilising the clot at 3mm below the cemento-enamel junction. Mineral trioxide aggregate (Angelus) was used as cervical barrier. A glass ionomer cement (Ketac-Fil, 3M Espe) was used as a temporary restorative material (Figure 1b). The patient was then referred back to his clinician to perform the definitive restoration.

After a five-month follow-up, mobility and response to palpation and percussion tests were normal. Stabilisation of the periradicular disease was confirmed (Figure 1c), and the patient no longer showed any symptoms. However, the treated tooth still showed no sensitivity to thermal tests. After 12 months, a radiographic exam showed a considerable thickening of the root side walls, completion of the root formation and total healing of the periradicular disease. A considerable absorption of mineral trioxide aggregate was also observed, suggesting the occupation of root canal space by pulp tissue and dentine deposition (Figure 1d). The tooth responded normally to cold sensitivity tests, indicating the success of the treatment performed.

## Discussion

Until recently, apexification has been the only alternative to maintain teeth with pulp necrosis and incomplete root formation. However, the major drawback of this therapeutic strategy is that the procedure requires a long treatment period with successive changes of dressings of calcium hydroxide pastes; hence, there is a real possibility of fracture and reinfection (Cvek, 1992; Andreasen, Farik, Munksgaard, 2002; Rosemberg, Murray, Namerow, 2007; Hawkins, Toabinejad, Retamozo, 2015; Valera et al, 2015). For this reason, mineral trioxide aggregate was suggested as an alternative to eliminate long treatment periods (Pradhan et al, 2006; Raju, Yadav, Kumar, 2014; Badole et al, 2015). However, neither treatment strategy is able to effectively induce radicular dentine formation and dentine deposition on the side walls of the root canal (Bose, Nummikoski, Hargreaves, 2009).

The main objectives of pulp revascularisation are to reestablish the vascular nerve bundle and complete the root formation process (Forghani, Parisay, Maghsoudlou, 2013; Saoud et al, 2014). Consequently, the respective clinical actions are considerably different from those of apexification.

In the present case, chlorhexidine was used as an auxiliary chemical solution, because of its lower toxicity, compared with sodium hypochlorite (Gomes-Filho et al, 2008), considering the real possibility of extravasation of the irrigation solutions during treatment, due to lack of apical constriction. Recently published research has also used similar protocols (Soares Ade et al, 2013; Nagata et al, 2014).

The use of calcium hydroxide (Soares Ade et al, 2013;

Nagata et al, 2014) and/or antibiotic pastes (Hoshino et al, 1996; Sato et al, 1996; Kahler et al, 2014) for pulp revascularisation is critical in cases of necrotic teeth with incomplete root formation. These pastes are responsible for the disinfection process, considering that conventional cleaning and shaping cannot be performed, owing to the anatomic features of these teeth. However, previous studies have demonstrated the incidence of severe colour changes after using minocycline (Kahler et al, 2014). Therefore, ciprofloxacin and metronidazole were the medications of choice for the present case.

The absence of pain symptoms, the disappearance of possible fistula, the continuation of root development and the restoration of sensitivity to thermal change are the key success factors associated with pulp revascularisation (Kahler et al, 2014). All of these characteristics were confirmed in the case presented here, highlighted by complete root development after 12 months. Iwaya et al (2001) and Banchs and Trope (2004) reported clinical cases of pulp revascularisation, where complete apical closure occurred only after 30 and 24 months, respectively. Studies in different medical fields have shown that individuals can respond differently to similar interventions, and that these responses are strongly influenced by their systemic and immune conditions (Cooke et al, 2004; Kosalaraksa et al, 2011). This could have been a crucial factor for the quicker completion of the root formation in the case presented, in comparison with the cases mentioned above.

The case presented in this article confirms that pulp revascularisation is a viable alternative for the treatment of teeth with pulp necrosis and incomplete root formation. However, considering the principles guiding evidence-based dentistry, more longitudinal clinical studies, especially of a prospective nature, are needed to prove its effectiveness.

## Conclusions

The purpose of this article was to report a pulp revascularisation success story in a tooth with pulp necrosis and incomplete root formation. This procedure appears to be a promising alternative to deal with this clinical situation. However, more research is needed to prove its effectiveness.

## References

Andreasen JO, Farik B, Munksgaard EC (2002) Long-term calcium hydroxide as a root canal dressing may increase risk of root fracture. *Dent Traumatol* 18: 134-7

Badole GP, Warhadpande MM, Bahadure RN, Badole SG (2015) Nonsurgical endodontic treatment of permanent maxillary incisors with immature apex and a large periapical lesion: a case report. *Gen Dent* 63: 58-60

Banchs F, Trope M (2004) Revascularization of immature permanent teeth with apical periodontitis: new treatment protocol? *J Endod* 30: 196-200

Bose R, Nummikoski P, Hargreaves K (2009) A retrospective evaluation of radiographic outcomes in immature teeth with necrotic root canal systems treated with regenerative endodontic procedures. *J Endod* 35: 1343-9

Chueh LH, Huang GTJ (2006) Immature teeth with periradicular periodontitis or abscess undergoing apexogenesis: a paradigm shift. *J Endod* 32: 1205-8

Cooke A, Zaccane P, Raine T, Phillips JM, Dunne DVV (2004) Infection and autoimmunity: are we winning the war, only to lose the peace? *Trends Parasitol* 20: 316-21

Cvek M (1992) Prognosis of luxated non-vital maxillary incisors treated with calcium hydroxide and filled with gutta-percha: a retrospective clinical study. *Endod Dent Traumat* 8: 45-55

Forghani M, Parisay I, Maghsoudlou A (2013) Apexogenesis and revascularization treatment procedures for two traumatized immature permanent maxillary incisors: a case report. *Restor Dent Endod* 38: 178-91

Gomes-Filho JE, Aurélio KJ, Costa MM, Bernabé PF (2008) Comparison of the biocompatibility of different root canal irrigants. *J Appl Oral Sci* 16: 137-44

Hawkins JJ, Torabinejad M, Retamozo B (2015) Effect of three calcium hydroxide formulations on fracture resistance of dentin over time. *Dent Traumatol* 31: 380-4

Hoshino E, Kurihara-Ando N, Sato I, Uematsu H, Sato M, Kota K, Iwaku M (1996) In-vitro antibacterial susceptibility of bacteria taken from infected root dentine to a mixture of ciprofloxacin, metronidazole and minocycline. *Int Endod J* 29: 125-30

Iwaya SI, Ikawa M, Kubota M (2001) Revascularization of an immature permanent tooth with apical periodontitis and sinus tract. *Dent Traumatol* 17: 185-7

Kahler B, Mistry S, Maule A, Ringsmuth AK, Case P, Thomson A, Holcombe T (2014) Revascularization outcomes: a prospective analysis of 16 consecutive cases. *J Endod* 40: 333-8

Kosalaraksa P, Srirompotong U, Newman RW, Lumbiganon P, Wood JM (2011) Serological response to trivalent inactivated influenza vaccine in HIV-infected children with different immunologic status. *Vaccine* 29: 3055-60

Lovelace TW, Henry MA, Hargreaves KM, Diogenes A (2011) Evaluation of the delivery of mesenchymal stem cells into the root canal space of necrotic immature teeth after clinical regenerative endodontic procedure. *J Endod* 37: 133-8

Nagata JY, Gomes BP, Rocha Lima TF, Murakami LS, de Faria DE, Campos GR, de Souza-Filho FJ, Soares Ade J (2014) Traumatized immature teeth treated with 2 protocols of pulp revascularization. *J Endod* 40: 606-12

Pradhan DP, Chawla HS, Gauba K, Goyal A (2006) Comparative evaluation of endodontic management of teeth with unformed apices with mineral trioxide aggregate and calcium hydroxide. *J Dent Child* 73: 79-85

Raju SM, Yadav SS, Kumar SRM (2014) Revascularization of immature mandibular premolar with pulpal necrosis - a case report. *J Clin Diagn Res* 8: 29-31

Rosemberg B, Murray PE, Namerow K (2007) The effect of calcium hydroxide root filling on dentin fracture strength. *Dent Traumatol* 23: 26-9

Saoud TM, Zaazou A, Nabil A, Moussa S, Lin LM, Gibbs JL (2014) Clinical and radiographic outcomes of traumatized immature permanent necrotic teeth after revascularization/revitalization therapy. *J Endod* 40: 1946-52

Sato I, Ando-Kurihara N, Kota K, Iwaku M, Hoshino E (1996) Sterilization of infected root-canal dentine by topical application of a mixture of ciprofloxacin, metronidazole and minocycline in situ. *Int Endod J* 29: 118-24

Silveira CM, Sebrão CC, Vilanova LS, Sánchez-Ayala A (2015) Apexification of an immature permanent incisor with the use of calcium hydroxide: 16-year follow-up of a case. *Case Rep Dent* 1-6

Soares Ade J, Lins FF, Nagata JY, Gomes BP, Zaia AA, Ferraz CC, de Almeida JF, de Souza-Filho FJ (2013) Pulp revascularization after root canal decontamination with calcium hydroxide and 2% chlorhexidine gel. *J Endod* 39: 417-20

Thomson A, Kahler B (2010) Regenerative endodontics-biologically-based treatment for immature permanent teeth: a case report and review of the literature. *Aust Dent J* 55: 446-52

Valera MC, Albuquerque MT, Yamasaki MC, Vassallo FN, da Silva DA, Nagata JY (2015) Fracture resistance of weakened bovine teeth after long-term use of calcium hydroxide. *Dent Traumatol* 31: 385-9

*Reprinted with permission by ENDODONTIC PRACTICE December 2016*