

From digital planning to the mock-up and final restoration

Cyril Gaillard¹ and Jérôme Bellamy²

Presentation of a modern work concept on the basis of a veneer fabrication
A report by Cyril Gaillard and Jérôme Bellamy, Bordeaux/France

“Never promise what you can’t deliver!” Particularly when undergoing esthetically motivated dental treatment, patients should be given a realistic visualization of the final outcome to avoid raising undue expectations.

The demand for cosmetic treatments is also increasing in dental practices. Today’s communication media provide patients with virtually limitless access to a wealth of information on this topic. And with it comes an increase in expectations. This can pose a conundrum to the dentist: patients want to be promised the desired results yet they should not be given undue expectations in the run-up to the treatment.

The challenge

One of the challenges in day-to-day dentistry is the fact that the mock-up presented to the patient is produced from a wax-up and is often not consistent with the final outcome of the treatment (e.g. ceramic veneers). Several research studies have been initiated to overcome this problem. The SKYN concept is a result of this research.

The solution

The SKYN concept is based on a unique approach: it uses natural tooth shapes to create a mock-up directly in the patient’s mouth. A wax-up is created on the basis of tooth shapes that reflect the anatomy and morphology of natural teeth in terms of height, width, curvature and surface texture.

The predictability of the result is ensured by using CAD/ CAM technology to scan the mock-up, make adjustments in the oral cavity and then mill the veneers to achieve lifelike results. The reproducibility of the mock-up and the accuracy of the result arise, among others, from the performance of the CAD/ CAM system, allowing the expectations of the patient to be met both promptly and effectively.

¹ Cyril Gaillard
Bordeaux/France

² Jérôme Bellamy
Bordeaux/France

Contact

14 Rue Montesquieu
33000 Bordeaux
France
contact@cyrilgaillard.com

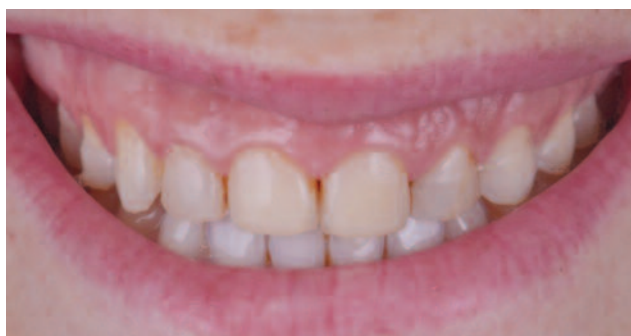

Figure 1: Preoperative situation. Severely stained restorations in the upper anterior region. It does not bother the patient that her upper lip is asymmetrical and her gum line is visible when she laughs.

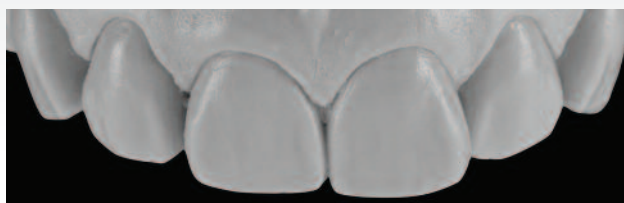


Figure 2: SKYN models (according to Dr Jan Hajt6) for the fabrication of the wax-up

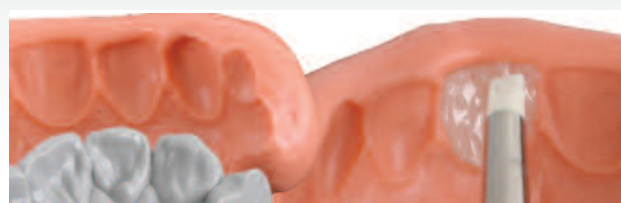

Figure 3: The composite (IPS Empress Direct) is applied into the silicone key.

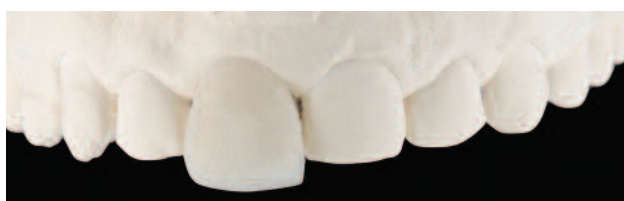

Figure 4a and b: The composite veneers created with the help of the silicone key show a natural shape and surface texture on the model.

CAD/CAM technologies have brought about a revolution in dentistry. They enable the efficient manufacture of customized ceramic veneers with high accuracy and within a short period of time. Furthermore, the restorations present an accurate copy of the esthetic wax-up. The different working steps involved in the SKYN concept are demonstrated below on the basis of a clinical case.

Clinical case

Preoperative situation

The patient visited the practice with a request that mainly concerned esthetic criteria. She felt that her anterior restorations looked too yellowish and their shape did not fit in. The restorations had been in her mouth for several years. They should now be replaced.

First, a series of digital pictures was taken to examine the situation more closely. The patient had a high smile line. However, the fact that her gums were visible when she smiled and her upper lip was asymmetrical did not bother her (Figs 1a and b). The periodontal apparatus was healthy. The soft tissues did not show any signs of abnormalities either.

Treatment planning

We recommended the patient to have the anterior region restored with veneers stretching from teeth 15 to 25 and advised her to have the premolars included in the restoration to achieve a harmonious appearance. The patient agreed with our proposal. We drew up the following treatment plan:

- Wax-up using composite veneers to reproduce the natural shape and texture of the teeth
- Mock-up according to the SKYN concept using a light-curing nanohybrid composite (IPS Empress® Direct)
- Intraoral digital data scan of the mock-up
- Preparation of the teeth with the help of the mock-up
- Digital impression of the preparation using an optical camera
- Fabrication of the temporaries
- Machining of the glass-ceramic veneers (IPS Empress CAD)
- Incorporation of the veneers

Fabricating the wax-up

The aim of the ceramic veneers was to give more volume to the teeth. The teeth should appear stronger and longer. Adjusting the dental proportions was requisite to creating a harmonious appearance between the teeth and the smile on the patient's face. To create the wax-up, we used the SKYN models ("Anterior Model Set" by Dr Jan Hajt6) as reference (Fig. 2). This is a reproduction of natural teeth. Upon request by the patient, tooth selection was performed with the help of both the DSD program (Digital Smile Design) and the VisagiSMile design and visualization software.

Transfer to the mock-up

We created a silicone key of the vestibular surfaces with the help of the wax-up and applied a thin layer of composite

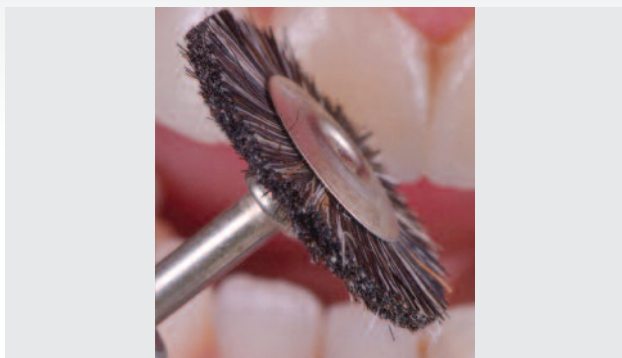


Figure 5: The mock-up is placed in the mouth. The surfaces are being reworked slightly.

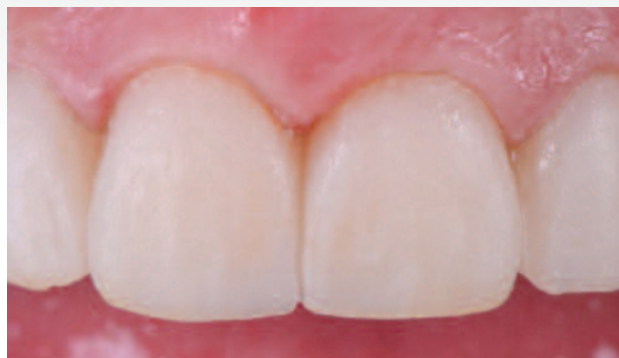

Figure 6: Completed mock-up. Photos and videos are used to assess it.

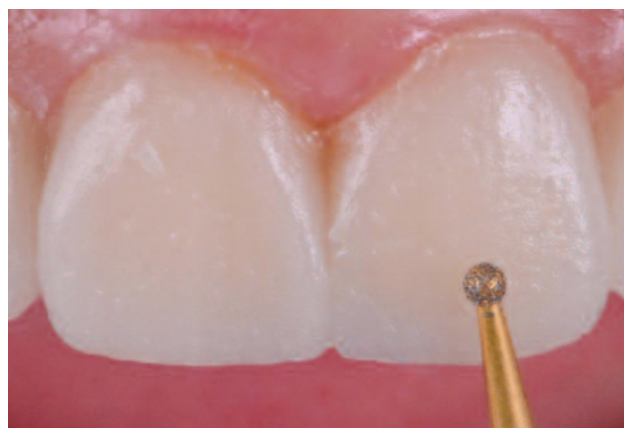
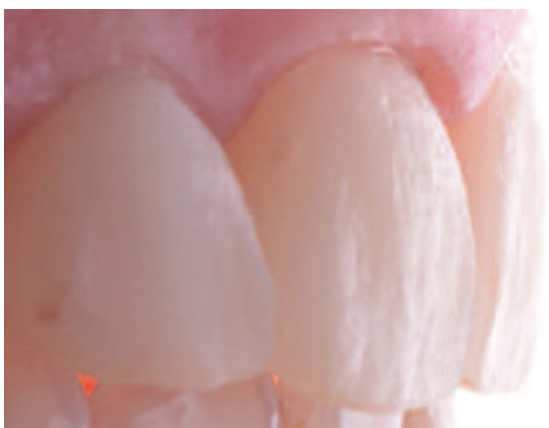
Figure 7a and b: The surfaces of the mock-up are being reworked slightly.

material into the key using a spatula (IPS Empress Direct) (Fig. 3). Once light cured (Bluephase® with Polywave® LED), the resulting composite veneers for teeth 15 to 25 were placed on the model and stabilized with wax (Fig. 4). Once the wax-up was finalized, it was duplicated and cast in stone.

We created a silicone key from this model to assist the dentist in the preparation of the teeth. The silicone key was created in two steps using two different silicone materials, one with a high hardness (Silico Dur, Cendres+Métaux) and the other with a low hardness (3M ESPE Express). The silicone key served to create the mock-up and the temporaries.

Tooth preparation and data transfer to the lab

The mock-up was inserted with the help of the silicone key and the surface texture was reworked using a polishing

system (Astropol®) (Fig. 5). The esthetic effect was validated with photographs and videos. The patient could also inspect the pictures (Figs 6 and 7). Then, the teeth were prepared using a ball-shaped bur whilst the mock-up was in place (Galip Gurel 2003) (Fig. 8). This procedure meets the requirements of minimally invasive dentistry. An impression of the prepared teeth (Fig. 9) was taken using an intraoral scanner and the temporaries were fabricated with the help of the silicone key.

At this point, the dentist is required to take two optical impressions: first, an impression of the prepared teeth and, second, an impression of the temporaries in the mouth. In addition, a conventional silicone impression of the prepared teeth is taken. The dental technician will use this impression to produce a physical model to check the fit and contact points of the milled ceramic veneers.

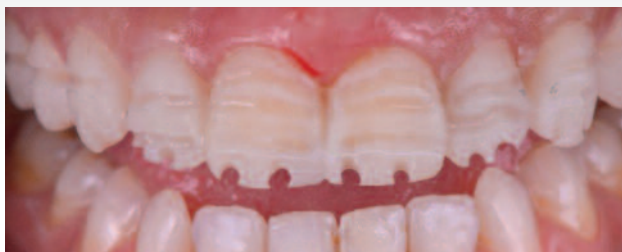

Figure 8: Targeted preparation of the teeth with the mock-up in place.

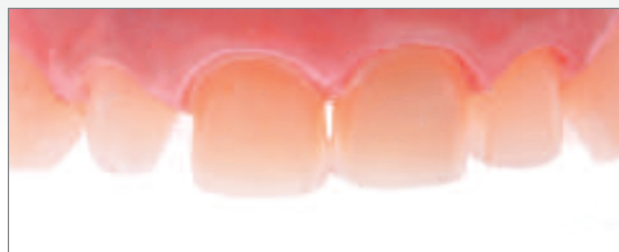

Figure 9: Close-up of the prepared anterior teeth.

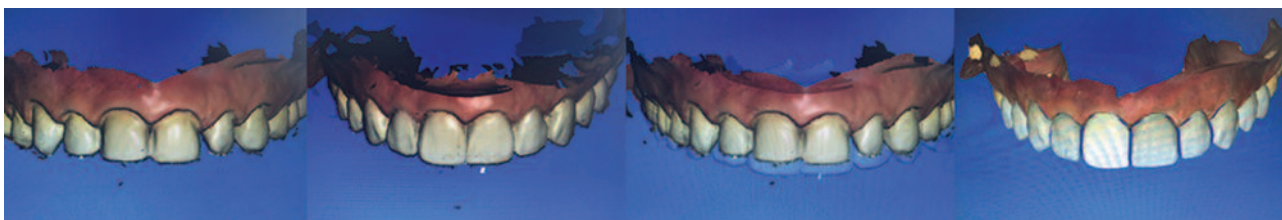


Figure 10: The CAD data of the digital impressions of the prepared teeth and the mock-up are superimposed.

Creating the final restoration

For the CAD construction, the two data sets (temporaries, prepared teeth) were superimposed in the software (Fig. 10). Subsequently, the shape of the temporaries was matched to the preparation margins. Each component was examined (preparation margin, thickness, contact points, etc.) separately before the data was transmitted to the milling unit for machining (Fig. 11). For the fabrication of the veneers, we decided to use the IPS Empress CAD Multi blocks, which feature a lifelike shade transition from the dentin to the incisal. We selected a block in shade A1. Each veneer was positioned in the block in such a way that the translucency of the incisal area matched our requirement. Once the veneers were milled, we checked their fit on the prepared dies of the model and assessed their contact points with each other. The surface texture was lightly reworked (Fig. 12). To achieve a highly esthetic result, we additionally characterized the veneers with Stains and Essence materials (IPS Ivocolor®) before we glaze-fired them (Fig. 11).

Seating the ceramic veneers

At the try-in, the shade and fit were checked. All ten veneers showed an excellent fit in the mouth. The next step was adhesive bonding. Prior to the bonding procedure, a rubber dam was placed to isolate the treatment field and keep it dry. As the natural teeth were not discoloured, we were able to use a translucent luting composite (Variolink® Esthetic) to insert the veneers (Fig. 13). The veneers were seated using

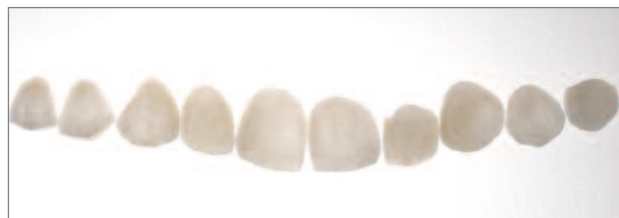

Figure 11: Veneers ready for placement

the following protocol:

- The restorations were etched with hydrofluoric acid for 60 seconds, rinsed under running water and dried with compressed air.
- The veneers were then conditioned with silane. A universal primer (Monobond® Plus) was applied, allowed to react for 60 seconds and dried.
- The prepared teeth were etched with 37% phosphoric acid gel (Total Etch) and rinsed.
- Fluoride-releasing Excite®F DSC adhesive was applied (without light-curing).
- The veneers, which were coated with luting composite, were seated.
- The luting composite was tack-cured for 1 to 2 seconds (Bluephase with Polywave LED) to facilitate the clean-up of excess luting composite.
- Final light curing of all veneers for 40 seconds
- Removal of the rubber dam and occlusal check. At the last step, the restorations were polished.

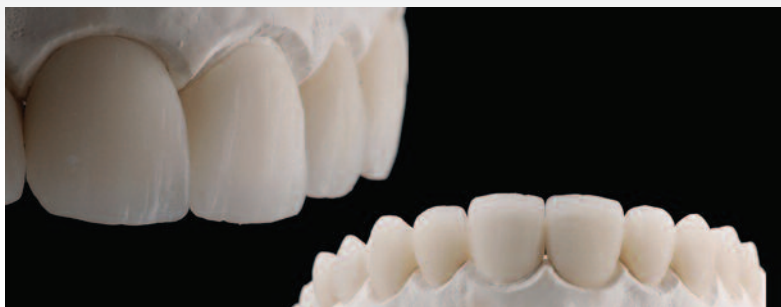

Figure 12: Restorations on the model after CAD/CAM-supported fabrication of the ceramic veneers.

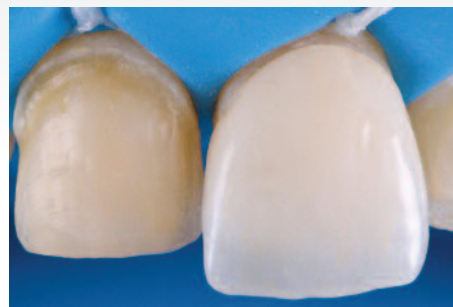

Figure 13: Adhesive cementation of the ceramic veneers with a rubber dam in place.

The ceramic restorations show an appealing esthetic appearance in the mouth and harmonize beautifully with the smile of the young patient. The planned situation was accurately transferred to the final restoration (Figs 14 to 16).

Conclusion

Modern materials in esthetic dentistry allow pleasing results to be achieved with considerably more ease than before. It may be considered a substantial progress that the resulting

restorations meet not only high esthetic requirements but also essential functional criteria. State-of-the-art planning tools, digital auxiliaries, CAD/CAM-supported manufacturing and promising materials lead to excellent results and ensure high patient satisfaction. However, never mind the CAD/CAM technologies, the skills and experience of a seasoned dental technician will remain indispensable.

Reprinted with permission by Reflect 1/2017

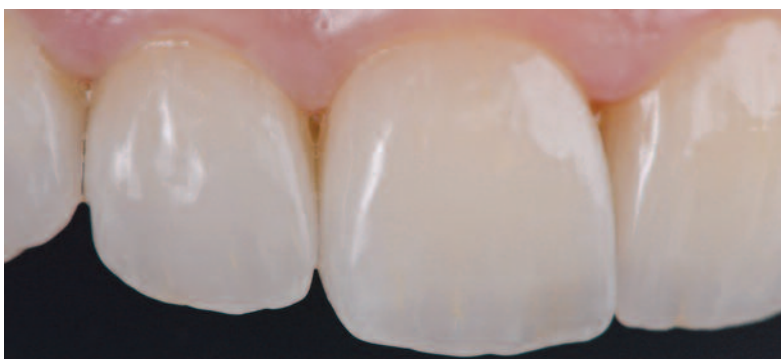

Figure 14: Close-up of the veneers after seating.

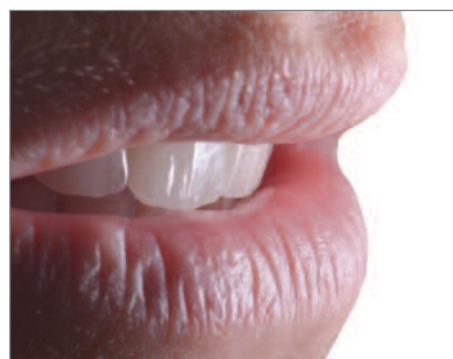

Figure 15: Texture and tooth shape look natural and harmonize with each other.

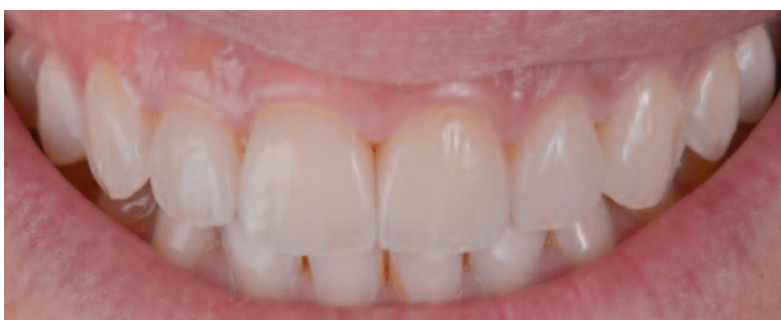

Figure 16: Lip appearance and portray picture (below) with the completed restorations. The expectations of the patient have been met.

