

Full-arch maxilla restoration with immediate implant loading: a 10-year follow-up

Dennis Rohner¹

Introduction

Dental implants are integral to contemporary prosthetic dentistry, providing a stable foundation for dental prostheses and facilitating the restoration of normal masticatory function, speech, and esthetics. The use of bone level implants is particularly advantageous in achieving optimal osseointegration and long-term stability, essential for the success of full-arch prostheses. Straumann® Bone Level implants, designed with a tapered effect and advanced surface technology, have been associated with high survival rates and minimal marginal bone loss over extended periods.

Quality of life (QoL) is a critical parameter in assessing the success of dental treatments. Numerous studies have highlighted the positive impact of implant-supported rehabilitations on patients' psychological well-being, social interactions, and overall life satisfaction. For instance, a systematic review reported significant improvements in dental patient-reported outcomes (dPROs) in individuals undergoing full-arch implant restorations¹. In addition, a recent publication demonstrated high implant survival rates (97.9%) and patient satisfaction over a 10-year follow-up period².

This case report details the full-arch rehabilitation of a patient using Straumann® Bone Level implants, focusing on long-term outcomes and improvements in the patient's quality of life. The patient's clinical journey, from initial consultation to postoperative follow-up, is discussed, highlighting the procedural nuances and the benefits observed. By presenting this case, we aim to contribute to the growing body of real-world and scientific evidence supporting the efficacy of Straumann® Bone Level implants in full-arch rehabilitations and their role in enhancing patient-centered outcomes.

Initial situation

A 68-year-old female, classified as ASA I, with no significant medical history, medications, or allergies, presented to our clinic with concerns regarding the appearance of her remaining front teeth, which led to embarrassment and the need for psychiatric support. The patient's occupation as a teacher for young children accentuated her desire for an esthetically pleasing smile. She wished for a fixed dental solution.

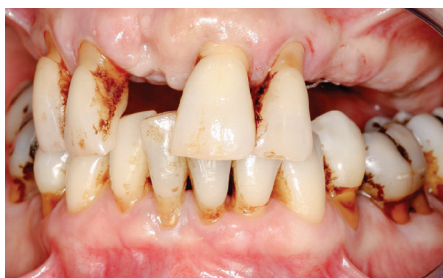

Fig. 1

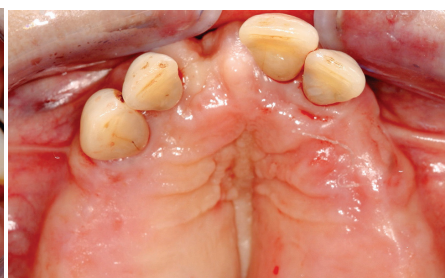

Fig. 2

¹ PD Dr. Dr. Dennis Rohner
Associate Professor, University of
Basel, Switzerland
Senior consultant, Craniofacial
Center, Aarau, Switzerland

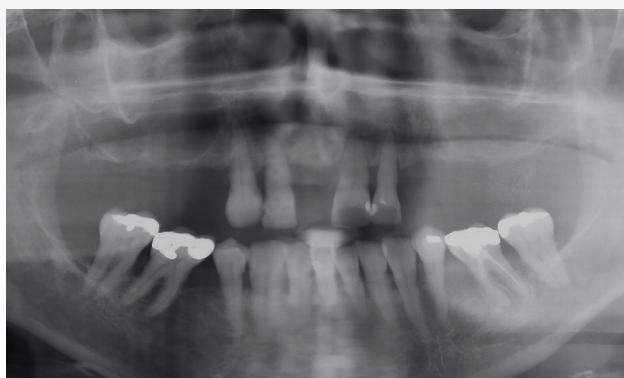

Fig. 3

The extraoral examination revealed a medium smile line with slightly protruding incisors. During the intraoral examination of the upper jaw, a dentition in poor condition was noted, with only four teeth remaining. This condition was characterized by the loss of periodontal support, bleeding on probing, and dental mobility (Figs. 1,2).

The radiographic examination indicated both vertical and horizontal loss of bone support in the upper jaw. Furthermore, it was evident that, while there was sufficient bone in the posterior sector for implant placement, it was limited in quantity (Fig. 3).

According to the SAC classification, the patient was classified as complex from both the surgical and prosthodontic standpoints (Fig. 4).

Treatment planning

After thorough evaluation and consideration of treatment options, it was decided to proceed with immediate implant placement in the upper jaw as part of the patient's comprehensive full-mouth rehabilitation plan. This approach aims to restore both function and esthetics, with a particular focus on effectively addressing concerns through a fixed solution utilizing dental implants. Teeth were carefully

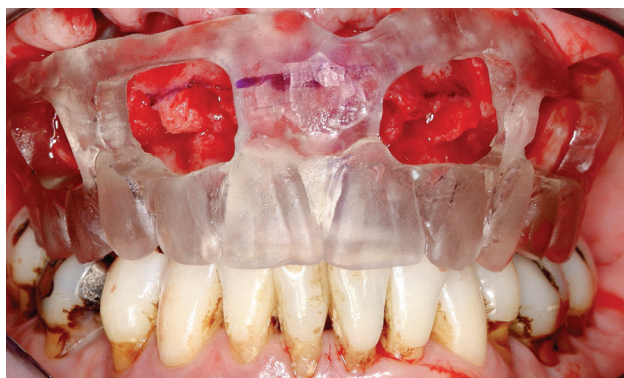


Fig. 5

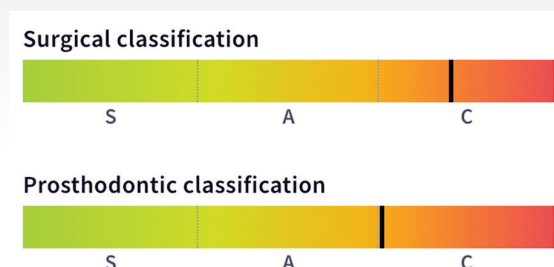


Fig. 4

extracted with minimal trauma to preserve the remaining bone. Following the extractions, implants were immediately placed, and a temporary fixed bridge was fabricated and installed on the same day as the surgery. The treatment workflow included

1. Planning for extraction and immediate placement of implants in the upper jaw.
2. Prospective dentition due to the situation of the lower jaw ending in a correct occlusion.
3. Digital planning based on the CBCT scan and preparation of surgical stent.
4. Use of a surgical stent for pilot drilling.
5. Use of Straumann® BL SLActive® straight anterior and tilted posterior implants.
6. Immediate fabrication of a temporary fixed bridge on the same day as the surgery.
7. Keep the smile line to fulfill esthetic requirements.

Surgical procedure

Local anesthesia with lidocaine 2% with epinephrine 1:100,000 was administered. A mucoperiosteal flap with a crestal incision was raised. The surgical stent was checked and positioned for implant placement, ensuring the proper positioning and angulation of the implants within the bone (Fig. 5). The alveolar bone was slightly reduced and

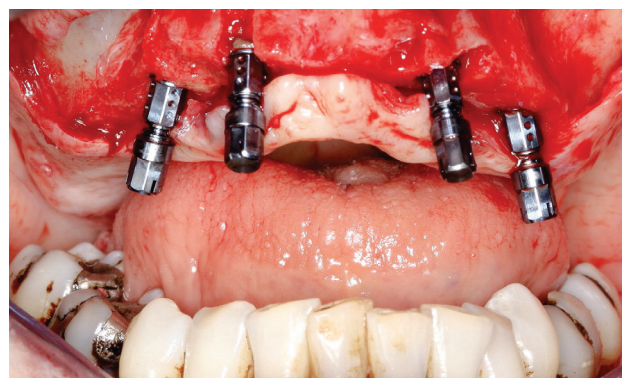

Fig. 6

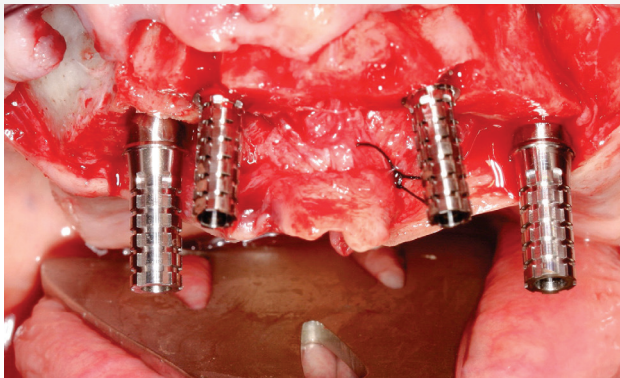


Fig. 7

flattened. The Straumann® Surgical Cassette was utilized to prepare the implant bed, following the pilot drilling protocol. Four Straumann® BL SLActive® implants were inserted, with straight implants positioned in the front and tilted implants at the back. Utilizing the handpiece at a maximum speed of 15 rpm, the implants were placed in a clockwise direction and torqued to 35 Ncm (Fig. 6).

Following implant placement, screw-retained 0°-straight and 30°-angulated abutments, and temporary abutments were placed to correct occlusal orientation (Fig. 7). Subsequently, the mucoperiosteal flap was meticulously adapted, wound closure was performed, and the impression could then be taken (Fig. 8).

Following the surgical procedure, a temporary fixed bridge was inserted on the same day for immediate loading (Fig. 9). Subsequently, radiographic control was conducted after the placement of the temporary restoration (Fig. 10).

At the suture removal appointment, healing was noticed to be uneventful.

Prosthetic procedure

Six months later, after both implants had healed and

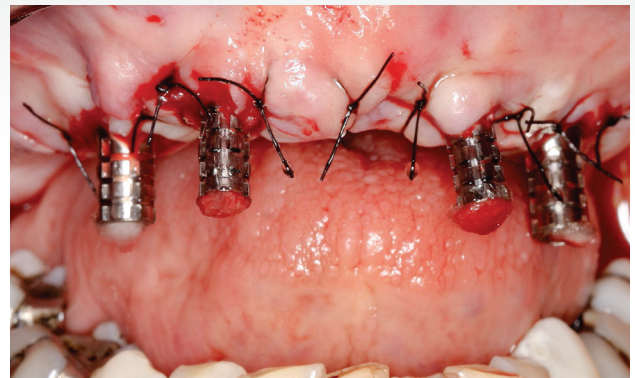


Fig. 8

osseointegration was successfully achieved, an impression was taken on the level of the screw-retained abutments, and the final titanium scaffold was milled (Fig. 11). Subsequently, the final bridge with white and pink esthetics was completed (Fig. 12). The patient received detailed oral hygiene instructions, and occlusion was thoroughly checked to ensure proper alignment and function.

Treatment outcomes

The outcome highlights the exceptional health of both hard and soft tissues. The full bridge showcases the clinical situation seven years after surgery (Fig. 13). Additionally, the panoramic radiograph shows stable bone levels seven years following implant insertion (Fig. 14). The clinical situation with a smile after 7 years (Figs. 15,16).

At the 10-year follow-up, the panoramic radiograph indicated stable peri-implant bone levels. The marginal bone remained intact, and there were no indications of peri-implantitis. The integrity of the implant rehabilitation was also preserved, showing no fractures, wear, or detachment (Fig. 17). The clinical assessment showed that the peri-implant soft tissues were in a healthy condition with no signs of

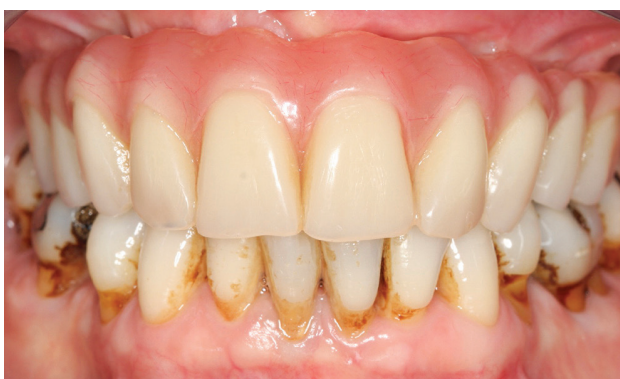

Fig. 9

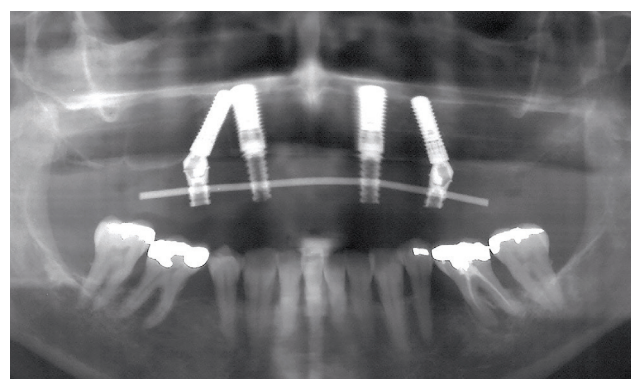


Fig. 10

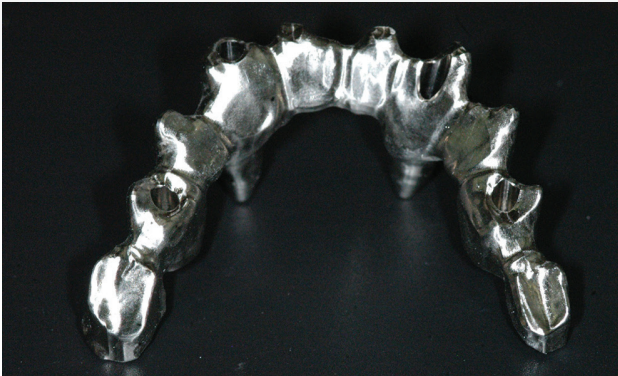

Fig. 11

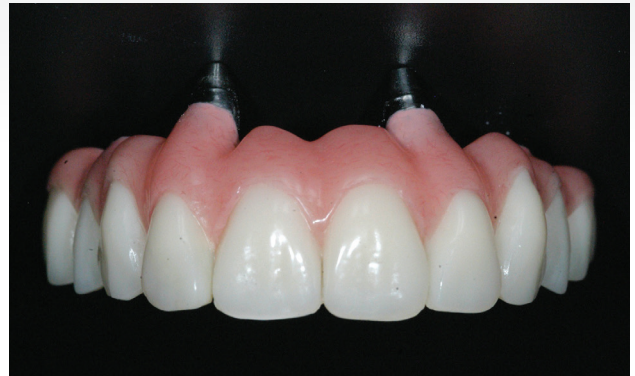

Fig. 12

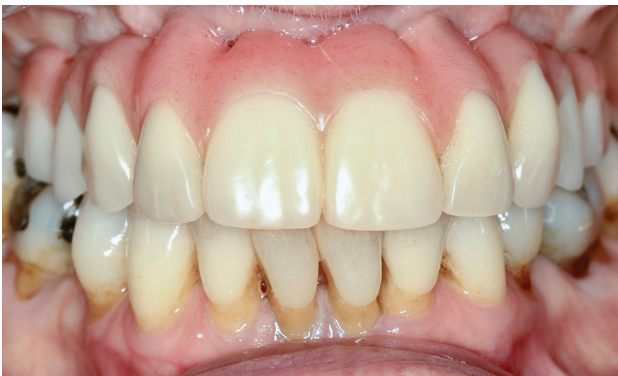

Fig. 13

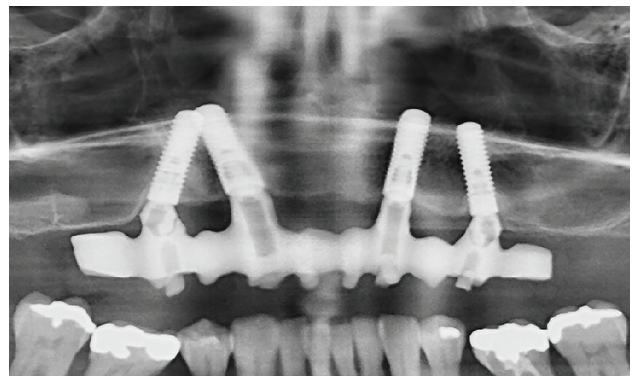

Fig. 14

inflammation or infection. Probing depths around the implant were within normal limits and there was no bleeding on probing. Functionally, the implant-supported rehabilitation was performing well, with no discomfort or mobility reported by the patient. The occlusion was stable, contributing to satisfactory masticatory function (Fig. 18).

This 10-year follow-up underscores the long-term success and stability of a full-arch maxilla restoration with immediate implant loading achieved through meticulous surgical

technique, appropriate prosthetic design, and consistent maintenance. The positive outcome in this case highlights the importance of adhering to proper planning, placement, rehabilitation, and follow-up protocols.

The patient successfully underwent full mouth rehabilitation, leading to a notable enhancement in both function and esthetics. The fixed prosthetic restorations not only offered a stable and natural-looking smile but also relieved the patient's previous feelings of shame and embarrassment.

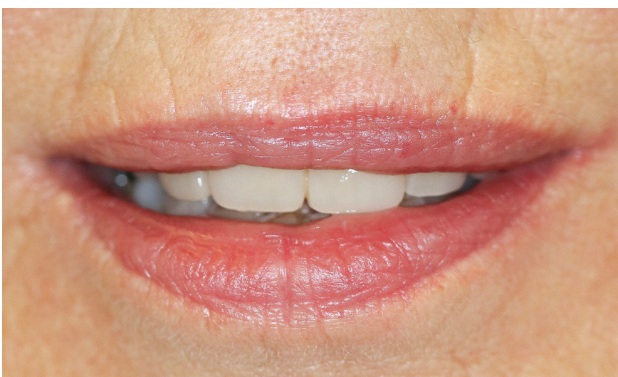

Fig. 15

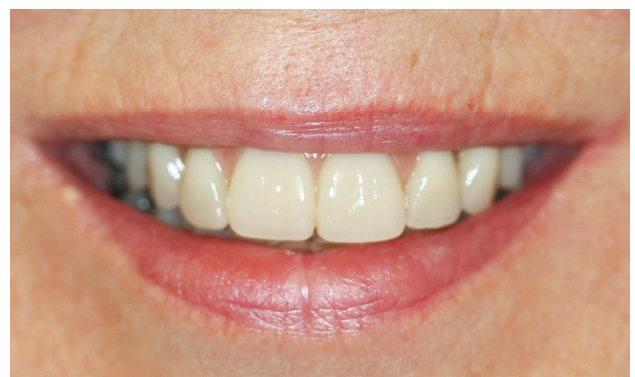

Fig. 16

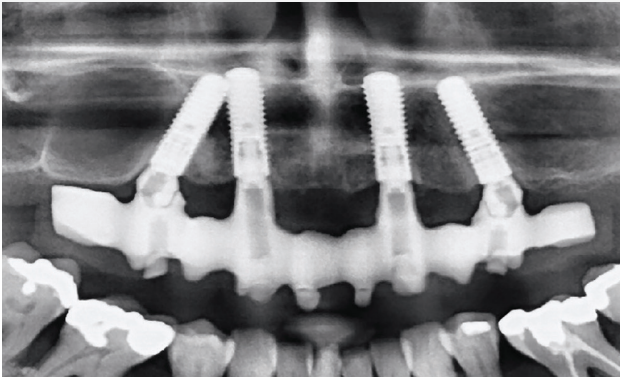


Fig. 17

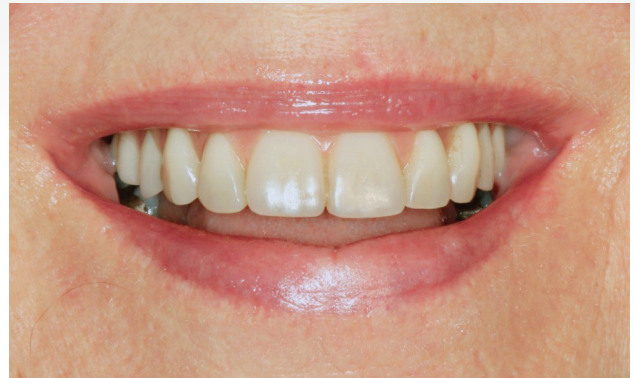

Fig. 18

Subsequent post-treatment follow-ups revealed satisfactory healing and adaptation to the new dental restorations.

This case emphasizes the importance of addressing both the dental and psychological aspects of patients' well-being in full-mouth rehabilitation. By providing comprehensive treatment that includes fixed prosthetic solutions, it is possible to restore both function and esthetics, leading to improved self-esteem and social interactions. The successful rehabilitation of failing dentition in this 68-year-old patient highlights how such interventions can significantly enhance the overall quality of life and patient satisfaction.

The patient expressed profound happiness, stating, "I am indescribably happy. All my shame and problems with my mouth disappeared 7 years ago when I received my new smile. Nowadays, I have open access to my young scholars. I even extended my retirement because I felt so relieved due to my natural laugh with fixed teeth. I have a new life. Thank you so much!" This testimony illustrates the transformative impact of a dental intervention on patients' lives, allowing them to enjoy newfound confidence and social freedom.

Author's testimonial

"Most patients with compromised dentitions wish for a one-stage reconstruction and rehabilitation. Based on meticulous analog and/or digital planning, the surgery and prosthetic rehabilitation can be achieved on the same day, leaving a happy patient. Surgical expertise and excellent technical support are mandatory to reach the planned outcome."

References

1. Abou-Ayash S, Fonseca M, Pieralli S, Reissmann DR. Treatment effect of implant-supported fixed complete dentures and implant overdentures on patient-reported outcomes: A systematic review and meta-analysis. *Clin Oral Implants Res.* 2023 Sep;34 Suppl 26:177-195.
2. Diez-Fraile A, Barbier L, Abeloos J. Maxillary bone augmentation with calvarial bone graft for immediate full-arch rehabilitation: Insights from a 10-year proof-of-concept retrospective analysis. *Clin Oral Implants Res.* 2024 Feb;35(2):201-219

Reprinted with permission from youTooth, 01. July 2024