

MTA vpt - preserving pulp vitality in daily practice

Reliable Pulp Protection

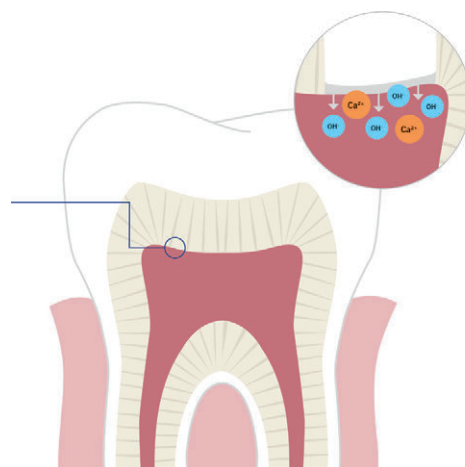
In daily practice, reliable pulp protection is essential to preserve the vitality of the pulp. Biocompatibility and a stable, bacteria-proof seal are substantial properties. High compressive strength and low solubility of the material used are particularly important for the longevity of the protective seal.

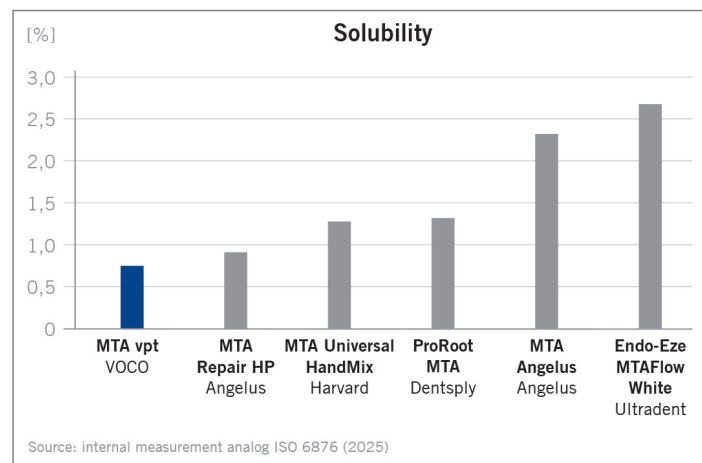
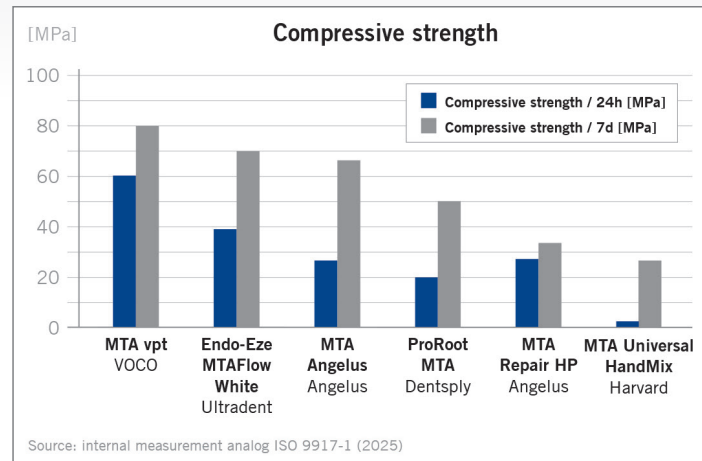
Mineral Trioxide Aggregate (MTA) meets these requirements: MTA materials are considered the benchmark for biocompatibility.¹ They set during the cementation reaction to form a reliably stable layer and release calcium and hydroxide ions that stimulate the formation of reparative dentine^{2,3} and the body's own regeneration of the pulp.⁴ The resulting high pH is known to be bacteriostatic and promotes remineralisation.^{5,6} In scientific research, the excellent sealing properties of the material are also attributed to the ion release and subsequent apatite formation.² Numerous studies on MTA materials, chemically referred to as calcium silicate-based cements, document their reliable high clinical success rates in *Vital Pulp Therapy (VPT)*.^{7,8}

MTA vpt from VOCO (Cuxhaven, Germany), which consists mainly of tricalcium silicate, offers all these advantages of the material class and thus creates a long-term, stable and tight seal – the optimal base for preserving the vitality of the pulp. In accordance with its indications, it can be used in deep carious lesions or in cases of traumatic pulp exposure. MTA vpt also supports the objectives of caries management and, by extension, those of the VPT.

Direct pulp capping

When pulp exposure is unavoidable or caused by trauma, MTA vpt can be used to protect the exposed pulp tissue. MTA materials have a very good and reliable success rate in direct pulp capping.⁹ This is mainly due to a more predictable formation of tertiary dentin, i.e. hard dentin bridges.¹⁰





A solid base

Durability

Low solubility and high compressive strength are important indicators of the long-term durability and solidity of MTA cements. MTA vpt exhibits particularly good values in this respect, which ensures the stability and longevity of the entire restoration. MTA vpt sets via a multi-stage cement reaction to form a reliably stable sealing. Optimal X-ray visibility is ensured with an opacity of 290 % Al.

Improved product composition

MTA vpt is free of bismuth oxide and iron-containing compounds – this prevents product-related discolouration, as known from early MTA cements.^{11,12}

Monomer-free

Unlike other MTA materials, MTA vpt does not contain methacrylates, the use of which is often considered critical in

proximity of the pulp.¹³ In particular, the cytotoxic properties of the monomers are a concern when they come into contact with the pulp.

Wide range of applications

Management of deep carious lesions

MTA vpt is perfectly suited for caries management – caries treatment by selective or stepwise excavation. Caries management helps to avoid over excavation and, especially near the pulp, the exposure of the pulpal cavum.^{14,15} If a small amount of carious dentin must remain for this purpose, MTA vpt can be used as a bacteria-proof barrier for indirect pulp capping.

Application anterior region

MTA vpt is characterised by high shade stability. This is particularly important for cases in the anterior region. After

hemostasis, MTA vpt is applied directly to the exposed pulp tissue. When mixed, MTA vpt has a slightly bluish colour, which changes to a white-opaque shade as it sets.

Pediatric dentistry

MTA vpt is also perfectly suited for pediatric dentistry. MTA materials are hydrophilic and require no additional conditioning, which simplifies clinical application. They can be used, for example, after a pulpotomy on deciduous teeth.^{16,17} The use of VPT methods in conjunction with MTA materials for first dentition has been confirmed by research.^{18,19} The completion of root formation (apexogenesis) can be supported by a protective layer with MTA vpt after a vital amputation.

Filling therapy and handling

MTA vpt is applied directly to the unconditioned dentine. In the case of exposed pulp, hemostasis is performed first if necessary. Then the pulp tissue and the adjacent dentine are covered with MTA vpt. A light-curing flowable or flowable glass ionomer cement can then be applied immediately without exerting pressure.

When mixing by hand, the consistency of MTA vpt can be easily varied by adding powder or liquid, depending on the application situation. Application and adaptation is carried out using suitable instruments such as spatulas and cement plugger.

Vital Pulp Therapy

Vital Pulp Therapy (VPT) has become a key concept for deep carious lesions, traumatic pulp opening or restorative treatments. It combines proven methods for preserving the vitality of the pulp with a rethinking of diagnostic classification and therapy.²⁰ The use of MTA materials in particular is advocated in this concept.^{8,21} The primary aim of VPT is to avoid pulpectomy with subsequent root canal treatment or even extraction. MTA vpt can be used in VPT for all its indications.

VPT benefits

• **Tooth preservation**

VPT enables the preservation of natural tooth structure and function by maintaining the vitality of the pulp.

• **Cost efficiency**

A VPT is generally less expensive than a complete root canal treatment and reduces possible subsequent treatments.^{22,23}

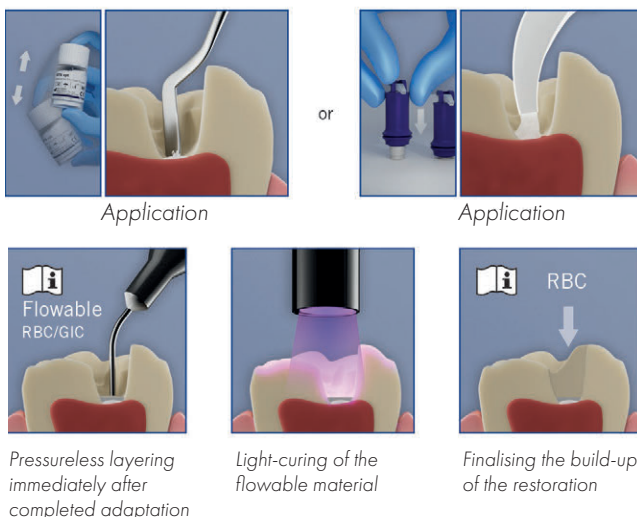
• **Minimally invasive**

Complex endodontic treatments can be avoided in many cases with minimally invasive procedures.

• **Long-term prognosis**

The natural defense function and the perception of internal stimuli are maintained, resulting in improved long-term prognosis and reduced risk of fracture.²⁴

Application



Indirect pulp capping / lining

The preference for MTA materials in indirect capping is justified by their low solubility and the resulting non-absorbing material properties.²⁵ In the context of VPT, indirect capping gains additional importance if pulp opening by means of selective caries excavation is avoided.

Partial or complete pulpotomy

MTA vpt can be used after a vital amputation for both partial and complete pulpotomy. It provides reliable coverage for treatment of the remaining pulp tissue. Research confirms the very good success rates of this treatment in conjunction with MTA cements.^{8,26}

Preservation of Vital Pulp Therapy

Indications

- Base fill cement for all restorative materials
- Indirect pulp capping
- Direct pulp capping
- Treatment of pulp following vital amputation

Advantages

- MTA for everyday clinical practice – biocompatible, free of monomers
- High pH value (12) – known for its bacteriostatic effect
- Release of calcium and hydroxide ions – promotes formation of tertiary dentine and remineralisation
- Reliable pulp protection – mineralises to form a stable bacteria-proof seal
- Time-efficient – immediate further processing thanks to layering without pressure
- Easy handling – application with standard instruments or directly from the capsule
- No product-related discolouration – free of bismuth oxide and ferrous compounds
- Radiopaque (290 % Al)

References

1. Murray P in Shelton R (ed.) 2017 Biocompatibility of dental biomaterials, p. 41
2. Okiji T, Yoshiba K, 2009 – <https://doi.org/10.1155/2009/464280>
3. Song M, Yu B et al., 2017 – <https://doi.org/10.1016/j.cden.2016.08.008>
4. Islam R, Islam RR et al., 2023 – <https://doi.org/10.1016/j.jdsr.2023.02.002>
5. Watson TF, Atmeh AR et al., 2014 – <https://doi.org/10.1016/j.dental.2013.08.202>
6. Tay FR, Pashley DH, 2008 – <https://doi.org/10.1016/j.biomaterials.2007.11.001>
7. Xavier MT, Costa AL et al. 2024 – <https://doi.org/10.3390/ma17174264>
8. Parirokh M, Torabinejad M et al., 2017 – <https://doi.org/10.1111/iej.12841>
9. Hilton TJ, Ferracane JL et al., 2013 – <https://doi.org/10.1177/0022034513484336>
10. Li Z, Cao L et al., 2015 – <https://doi.org/10.1016/j.joen.2015.04.012>
11. Camilleri J, Borg J et al., 2020 – <https://doi.org/10.1371/journal.pone.0240634>
12. Al-Hiyasat AS, Ahmad DM et al., 2021 – <https://doi.org/10.1186/s12903-021-01677-y>
13. García-Mota LF, Hardan L et al., 2022 – <https://doi.org/10.1016/j.jebdp.2022.101776>
14. Duncan HF, Galler KM et al., 2019 – <https://doi.org/10.1111/iej.13080>
15. Bjørndal L, Simon S et al., 2019 – <https://doi.org/10.1111/iej.13128>
16. Guo J, Zhang N et al., 2023 – <https://doi.org/10.1007/s00784-022-04830-1>
17. AAPD, 2020 - https://www.aapd.org/media/Policies_Guidelines/BP_PulpTherapy.pdf
18. Coll JA, Dhar V et al., 2024 – <https://pubmed.ncbi.nlm.nih.gov/38449041>
19. Smail-Faugeron V, Glennly A-M et al., 2018 – <https://doi.org/10.1002/14651858.CD003220.pub3>
20. Cushley S, Duncan HF et al., 2019 – <https://doi.org/10.1016/j.jident.2019.06.005>
21. Kahler B, Taha NA et al., 2023 – <https://doi.org/10.1111/adj.12997>
22. Amato M, Hecker H et al., 2017 – <https://doi.org/10.1055/s-0043-119653>
23. Emara R, Krois J et al., 2020 – <https://doi.org/10.1016/j.jident.2020.103330>
24. Dammaschke, Galler et al., 2019 (p.44) – <https://doi.org/10.3238/dzz-int.2019.0043-0052>
25. Petrou MA, Alhamoui FA et al., 2014 – <https://doi.org/10.1007/s00784-013-1107-z>
26. Wang W, Zeng Q et al., 2024 – <https://doi.org/10.1016/j.jident.2024.105392>

MTA Angelus, MTA Repair HP, ProRoot MTA, Endo-Eze MTAFlow White, Harvard MTA Universal HandMix are not registered trademarks of VOCO GmbH.

A complete bibliography can be found at:
www.voco.dental/MTAvpt_lit