

Maxillary sinus surgery: Anatomy and advanced diagnostic imaging

Tiziano Testori¹

Abstract

No treatment plan for the posterior maxilla can fail to consider the status of the maxillary sinus. If pneumatization of the sinus or alveolar bone resorption has occurred, then bone grafting or sinus elevation may be necessary to enable implant-supported rehabilitation. Anatomic features including the Schneiderian membrane, the major arteries and nerves, and any bony septa optimally should be three-dimensionally rendered with advanced diagnostic imaging technologies such as computed tomography (CT). A determination can then be made as to whether alternatives to sinus elevation may be considered. If sinus elevation is inevitable, it is essential to have an excellent understanding of the sinus anatomy, which is briefly outlined in this article.

Key words: sinus anatomy, maxilla, diagnostic imagery

Introduction

In developing any treatment plan for the maxilla that includes the posterior regions, the status of the maxillary sinus must be carefully considered. Pneumatization of the sinus may limit the amount of residual bone. Given the tendency of the alveolar ridge to progressively resorb after tooth loss and the typically poorer quality of posterior maxillary bone, rehabilitation of this area with implant-supported fixed prostheses has traditionally been challenging.

Clinicians initially tried to solve the problem of insufficient posterior bone support by using prostheses with distal extensions supported by implants placed anteriorly or by combining long implants in the anterior with short posterior implants. However, by the late 1970s, Tatum¹ and Boyne² were reporting on an alternative: elevation of the maxillary sinus in order to better accommodate placement of endosseous implants. Since then, numerous approaches to maxillary sinus elevation have developed, and a substantial body of research has demonstrated the procedure to be predictably successful.³ At the same time, other alternatives have also developed, including the use of reduced-length implants with roughened surfaces or tilted implants inserted in a variety of ways.

This article briefly reviews the role of computed tomography (CT) when sinus-augmentation surgery is being considered.

¹ Tiziano Testori, MD, DDS
Assistant Clinical Professor and Head of the Section of Implant Dentistry and Oral Rehabilitation, Department of Odontology, at the University of Milan, Milan, Italy.
Private Practice, Como, Italy.
www.implantologiaitalia.it.

The Role of CT in Sinus Augmentation

When the alveolar process has resorbed significantly and sufficient bone to accommodate implants appears to be unavailable, diagnostic imaging plays a vital role, providing reliable and necessary information.^{4,5} CT offers considerable advantages compared with traditional diagnostics (orthopantography, intraoral radiographs). For complex dental operations, CT must be considered an essential presurgical diagnostic method (Figures 1-3).⁶⁻⁸

With three-dimensional reconstructions based on CT scan data, morpho-volumetric analysis of the planned surgical site becomes relatively simple, and the available densitometric information ensures much higher diagnostic confidence compared with conventional radiologic investigation. Electronic reconstructions are now available in various rendering modes that synthesize an enormous amount of information, contained in hundreds of axial images. In addition to being immediate and diagnostically exhaustive, these images can be easily interpreted by operators.

Combining the scan data with a computer-guided surgical system such as the Tapered Navigator® Kit (BIOMET 3i) for CT guided surgery may make it possible to place implants despite the anatomical limitations. CT guidance technology allows clinicians to measure with great precision the locations of anatomic structures and the dimensions of underlying bone. Bone densities can also be easily identified, and an accurate surgical guide with precise surgical instrumentation can be fabricated. The use of these combined tools sometimes enables placement of implants when the bone under the maxillary sinus is minimal.

If a sinus elevation is unavoidable, a variety of anatomical factors may influence the design of the lateral window and the choice of graft material. Information on bone density, bone cortical walls, and bone resorption in the alveolar processes is important for planning functionally and aesthetically optimal prosthetic treatment. Information on associated orosinus pathologies is also important.

Determining the position and patency of the maxillary sinus ostium is essential when planning sinus-elevation procedures. Of particular importance is the integrity of the ostio-meatal complex, the morpho-functional unit used for drainage and aeration of the anterior ethmoidal cells, the maxillary sinuses, and the frontal sinuses. CT scanning allows for precise evaluation of its numerous components, revealing any irregularities in development (e.g. bulla conche, septum deviation, or inflammation involving the maxillary sinus ostium). Respecting the structure of the ostium is essential for a successful operation.

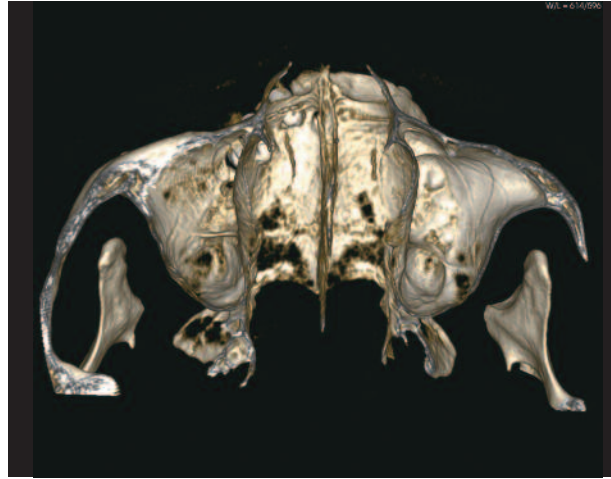

Figure 1: High definition 3D reconstruction of the maxillary bone.

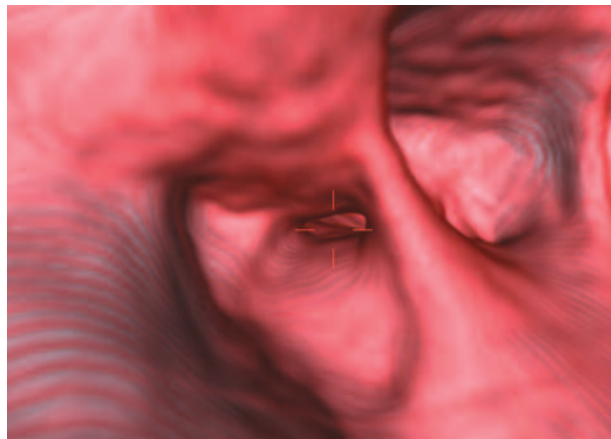


Figure 2: Virtual endoscopy with VRT superimposition of soft tissues can be used to check patency.

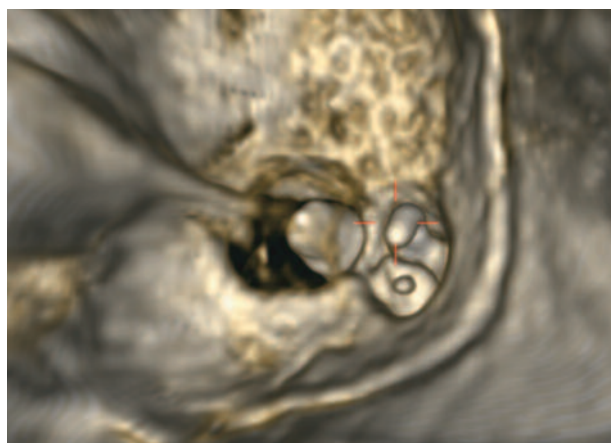


Figure 3: Virtual endoscopy used to analyze the tooth positions with respect to the maxillary sinus floor.

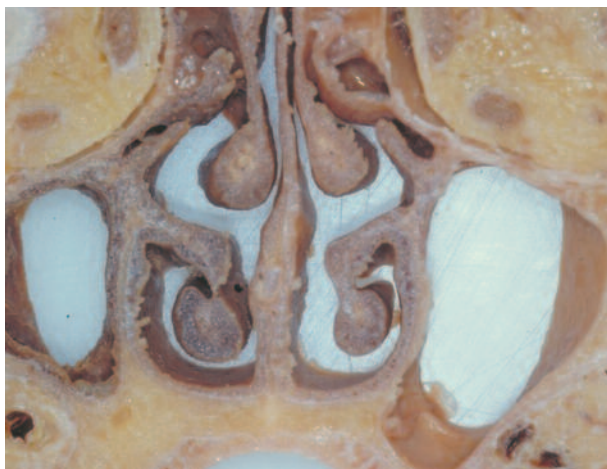

Figure 4: Frontal section of the maxillary sinuses. Hyperpneumatization of the left sinus and atrophy of the alveolar ridge subsequent to tooth loss is evident.

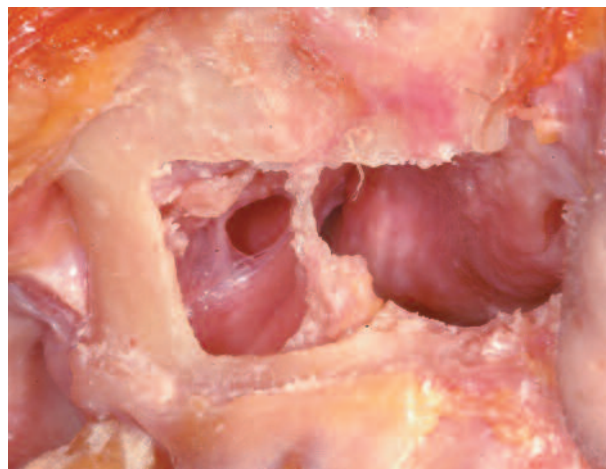


Figure 5: Relationship between the nasal cavity and the maxillary sinus.

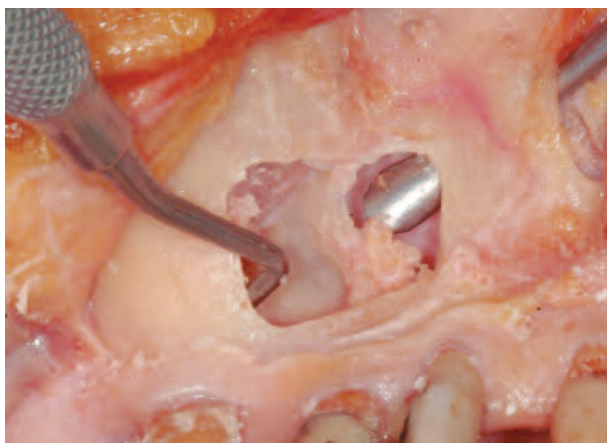


Figure 6: The instrument enters from the pyriform opening and reaches the medial wall of the sinus (the lateral wall of the nasal cavity).

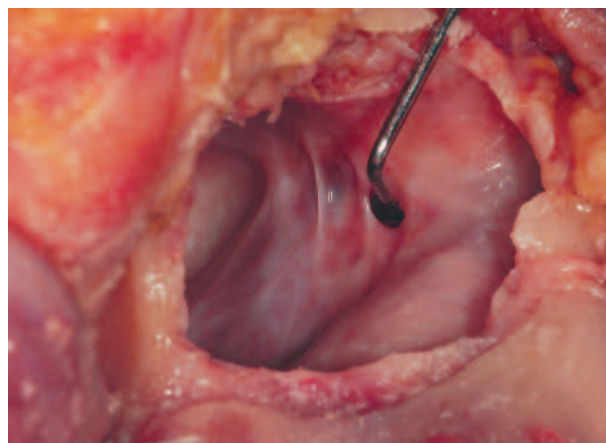


Figure 7: The foramen of the sinus ostium is normally a 6mm by 3.5mm oval.

Overview of the Sinus Anatomy

All the paranasal sinuses occupying the maxillary bone humidify and warm the inhaled air. They also thermally insulate the upper nerve centers, protect the skull base from trauma, influence phonation by acting as an indirect resonance box, and contribute to reducing the weight of the facial bones.^{9,10} The largest of the paranasal air cavities, the maxillary sinus includes a medial wall that separates the maxillary sinus from the nasal cavity, a posterior wall facing the maxillary tuberosity, a mesio-vestibular wall containing the neurovascular bundle, an upper wall constituting the orbit floor, and a lower wall next to the alveolar process that is the bottom of the maxillary sinus itself (Figures 4 and 5).¹¹

The maxillary sinus communicates with the homolateral nasal fossa by means of a natural ostium located postero-superiorly on the medial surface (Figures 6 and 7). In adults with a full set of teeth, the maxillary sinus floor is the strongest of the bone walls surrounding the cavity. However, as aging occurs, the sinus floor tends to resorb and form dehiscences around the roots. The root ends may jut into the cavity, covered only by the Schneiderian membrane and a small bone cortex flap (which in turn may be missing). Extreme care must be taken to avoid tearing the membrane when separating it from such exposed apices.

The mesio-vestibular and medial bone walls are the ones most often involved in maxillary sinus surgery. An accessory

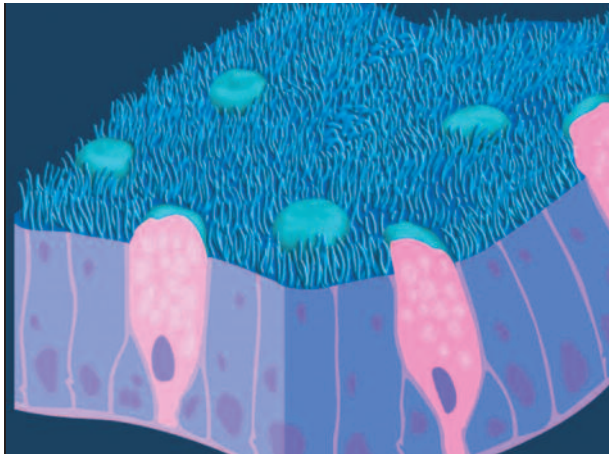


Figure 8: Diagram of the Schneiderian mucosa with various cellular components.

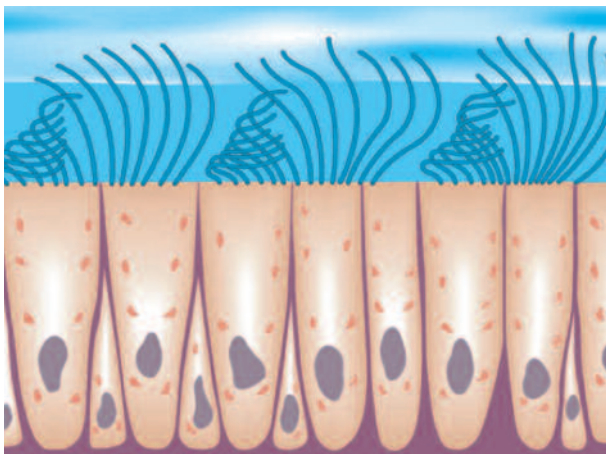


Figure 9: Diagram of the ciliated epithelium, propellant for sinus secretions.

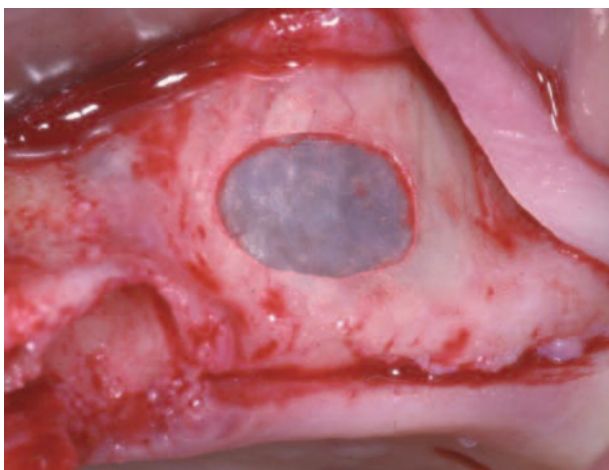


Figure 10: A thin sinus membrane.

ostium may sometimes be found on the medial wall. When this occurs, it should be identified before any maxillary sinus-elevation procedure is performed, to avoid detaching the mucosa up to this point.

The Sinus Membrane

The Schneiderian (mucous) membrane lines the inner walls of the sinus and in turn is covered by pseudo-stratified columnar ciliated epithelium (Figures 8-10). Serum-mucosa glands are located in the lamina directly underneath, especially next to the ostium opening. Normally the thickness of the Schneiderian membrane varies from 0.13mm to 0.5mm. However, inflammation or allergic phenomena may cause it to thicken, either generally or locally (in streaks). In such cases, it may be necessary for an otolaryngologist to restore the sinus to a physiologic state before a sinus-lift operation can be carried out.

Progressive Change, Edentulism, and Bone Resorption

In cases of maxillary edentulism, progressive resorption of the alveolar ridge may reduce the bone to a thickness of less than 1mm. Several causes may contribute to this phenomenon. Teeth and the masticatory loads they apply stimulate the alveolar bone and limit its resorption. Immediately after the avulsion of a tooth, significant bone-modeling typically occurs. Vertical bone loss later tends to stabilize, averaging about 0.1mm/year, though large variations can be found among individuals. However, hormonal imbalances, metabolic factors, inflammation, and certain systemic pathologies can cause the bone resorption to accelerate again. Age and gender may also influence bone loss.

The sinus floor tends to lower craniocaudally as the alveolar ridge is resorbed in the opposed direction. It is the lack of vertical posterior maxillary bone that often necessitates the use of bone grafts or sinus-lifting procedures prior to implant rehabilitation.

Progressive resorption of the posterior maxillary edentulous ridge follows a well-defined path that differs from that of the anterior regions and includes repeatable, predictable morphologic changes. Cawood and Howell's system for classifying the degrees of atrophy based on the morphologic differences in the residual ridge¹² is extremely useful for presurgical diagnostic assessment, as the ridge appearance is connected to the horizontal and vertical size of bone available for implants.

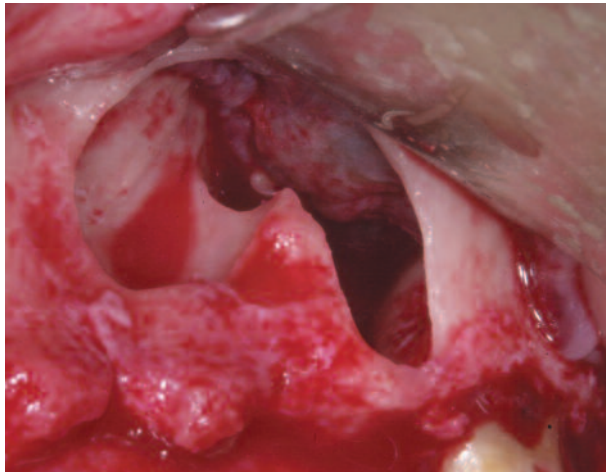


Figure 11: Underwood septa inside the maxillary sinus.

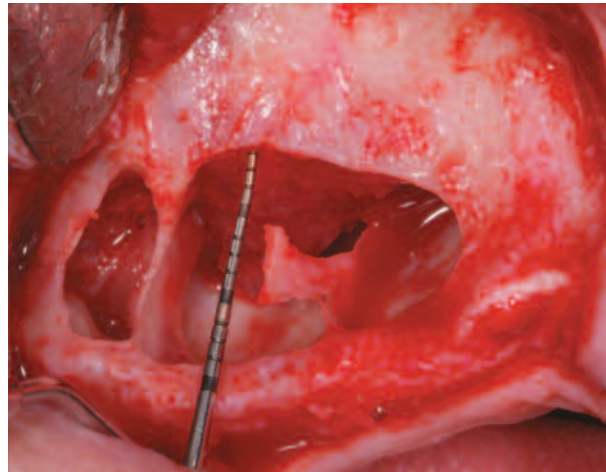


Figure 12: Another view of the Underwood septa.

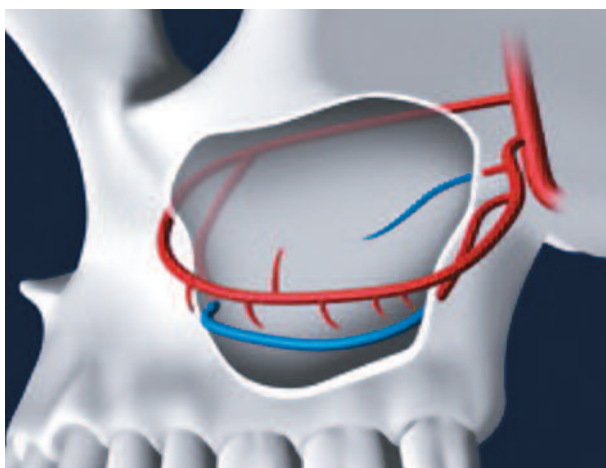


Figure 13: Vascular system of the maxillary sinus.

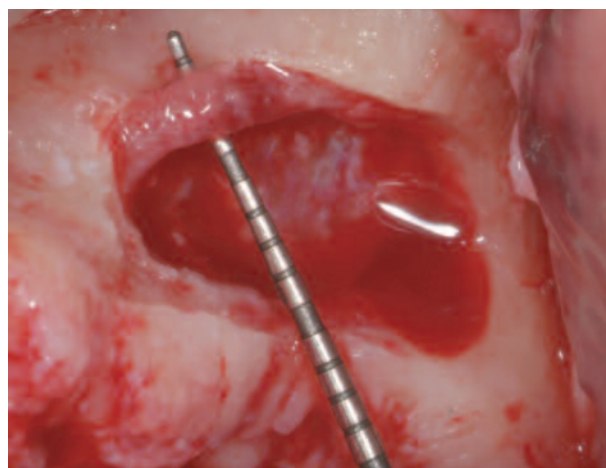


Figure 14: The diameter of this alveolar antral artery, detected during left sinus-floor augmentation, was nearly 3mm.

Bony Septa

Inside the maxillary sinus, bony septa originating in the sinus floor are often found (Figures 11 and 12). Called Underwood septa, they may divide the back part of the sinus into multiple compartments known as posterior recesses. They may even occasionally reach from the base to the upper sinus wall, creating two sinuses.¹³ Estimates of the prevalence of such septa have ranged from 16 to 58%.¹⁴⁻¹⁷

The formation of Underwood septa may be linked to the fact that teeth are lost at different times. The edentulous areas may resorb in a manner that results in a difference in level between the two adjacent portions of the sinus floor. It is thought that a bony septum may form in the area between the two regressing areas in order to transfer

masticatory loads optimally. After the complete loss of teeth, the septa sometimes gradually disappear.¹⁸

A tridimensional x-ray diagnosis of septa presence is important for planning the size, shape, and position of the antrostomy in maxillary sinus elevation and later separating the sinus membrane from the septa.

Vascularization

Three arteries supply blood to the maxillary sinus: the infraorbital artery, the posterior lateral nasal artery, and the posterior superior alveolar artery (Figures 13 and 14). While their presence should be investigated to avoid hemorrhages during sinus-grafting surgery, severe hemorrhages tend to be rare, as the main arteries do not run inside the surgical area.¹⁹

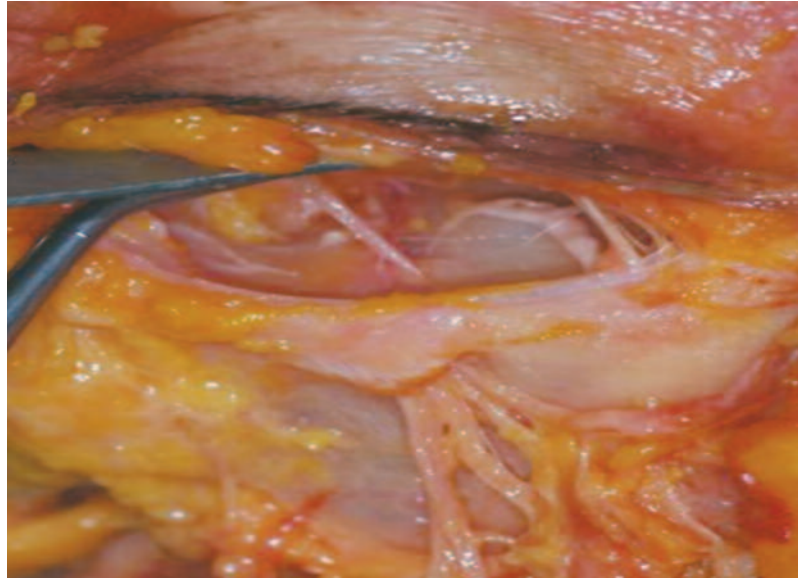


Figure 15: After emerging from the infraorbital foramen, the infraorbital nerve seen in this cadaver dissection splits into smaller branches.

If small vessels located in the exposed Schneiderian membrane are broken, it is better to allow hemostasis to occur naturally. Applying light pressure with a gauze may be effective, however, whereas an electrocoagulator may cause membrane necrosis.

Innervation

Innervation of the maxillary sinus originates directly from the maxillary nerve, the second branch of the fifth cranial nerve. With its posterior middle and superior alveolar branches, it innervates the posterior sinus floor together with the molar and premolar teeth. The anterior superior alveolar branch reaches the anterior sinus wall and the superior dental plexus, running below the Schneiderian membrane.

Some branches starting in the infraorbital nerve branch out from the trunk before exiting the infraorbital foramen (Figure 15). They then innervate the maxillary sinus medial wall. Branches of the pterygopalatine ganglion and the sphenopalatine ganglion also innervate the sinus mucosa.

Clinical Relevance

Any clinician treating the posterior maxilla must have a firm understanding of the anatomy of the maxillary sinus. The use of CT scanning prior to treatment of patients with significant posterior maxillary resorption can provide invaluable information about the precise status of the

patient's bone and other significant structures, making it easier to choose among treatments including sinus-floor elevation.

Disclosure

The contributing clinician has a financial relationship with BIOMET 3i LLC resulting from speaking engagements, consulting engagements, and other retained services.

Reprinted with permission from JOURNAL OF IMPLANT AND RECONSTRUCTIVE DENTISTRY® Vol. 3 No. 1

References

1. Tatum OH. Maxillary sinus grafting for endosseous implants. Lecture, Alabama Implant Study Group, Annual Meeting. Birmingham AL, USA, 1977.
2. Boyne PJ, James RA. Grafting of the maxillary sinus floor with autogenous marrow and bone. *J Oral Surg* 1980;38:613-616.
3. Del Fabbro M, Francetti L, Taschieri S, et al. Systematic review of the literature on maxillary sinus augmentation associated with implantation procedures. In: Testori T, Del Fabbro M, Weinstein R, Wallace S (eds). *Maxillary Sinus Surgery and Alternatives in Treatment*. London: Quintessence, 2009:326-341.
4. Dula K, Buser D, Porcellini B, et al. Computed tomography/oral implantology (I). *Dental CT: A program for*

the computed tomographic imaging of the jaws: The principles and exposure technic. *Schweiz Monatsschr Zahnmed* 1994;104:450-459.

5. Dula K, Buser D. Computed tomography/oral implantology. Dental CT: A program for the computed tomographic imaging of the jaws. The indications for preimplantological clarification. *Schweiz Monatsschr Zahnmed* 1996;106:550-563.

6. Schom C, Engelke W, Kopka L, et al. Indications for dental-CT. Case reports. *Aktuelle Radiol* 1996;6:314-324.

7. Testori T, Sacerdoti S, Barenghi A, et al. La tomografia assiale computerizzata nella moderna implantologia: Reali vantaggi per una corretta programmazione chirurgico-protesi; dose assorbita dal paziente. *Ital J Osseointegration* 1993;1:19-28.

8. Belloni GM, Testori T, Francetti L, et al. TC spirale in implantologia. Valutazione della dose radiante assorbita. *Dental Cadmos* 1999;2:55-58.

9. Blanton PL, Biggs NL. Eighteen hundred years of controversy: The paranasal sinuses. *Am J Anat* 1969;124:135-148.

10. Ritter FN, Lee D. *The Paranasal Sinuses, Anatomy and Surgical Technique*. St. Louis: The Mosby Company, 1978:6-16.

11. McGowan DA, Baxter PW, James J. *The Maxillary Sinus and Its Dental Implications*. Oxford: Wright, Butterworth-Heinemann Ltd., 1993:1-125.

12. Cawood JI, Howell RA. Reconstructive preprosthetic

surgery. I. Anatomical considerations. *Int J Oral Maxillofac Surg* 1988;17:233-236.

13. Miles AEW. The maxillary antrum. *Br Dent J* 1973;134:61-63.

14. Underwood AS. An inquiry into the anatomy and pathology of the maxillary sinus. *J Anatomical Physiol* 1910;44:354-369.

15. Jensen OT, Greer R. Immediate placement of osseointegrating implants into the maxillary sinus augmented with mineralized cancellous allograft and Gore-Tex: Second-stage surgical and histologic findings. In: Laney WR, Tolman DE (eds). *Tissue Integration in Oral Orthopedic and Maxillofacial Reconstruction*. Chicago: Quintessence, 1992:321-333.

16. Ulm CWP, Solar G, Krennmair G, et al. Incidence and suggested surgical management of septa in sinus lift procedures. *Int J Oral Maxillofac Implants* 1995;10:462-465.

17. Kim MJ, Jung UW, Kim CS, et al. Maxillary sinus septa: prevalence, height, location, and morphology. A reformatted computed tomography scan analysis. *J Periodontol* 2006;77(5):903-908.

18. van den Bergh JPA, ten Bruggenkate CM, Disch FJM, et al. Anatomical aspects of sinus floor elevations. *Clin Oral Implants Res* 2000;11:256-265.

19. Testori T, Rosano G, Taschieri S, et al. Ligation of an usually large vessel during maxillary sinus floor augmentation. A case report. *Eur J Oral Implantol* 2010;3(3):255-258.