

The Self-Adjusting File: case reports

Peet van der Vyver¹

Straight and narrow root canals with a round cross-section can be effectively cleaned and shaped with rotary nickel titanium files in order to remove most of the inner layer of the heavily contaminated dentin (Metzger et al, 2010). According to Wu, van der Sluis and Wesselink (2003), this goal is not easily attained in oval, flat or curved root canal systems.

In a study by Wu et al (2000), it was demonstrated that oval or flat root canal morphology is present in up to 25% of root canals, and in certain groups it may be as high as 50%. Radiographically, it is also very difficult to recognize this asymmetry in root canals because it usually occurs in the bucco-lingual dimension.

Most rotary nickel titanium instruments prepare root canals into a form that has a round cross section (Metzger et al, 2010). In oval or flat root canals there is possible untouched areas on the buccal or lingual inner aspects of the root canals or on the side facing the isthmus in tear-shaped root canals after preparation with conventional rotary files.

Figure 1 illustrates a magnified view of a cross-section of the mesial root canals in an extracted root canal treated molar, using conventional NiTi rotary instrumentation. Note the debris that was pushed into the isthmus area (arrows) preventing the root canal cement and obturation material to completely obturate the root canal system. These untouched areas may contain infected tissue or debris that may lead to failure after obturation of the root canal system.

Recently, the Self- Adjusting File (SAF) was developed to ensure complete and conservative removal of the inner infected dentin from all the surfaces of most root canal systems, without the risks of root canal transportation and instrument separation.

The SAF system

The files are designed as a hollow, compressible, thin walled pointed cylinder (1.5 or 2mm) composed of 120um thick nickel titanium lattice (Figure 2). The surface of each

lattice is abrasive and can remove dentin from the root canal wall when activated in a back-and-forth grinding motion. The file can be compressed when inserted into any root canal previously negotiated and prepared up to a ISO size 20. The compressed file will then adapt itself three-dimensionally to the shape of the root canal. In a round canal it will result in a round cross-section and in an oval or flat canal it will result in a flat or oval cross-section after mechanical root canal preparation.

The SAF instrument is activated with a transline (in and out) vibrating handpiece (Gentle Power Lux 20LP, Kavo, Biberach, Germany) adapted with a RDT3 head (Redent-Nova) (Figure 3) at a frequency of 83.3Hz (5000rpm) and amplitude of 0.4mm (Metzger et al, 2010; Versiani, Pecora, Sousa-Neto, 2011).

Another key advantage of the hollow designed file is that

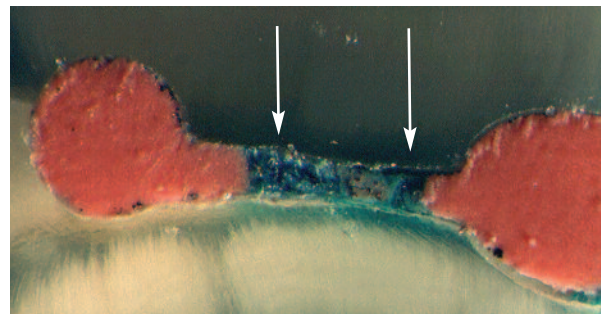


Figure 1: Magnified view of a cross-section of the mesial root canals in an extracted root canal treated molar, using conventional NiTi rotary instrumentation.



Figure 2: The Self-Adjusting File.



Figure 3: The SAF instrument is activated with a transline vibrating handpiece adapted with a RDT3 head.

*Professor Peet van der Vyver, BChD,
Extraordinary Professor, School of Dentistry, University of Pretoria,
South Africa.
Private practice, Sandton, South Africa*



Figure 4: The Vatea electronic irrigation device.

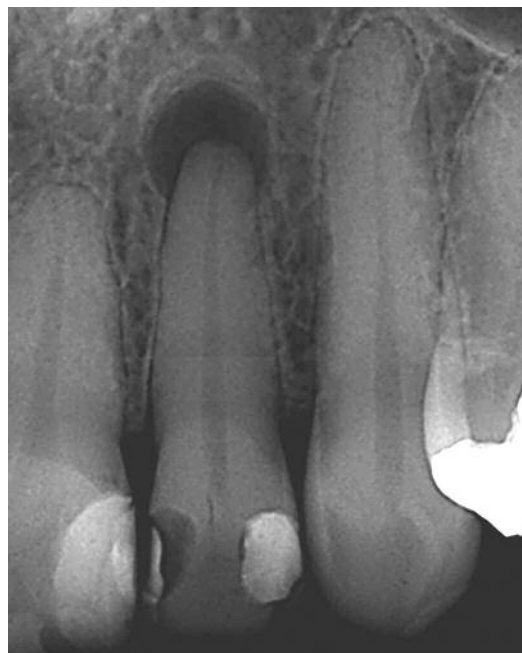

Figure 5: Case one: radiographic examination revealed a large periapical area the around apex of the root and confirmed that the tooth was non-vital.

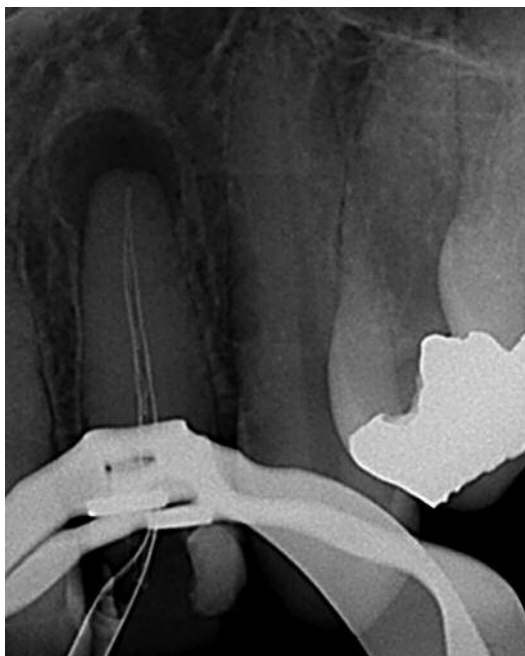


Figure 6: Case one: root canal preparation was done using a Self-Adjusting File (four minutes).

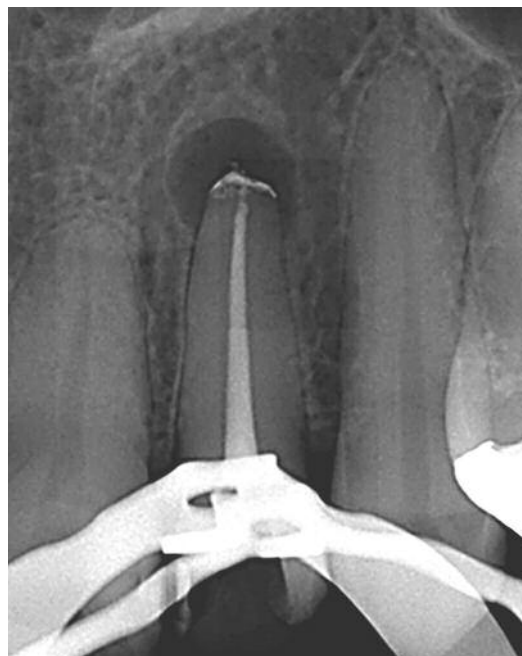


Figure 7: Case one: post-operative result.

it allows for continuous irrigation throughout the procedure. An electronic irrigation device (VATEA, Redent-NOVA) (Figure 4) can be connected directly to the irrigation hub on the side of the file by means of a silicon tube. The irrigation device will deliver the irrigation solution at a very low pressure and the flow rate can be set between 1 and 10ml/min to allow

for safe, continuous irrigation of the root canal system.

Case report one

The patient, a 42-year-old female, presented with discomfort on her upper right lateral incisor. Radiographic examination revealed a large periapical area the around apex of the root

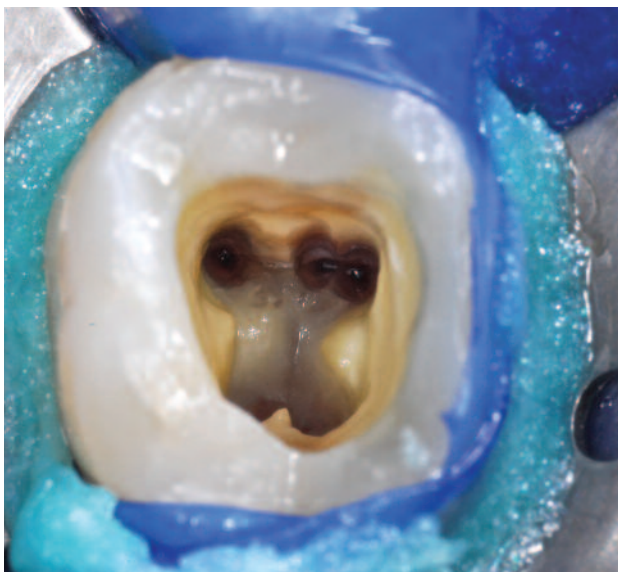


Figure 8: Case two: after access cavity preparation and refinement, three mesial and two distal canals were located.

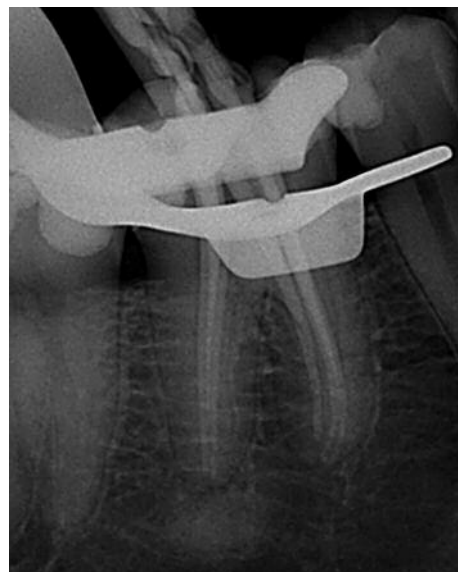

Figure 9: Case two: cone fit.

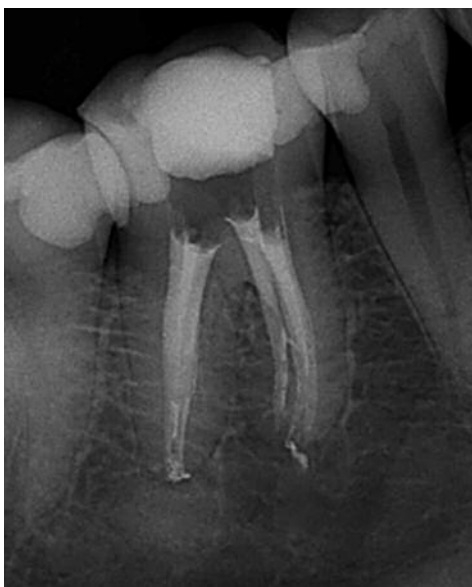

Figure 10: Case two: final result after obturation.

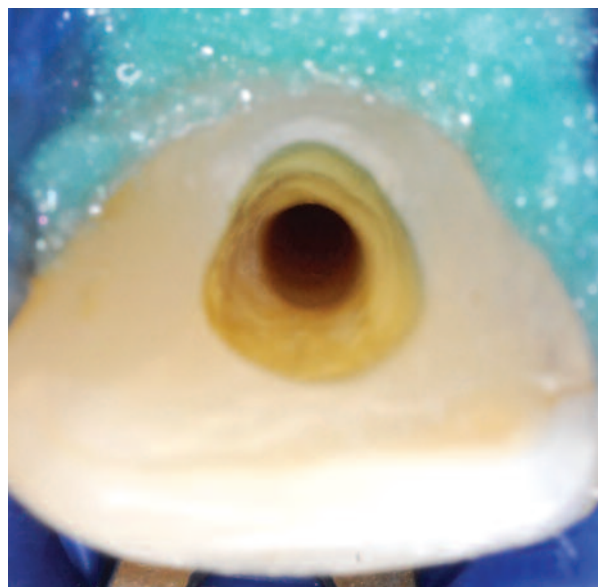


Figure 11: Root canals appear very clean and smooth after preparation with the SAF system.

and confirmed that the tooth was non-vital (Figure 5).

After access cavity preparation and length determination, a glide path was established up to a size 20 K-file. Root canal preparation was done using a Self-Adjusting File (four minutes) (Figure 6) and the Vatea irrigation pump to deliver 3.5% sodium hypochlorite during canal preparation.

Figure 7 demonstrates the post-operative result after obturation with an F3 ProTaper Gutta Percha Cone (Maillefer, Dentply) and Pulp Canal Sealer (Kerr) using Calamus Dual Obturating System (Maillefer, Dentply).

Case report two

A 38-year-old male patient presented with a non-vital lower left first molar. After access cavity preparation and access refinement with Start-X ultrasonic instruments (Maillefer, Dentply) and an X-Gates (Maillefer, Dentply), three mesial and two distal canals were located (Figure 8).

After length determination, a reproducible glide path was established with a size 10 and 15 K-file in a M4 reciprocating handpiece (Kerr). In curved and more complex root canal systems, the author found it valuable to modify the advocated clinical technique for the SAF system

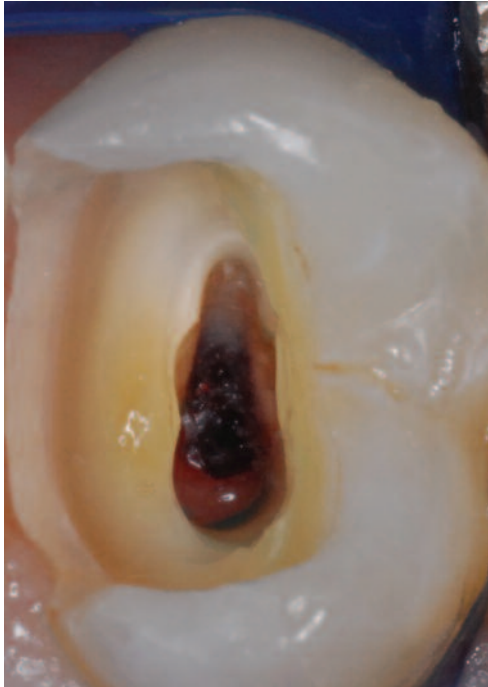


Figure 12: A magnified view of the canal orifice of an upper premolar before root canal preparation.

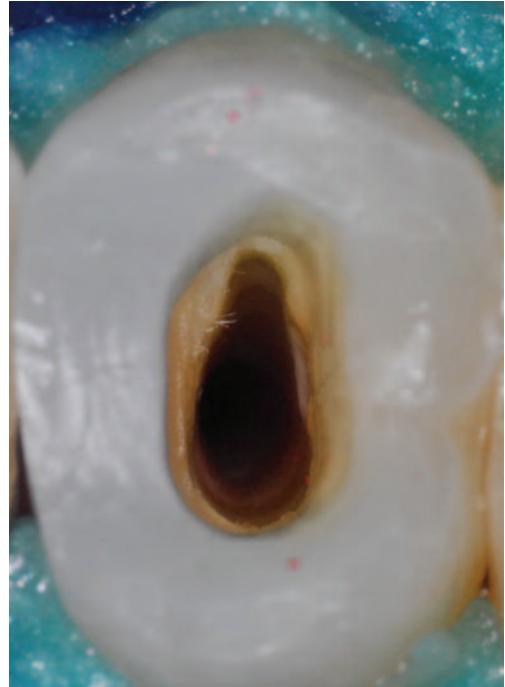
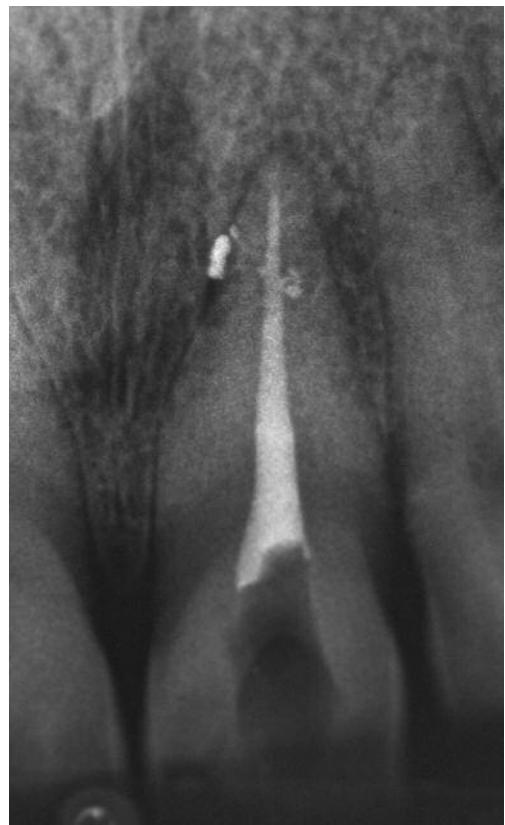
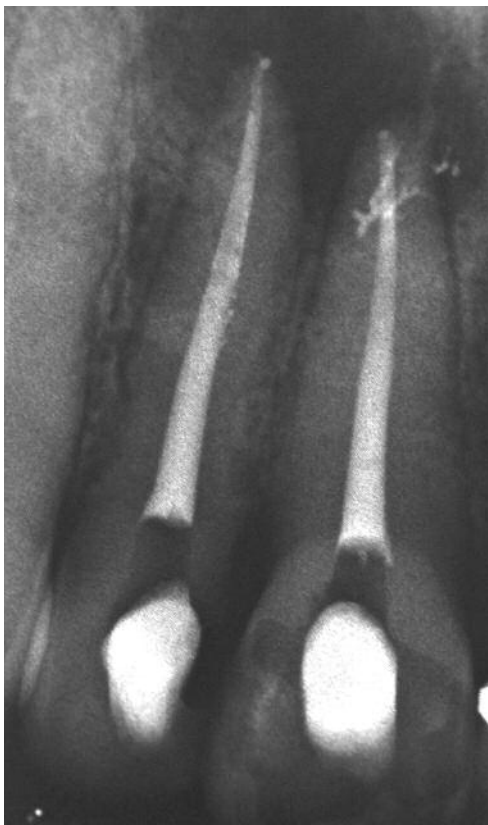Figure 13: The original outline of the canal was maintained after root canal preparation with the SAF system.



Figures 14 and 15: Two cases illustrating root canal preparation done with SAF and obturated with System B Elements (SybronEndo). Note the lateral canals that were visible after obturation.

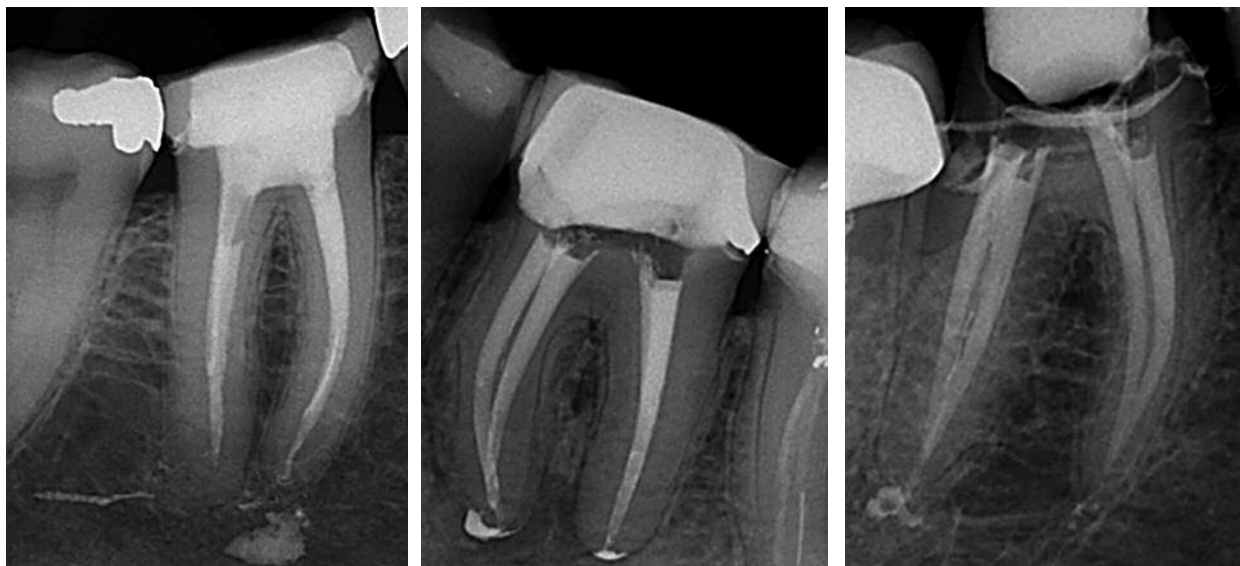


Figure 16: In this case, SAF was used up to working length and upon obturation it resulted in severe cement overfill into the periapical tissues.

Figures 17 and 18: Two cases illustrating ProTaper Universal and SAF used in combination to facilitate root canal preparation, with favorable outcomes.

as described by the manufacturer A ProTaper Universal S1 (Maillefer, Dentsply) instrument was taken to full length in all the root canals using a brushing motion. Thereafter, a Self-Adjusting File with continuous irrigation (3.5% sodium hypochlorite) was introduced and allowed to work its way down the root canal up to 1mm short of working length. Once the file has reached this length, the file was kept there for approximately two minutes to facilitate more shape and allow for the flow of irrigation solution through the root canal system. Final apical shape was achieved by using a F2 ProTaper Universal instrument (Maillefer, Dentsply) up to working length.

After cone fit (Figure 9), obturation of the five root canals were done with F2 Protaper Gutta Percha Cones (Maillefer, Dentsply) and Pulp Canal Sealer (Kerr) using the System B Elements (Kerr) and Obtura (Obtura Spartan). Figure 10 illustrates the final result after obturation.

Clinical findings and recommendations

In the author’s experience, under microscope magnification the root canals appear very clean and smooth compared to conventional rotary instrument preparation (Figure 11).

Original canal anatomy is also maintained. Figure 12 illustrates a magnified view of the canal orifice of an upper premolar before root canal preparation. After root canal preparation with the SAF system it is clearly visible that the original outline of the canal was maintained (Figure 13).

Another frequent finding after using the SAF (either as a single file system or in combination with rotary files as an adjunct for irrigation) is the evidence of lateral canals after

root canal obturation. Figures 14 and 15 show two cases where the root canal preparation was done with SAF and where lateral canals were visible after obturation.

In more complex cases the author finds it advantageous to combine the SAF system with ProTaper Universal. Firstly, the S1 ProTaper Universal file opens the canal to allow faster penetration of the SAF down the root canal. By keeping the SAF short of working length and finishing the last apical millimeter with one of the ProTaper Universal finishing files (F1, F2 or F3 depending on the size of the canal), it provides the clinician with a more predictable cone fit and apical control over obturation materials. Figure 16 depicts a case where the SAF was used up to working length and upon obturation of the root canal system it resulted in severe cement overfill into the periapical tissues. It is also very difficult to obtain excellent tugback with gutta percha cones after the SAF was used up to working length. Figures 17 and 18 illustrate two cases where ProTaper Universal and SAF was used in combination to facilitate root canal preparation as described above, with very favorable outcomes.

References

Metzger Z, Teperovich E, Zary, R Cohen, Hof R (2010) The Self-Adjusting File (SAF): part 1- respecting the root canal anatomy: a new concept of endodontic files and its implementation. J Endod 36: 679-690

Wu M-K, van der Sluis LWM, Wesselink PR (2003) The capacity of two hand instrumentation techniques to remove the inner layer of dentin in oval canals. Int Endod J 36: 218-224

Versiani MA, Pecora JD, Sousa-Neto, MN (2011) Flat-oval root canal preparation with self-adjusting file instrument: A micro-computed tomography study. J Endod 37: 1002-1007