Balance between dental soft tissue and restoration

The factors that influence the contours of the gingival tissue

Shoji Sasaki

When planning to restore a tooth with an aesthetic, naturally shaped dental crown, the age, sex and facial features of the patient as well as the balanced appearance of the crown in relation to the adjacent teeth should be taken into account.

Below, a case will be presented, in which the unfavourable shape and outline of the gingival tissue on an existing restoration was adjusted to match that of the adjacent tooth by utilizing the natural biological ability of the gingiva to adapt to the underlying hard tissues. This objective was mainly achieved by adjusting the cervical portion of the composite core. No further soft tissue therapy was performed.

Case history

The initial examination of the 17-year-old patient revealed a restoration which did not match the adjacent natural dentition in length and shape. Gingival recession was also recorded and unsightly discolorations were visible in the cervical region. Additionally, the left central incisor showed square gingival contours, while those of the right central incisor had a tapered appearance, so that the overall gingival outline did not have a balanced symmetrical look (Figure 1).

Following the removal of the restoration and endodontic treatment, the stained margins were lightened. As sufficient dentin was available to ensure successful further treatment (Figure 2), a glass fibre post was placed and a composite core was fabricated.

Shoji Sasaki, Miyazaki/Japan

Contact address:
Shoji Sasaki
Osaka Ceramic Training Center, Miyazaki School, Sucusesu 90, 6F, 1-7 Ohashi, Japan
Miyazaki-shi, Miyazaki-ken
octc-mi@mx2.wt.tiki.ne.jp

Figure 1: Starting situation.

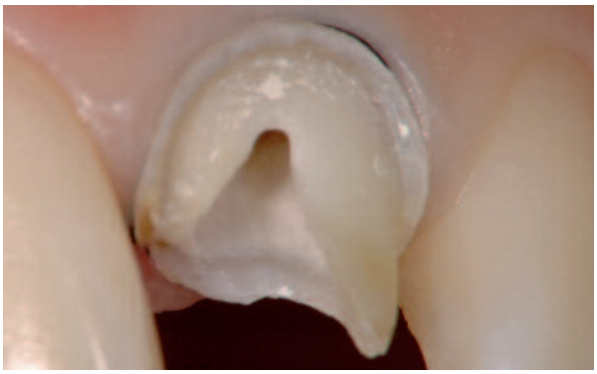

Figure 2: Situation after removal of the restoration and endodontic treatment.

The first provisional

After the first temporary restoration had been placed, the gingival contours on the two central incisors still showed a lack of balance and symmetry. Moreover, the gingival margin on the right side showed a slight taper towards the distal aspect, while the gum line on the left was located 0.5mm lower down with its shape being a symmetrical square type.

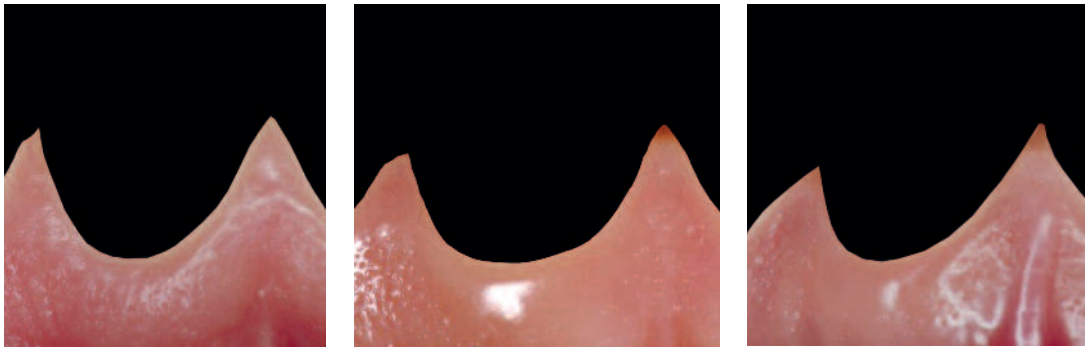

Figures 3a to 3c: Oval, square and triangular shape of the gingival contours.

Natural teeth

An analysis of the gum line of natural teeth showed that the gingival contour is largely influenced by the shape of the dental alveolus. Therefore, the core buildup on the left central incisor was optimized to ensure a gingival taper towards the distal aspect which would achieve the desired shape (Figures 3a to 3c).

Design of the core build-up

Figure 4 shows the criteria that apply in the shaping of core build-ups for maxillary central incisors. The graphic illustrates the basic concept involving three axial planes shown from a mesial and distal direction.

Basic points

a. In the vestibular region, the gingival margin runs nearly parallel with the largest labial extension of the maxillary central incisor crown.
b. On the lingual aspect, the gingival outline follows the curvature of the lingual surface.
c. The labial contour of the dental alveolus runs almost parallel with the longitudinal axis of the tooth.

The core build-up should feature a shape similar to that of the final restoration (Figure 5).

The second provisional

The temporary restoration or its subgingival contour on the distal aspect (Figure 6) showed a slight bulge and thus supported the gingival tissue from the inside. The mesial side was located close to the gum line and demonstrated a smooth transition (Figure 7).

There was no indication of an inflammation and the course of the gingival margin was adjusted in a biologically acceptable way by modifying the shape of the composite core below the gum line (Figure 8).

Shade selection

The shades A2, A1 and A3 from the IPS e.max® range were selected. In order to be able to determine the appropriate shade, the shades and hues of the substructure need to be taken into account. When building the crown, the final shade is achieved by layering different powders in a certain sequence. As a result, the intensity and translucency of the shades have to be taken into consideration (Figures 9 and 10).

Ceramic layering

The appropriate dentin shade is attained by selecting the dentin shade with the next higher shade value and by subsequently adjusting the brightness value with stains. Following the application of Essence materials in the cervical region and further characterizations, the restoration was fired (Figure 11).

After completion of the firing cycle, the surface is moistened with IPS e.max Ceram Glaze and Stain Liquid and shade A2 Deep Dentin powder is sprinkled over it. A thin layer of liquid creates an even surface for the application of the powder.

A section of a natural tooth (1mm in width) was reproduced with IPS e.max Ceram. Figure 12 shows the IPS e.max Ceram section in incident light, in transmitted light and in fluorescent light, while on the far right, a natural tooth section in fluorescent light can be seen. The cervical region and the mamelons of the natural tooth section show opaque areas which block the passage of light, whereas in the ceramic specimens, the same phenomenon is not as distinct. Consequently, it is recommendable to add a more opaque material to the highly translucent, ceramic dentin material when modelling the cervical region. The

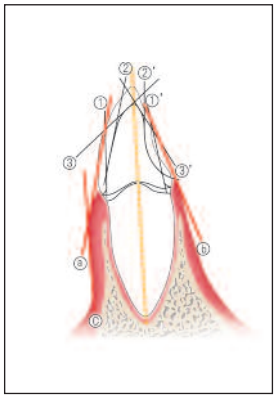

Figure 4: Parameters for the shaping of the core build-up.

Figure 5: The shape of the core reflects the reduced tooth shape.

Figure 6: The subgingival shape of the second provisional.



Figure 7: Graphic representation of the mesial aspect.

Figure 8: Biologically acceptable adjustment.

dull, opaque shade may be modified by adding IPS e.max Ceram Deep Dentin A2 and Occlusal Dentin (orange) (Figure 13). The shape of the dentin layer defined during shade determination is reproduced.

The translucent dentin structure is disregarded during shade selection. Building up the surface layer directly is easier than using the cut-back technique (Figure 14). Following this, the translucent enamel layer is built around the reduced dentin portion like a frame (Figures 15 and 16). To achieve a natural-looking light diffusion effect, alternating layers of translucent and opaque materials are placed. This technique can also be used when applying Essence materials internally. If only one shade is used, the same effect can be achieved by applying a crack line.

In the cervical region, a mixture of Cervical Transpa (orange-pink) and Transpa Incisal (1) is applied to achieve

Figure 9: The natural model.

Figure 10: Graphic representation of the different layers.

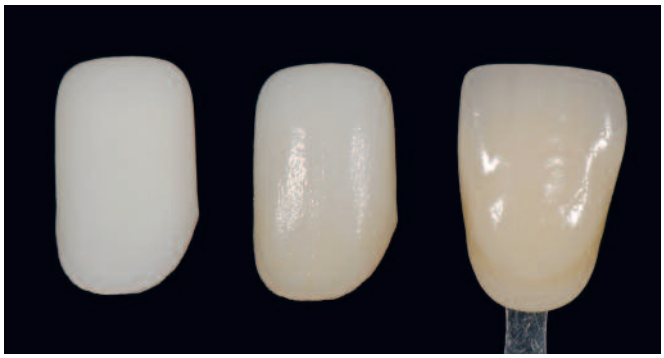

Figure 11: IPS e.max Press coping prepared for Dentin application.

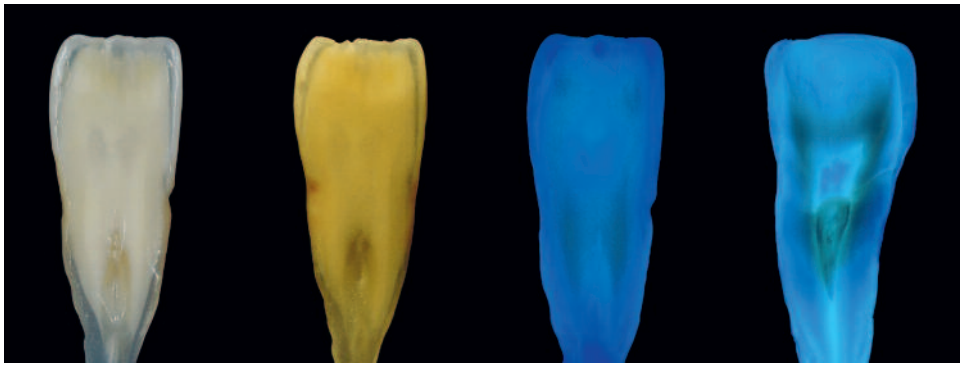

Figure 12: Sections showing the light optical properties.

Figure 13: Opaque mixture applied in the cervical region.

Figure 14: Direct build-up of the dentin core.

the desired depth effect. The shade value of the distal and mesial ridges is slightly higher, so that Opal Effect 2 and Opal Effect 3 are mixed at a ratio of 1:1. The white spot at the distal edge was reproduced with Opal Effect 2 material, which was complemented with a small amount of white Essence material (Figure 17).

Tooth shape

The labial structure is determined by three elements: the cervical line, the median line and the incisal line. Due to the crown angle, the three labial planes can be precisely defined. Additionally, the convex and concave zones can be determined (Figures 18a to 18c).

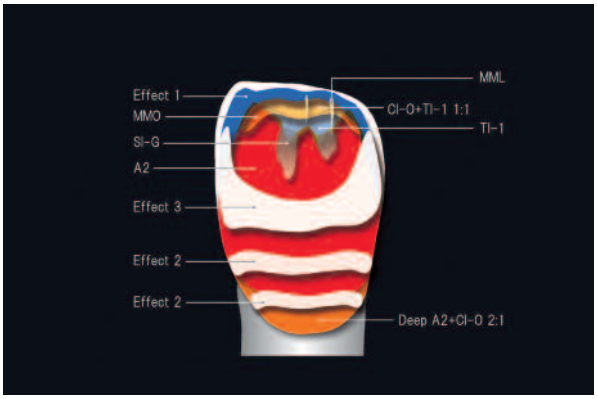

Figure 15: Schematic representation of the enamel.

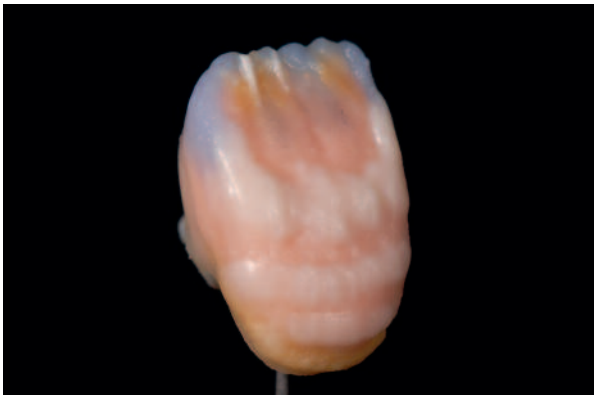

Figure 16: The layered restoration layer.

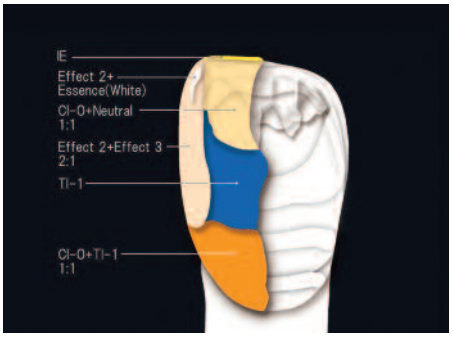

Figure 17: Schematic representation of the differently shaded enamel portions.

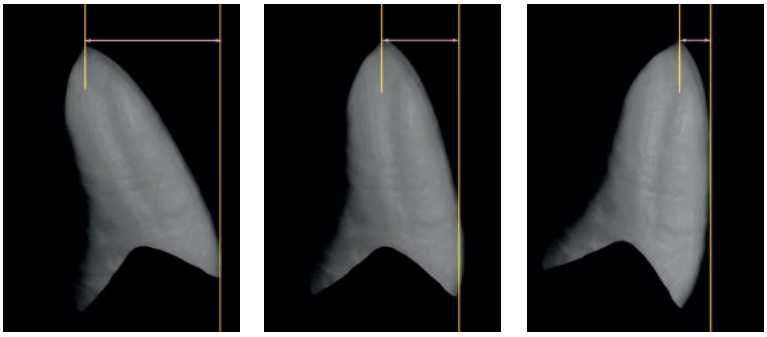

Figure 18a to 18c: Determination of the labial surfaces.

Summary

This case shows that the design of the core build-up decisively influences the gingival contour. The position and the subgingival contours of the periodontal tissue as well as the preparation limits need to be carefully defined to meet the biological requirements. The anatomical shape and subgingival contours achieved by a reduction in the curvature of the second temporary ensure a smooth transition to the gingival tissue (Figures 19 to 21).

Reprinted with permission of Reflect 02/08

Figure 19: Final situation.

Figure 20: IPS e.max Press – smooth transitions ...

Figure 21: ... similar to those of the natural model.