Evaluation of bone thickness for inserting mini-screws in inter-radicular sites

TIZIANA DOLDO, ANTONIO COSTA, VALERIA VESSIO, ANTONIO FAZZARI

Abstract

Objectives: The aim of the present study was to determine safe areas for inserting miniscrews in inter-radicular sites, in relation to the movement of the operator's hand with respect to the bone cortex during placement of miniscrews.

Methods and Materials: Twenty skulls of white males, age 20-50 years with complete dentition, were selected; the teeth were extracted in order to measure bone thickness. Areas with bone thickness of more than 3.5 mm (initial linear measurement) were then measured in angular terms by tomographic examination. Linear and angular measurements of inter-radicular spaces were taken.

Results: The greatest thicknesses measured in the vestibulopalatal direction were at apical level between the first and second molars of the upper arch and of the mandible. In the upper arch, the greatest inter-radicular mesiodistal bone thicknesses were found on the palatal side between the root of the second premolar and the root of the first molar at coronal level. A good quantity of bone was also observed at middle and apical levels between the two central incisors and between the first and second molar. In the lower arch, significant bone thicknesses were found at almost all apical levels in posterior sectors distally from the lateral incisor to the second molar. The area where the greatest range of inclination of the hand is possible in the axial plane, is between the palatal root of the first upper molar and the root of the second upper premolar at middle level, where the angle calculated was 50°. Another wide angle (30°) was calculated between the roots of the incisors.

Conclusions and significance: The results of our study show that insertion of microscrews is limited by insufficient mesiodistal bone thicknesses. Besides safe areas, we identified those which were borderline where screws can only be inserted with maximum operator precision.

Key Words: orthodontics, minisrews, anchorage

Introduction

Anchorage control is a critical step in orthodontics and a major aspect of orthodontic biomechanics. Different extradental anchorage strategies, such as implants, miniplates and zygoma ligatures have been introduced[1]. However, limitations of these methods, such as poor compliance, high cost and tooth movement, have prompted orthodontists to resort to miniscrews[2], which are modified orthopedic screws. Miniscrews have been found to successfully withstand orthodontic forces[3-6]. Their advantages include low cost, patient comfort, easy insertion and removal, shorter treatment times, immediate loading, fewer complications, complete recovery and restoration of function [7-11]. Many extra- and intra-alveolar sites have been proposed for miniscrew anchorage [12-15]. In our experience, the reduced size of the screws enables them to be inserted in inter-radicular sites: in extreme cases inclining the screw in the apical direction so as to prevent damage to the roots of adjacent teeth. Although different placements and insertion methods have been proposed for miniscrews, there have been few detailed assessments of inter-radicular areas also including clinical variables that could guide orthodontists during insertion of miniscrews, preventing damage to the adjacent root.

Department of Orthodontics, University of Siena, Italy
Corresponding Author
Prof. Tiziana Doldo
Dipartimento Scienze Odontostomatologiche Università di Siena
Policlinico S.Maria alle Scotte
53100 Siena, Italy
Tel-fax +39 0577 233412
Mail to: doldo@unisi.it

Materials and methods

Twenty skulls of white males, age 20-50 years, with complete dentition and good maxillary relationships were selected from the laboratory of the Institute of Human Anatomy of Siena University. The teeth were extracted in order to measure bone thickness. Linear measurements were made with two Mitutoyo type digital callipers, resolution 0.00l mm, error ± 0.001 mm, range 0-150 mm (Fig. 1). The calliper arms were modified to enable measurements in inaccessible places such as alveolar apices.

Areas with bone thickness of more than 3.5 mm (initial linear measurement) were then measured in angular terms by tomographic examination in 20 males, 20-50 years of age with complete dentition and good maxillary relationships. Tomography was performed with a Newton 3G volume scanner by cone-shape X-ray beam technique [16-18] in high-



Figure 1: Mitutoyo type digital calliper used to measure: a) mesiodistal and b) vestibulopalatal distances.

resolution mode (110 KV, tube current 3.9 mA, dose 3.47 mGy, exposure time 7.2 s, slice thickness 0.3 mm).

Linear measurements

Two series of measurements were made on the skulls, one in the mesiodistal and the other in the vestibulopalatal direction, at three depths:

Mesiodistal measurements:

- coronal third: the reading was taken 3 mm under the alveolar bone margin (Fig. 2A)
- middle third: the reading was made using a paper cone inserted in the deepest part of the alveole. Half this measurement was marked on the external side of the jaw to determine bone thickness at the mid point of the alveole (Fig. 2B)
- apical third: the reading was taken at the apex of the alveole (Fig. 2C).

Vestibulopalatal measurement: vestibulopalatal bone thickness was again measured coronally, medially and apically. The coronal and apical measurements were similar to those described for the mesiodistal spaces (Fig. 3A and C). The middle level was assessed using a paper cone to determine half depths of adjacent alveoles. These points were marked on the cortex and their mean point was the level at which the measurement was taken (Fig. 3B).

The means and standard deviations of the measurements were calculated to define the significance of the values. The mean was the algebraic sum of the measurements divided by the number of measurements, to give a general idea of the order of magnitude of quantitative measurements and their variability in the population represented by the sample [19]. The standard deviation represented the width of the distribution of measures.

Angular measurements

Angular measurments were made using R NNT version 2.0 software only in areas of interest, namely those found to have bone thickness > 3.5 mm by the previous linear measurements, in order to define the limits of operator hand movements with respect to the bone. Reconstruction of the tomographic images was obtained in the occlusal plane. Axial cuts were made at the same levels as the mesiodistal measurements (coronal, middle, apical). The angles were calculated using the "show angle" toolbar function of the software. The angle vertex was located at the midpoint of the distance between two adjacent roots on the external bone cortex, whereas the was limited by the need to maintain a safe distance of 1 mm between the root and the micro-implant.



Figure 2: a) Coronal, b) middle and c) apical mesiodistal measurements.



Figure 3: a) Coronal, b) middle and c) apical vestibulopalatal measurements.

Results

The measurements of the inter-radicular spaces of the upper and lower jaw are shown in Tables 1 and 2. The greatest thicknesses measured in the vestibulopalatal direction were 13.52±1.23 mm (mean ± SD) and 13.16±1.76 mm at apical level between the first and second molars of the upper arch and of the mandibula, respectively. Significantly less bone thickness was found at apical level between the upper lateral incisor and canine and at apical level between the two central lower incisors.

In the upper arch, the greatest inter-radicular mesiodistal bone thicknesses were found on the palatal side between the root of the second premolar and the root of the first molar at coronal, middle and apical levels (5.21±0.74 mm; 6.47±0.68 mm; 8.36±0.79 mm, respectively). On the vestibular side, in the same area, it was difficult to find such thicknesses due to the large mesiovestibular root of

Table 1
Intra-alveolar mesiodistal thickness

		Superior Arch			Inferior Arch		
		1/3 Coronal	1/3 Middle	1/3 Apical	1/3 Coronal	1/3 Middle	1/3 Apical
1-1	***Mean***	***1.11***	***3.76***	***6.12***	***1.00***	***2.21***	***3.41***
	Minimum	2.32	5.99	8.59	3.00	5.87	7.28
	Maximum	0.27	1.30	3.07	0.17	0.81	1.24
	S.D.	0.86	1.48	1.53	0.76	1.14	1.45
1-2	***Mean***	***1.08***	***1.92***	***2.94***	***0.72***	***1.63***	***2.65***
	Maximum	3.51	4.12	4.64	1.53	3.47	4.17
	Minimum	0.23	0.76	1.30	0.24	0.62	1.13
	S.D.	1.37	0.75	0.93	0.31	0.69	0.80
2-3	***Mean***	***1.63***	***2.50***	***2.96***	***0.79***	***1.77***	***3.76***
	Maximum	2.13	4.36	9.60	1.68	2.89	5.80
	Minimum	0.53	0.68	0.51	0.25	0.58	0.97
	S.D.	2.02	1.02	1.38	0.38	0.64	1.24
3-4	***Mean***	***1.06***	***2.36***	***3.45***	***0.80***	***2.17***	***3.98***
	Maximum	5.00	3.91	5.21	1.81	3.31	6.08
	Minimum	0.28	0.86	1.09	0.10	0.64	1.22
	S.D.	1.05	0.75	1.04	0.50	0.66	0.82
4-5	***Mean***	***1.13***	***2.16***	***3.45***	***1.11***	***3.55***	***4.12***
	Maximum	3.19	4.20	6.63	2.73	4.64	6.08
	Minimum	0.32	0.71	1.05	0.23	0.86	1.94
	S.D.	0.83	1.14	1.85	0.72	1.07	1.16
5-6	***Mean***	***1.16***	***2.24***	***3.38***	***1.56***	***2.60***	***4.38***
	Maximum	4.57	4.46	5.28	6.83	6.50	7.61
	Minimum	0.33	0.82	0.79	0.24	1.01	1.67
	S.D.	0.95	0.85	1.89	1.70	1.28	1.69
6-7	***Mean***	***1.22***	***2.74***	***4.60***	***1.38***	***2.84***	***4.59***
	Maximum	2.37	5.83	7.08	2.37	4.91	7.28
	Minimum	0.28	1.21	1.05	0.33	0.53	1.13
	S.D.	0.86	1.32	1.86	1.17	1.35	1.85
5-6	***Mean***	***5.21***	***6.47***	***8.36***	***1.56***	***2.60***	***4.38***
	Maximum	6.26	7.82	10.17	6.83	6.50	7.61
	Minimum	3.87	5.20	7.18	0.24	1.01	1.67
	S.D.	0.74	0.68	0.79	0.70	1.28	1.60
6-7	***Mean***	***1.12***	***2.74***	***4.60***	***1.38***	***2.84***	***4.59***
	Maximum	5.42	6.54	7.01	2.37	4.91	7.28
	Minimum	0.32	0.99	1.21	0.33	0.53	1.13
	S.D.	0.58	0.77	0.84	1.17	1.35	1.85

the first molar, which limited space for screw placement. A good quantity of bone was also observed at middle and apical levels between the two central incisors (3.76±1.48 mm; 6.12±1.53 mm, respectively) and between the first and second molar (4.60±1.86 mm).

In the lower arch, significant bone thicknesses were found at almost all apical levels in posterior sectors distally from the lateral incisor to the second molar; a palatal miniscrew site could be between the two premolars at middle level where a suitable thickness of bone was found (3.63±1.1 mm). In the mesiodistal direction, the greatest bone thickness was found at apical level between the two premolars and the two molars (4.12±1.16 mm and 4.59±1.85 mm, respectively). However, moderate mesiodistal thicknesses were also observed at all apical levels in the posterior sector (from the lateral incisor to the second molar). In this case, the mesiodistal palatal measurements were similar to the vestibular measurements.

The possible angles calculated for insertion of screws are illustrated in Table 3. They show that the area where the greatest range of inclination of the hand is possible in the axial plane is between the palatal root of the first upper molar and the root of the second upper premolar at middle level, where the angle calculated was 50°. Another wide angle (30°) was calculated between the roots of the incisors.

Discussion

Correct analysis of inter-radicular spaces for insertion of miniscrews involves comparing bone thickness data with miniscrew diameters and the presence of anatomical structures to be avoided. Areas with mesiodistal thicknesses greater than 3.5 mm were examined in detail to avoid damage to nerve and vascular bundles. We also investigated whether certain anatomical structures made certain areas unsuitable sites for microimplants. The areas rejected were:

Upper arch

- apical level between first and second molar on vestibular side, due to risk of perforating the maxillary sinus, since bone cortex thickness is unpredictable in this area;

Table 2
Intra-alveolar mesiodistal thickness

		Superior Arch			Inferior Arch		
		1/3 Coronal	1/3 Middle	1/3 Apical	1/3 Coronal	1/3 Middle	1/3 Apical
1-1	***Mean***	***6.61***	***7.89***	***8.87***	***5.47***	***7.27***	***9.34***
	S.D.	1.45	1.33	1.76	0.89	0.74	0.96
1-2	***Mean***	***6.20***	***7.33***	***8.87***	***6.86***	***7.61***	***9.05***
	S.D.	1.57	1.31	1.39	0.71	0.59	0.92
2-3	***Mean***	***5.95***	***6.90***	***9.15***	***7.31***	***8.52***	***9.46***
	S.D.	0.85	0.84	1.01	1.11	1.13	1.01
3-4	***Mean***	***8.03***	***8.69***	***9.79***	***8.47***	***9.54***	***10.44***
	S.D.	0.97	0.81	0.85	1.28	1.20	1.23
4-5	***Mean***	***8.00***	***8.94***	***10.37***	***7.61***	***9.40***	***10.29***
	S.D.	1.06	1.05	1.19	1.90	1.70	1.52
5-6	***Mean***	***10.49***	***11.53***	***12.79***	***9.75***	***10.80***	***11.50***
	S.D.	1.61	1.50	1.43	1.08	1.75	1.56
6-7	***Mean***	***11.32***	***12.44***	***13.52***	***10.37***	***12.10***	***13.16***
	S.D.	0.93	1.22	1.23	1.25	1.50	1.76

- apical level between the two central incisors on the palatal side due to difficulty of working in this area;
- apical level between the second premolar and the first molar on the palatal side since the nerve-vascular bundle of the palate lies 12±5 mm [20] from the amelodentine junction.

Lower arch

- apical level between the first and second premolars due to presence of the foramen mentalis;
- all apical sites on the palatal side due to presence of sublingual artery and vein and to risk of perforating the mouth floor.

Bone thickness in the vestibulopalatal direction in most cases offers sufficient space for microscrews. In extreme cases, the screw can always be inclined in the direction of the thickest area. In the literature [21-24], insertion of miniscrews having bone portions 5, 7, 9 and 11 mm in length are described. Insertion of screws not perpendicular to the tooth, for example at 120-130° with respect to the major axis of the latter, enables the space occupied by the screw to be reduced by 25-30%.

On the other hand, mesiodistal bone thicknesses do not offer sufficient bone and restrict operator movements, calling for maximum attention to avoid damaging adjacent roots. Our results show that the insertion angles of less than 8° shown in Table 3 are not safe zones because screw inclination has to be extremely precise. These areas should be regarded as risky. Anatomical sites enabling a range of 8-30° are regarded as borderline and success of screw insertion will depend on operator expertise (areas of maximum precision). Areas with freedom of movement exceeding 30° can be considered safe. Figure 4 shows safe areas in green, borderline in yellow and unsuitable areas in red.

To maintain periodontal hygiene of adjacent teeth and to facilitate primary stability of the miniscrew, the latter should be inserted in inter-radicular areas that offer a bone thickness of at

Table 3
Range of inclination of operator's hand

		Superior Arch			Inferior Arch		
		1/3 Coronal	1/3 Middle	1/3 Apical	1/3 Coronal	1/3 Middle	1/3 Apical
Vestibular side							
1-1	***Mean***	-	***3°***	***30°***	-	-	-
1-2	***Mean***	-	-	-	-	-	-
2-3	***Mean***	-	-	-	-	-	***2.20°***
3-4	***Mean***	-	-	-	-	-	***4.20°***
4-5	***Mean***	-	-	-	-	-	-
5-6	***Mean***	-	-	-	-	-	***11°***
6-7	***Mean***	-	-	***9.5°***	-	-	***8°***
Palatal side							
1-2	***Mean***	-	***3°***	-	-	-	-
2-3	***Mean***	-	-	-	-	-	-
3-4	***Mean***	-	-	-	-	-	-
4-5	***Mean***	-	-	—	-	***20°***	-
5-6	***Mean***	-	***50°***	-	-	-	-
6-7	***Mean***	-	-	-	-	-	-

***Figure 4:** Mesiodistal bone thicknesses of the dental arches. Safe areas for miniscrew insertion are shown in green, borderline areas in yellow and unsuitable areas in red.*

least 1 mm between the screw and the root.

Note that our assessment concerns an ideal situation, since the skulls and tomographies belonged to subjects with all their teeth and good maxillary relationships. Loss of a tooth, inflammation or malocclusion with crowding may vary the values calculated in the present study. In clinical situations, the intra-alveolar areas found suitable for miniscrew insertion may be less favourable. Moreover, in our assessment we did not consider inter-radicular spaces in the coronal third since periodontal and endodontal problems and loss of teeth may lead to bone resorption, altering bone thickness in this area. In some cases, endodontic complications may cause problems at this level.

Conclusions

The results of our study show that insertion of microscrews, with regard to the possible complication on root surfaces, is limited by insufficient mesiodistal bone thicknesses. Areas that can be considered the safest for intra-alveolar insertion of microimplants are:

• upper arch on vestibular side between the two central incisors at apical level. Here the operator's hand can vary in inclination through 30° in the axial plane (Figs. 4A and 5A);

• upper arch on palatal side – interadicular space at middle level between the second premolar and the first molar. Here, the operator's hand may vary in inclination through 65° in the axial plane. The wide angle possible in this area enables sufficient freedom of movement of the hand from the second contralateral premolar to the posterior teeth (Figs. 4B and 5B). When possible, it is advisable to insert microimplants in extra-alveolar areas which are stable and less subject to clinical variations.

Besides safe areas, we identified those which were borderline where screws can only be inserted with maximum operator precision. These areas are:

• upper arch on vestibular side between the two molars at apical level, where angle may vary by 9° (Figs 4C and 5C);

• lower arch on vestibular side between the two molars and between the second premolar and the first molar at apical level. The freedom of movement of the operator's hand in these areas is 8° and 11.5°, respectively (Fig. 4C and 5D);

• lower arch on palatal side between the two premolars at middle level. In this area the operator's hand has freedom of movement of about 20° in the axial plane. This enables the operator to use the screwdriver distally from the area between the second premolar and the first molar, as far as the second contralateral molar (Figs. 4D and 5E).

References

1. Melsen B, Bosch C. *Different approaches to anchorage: a*

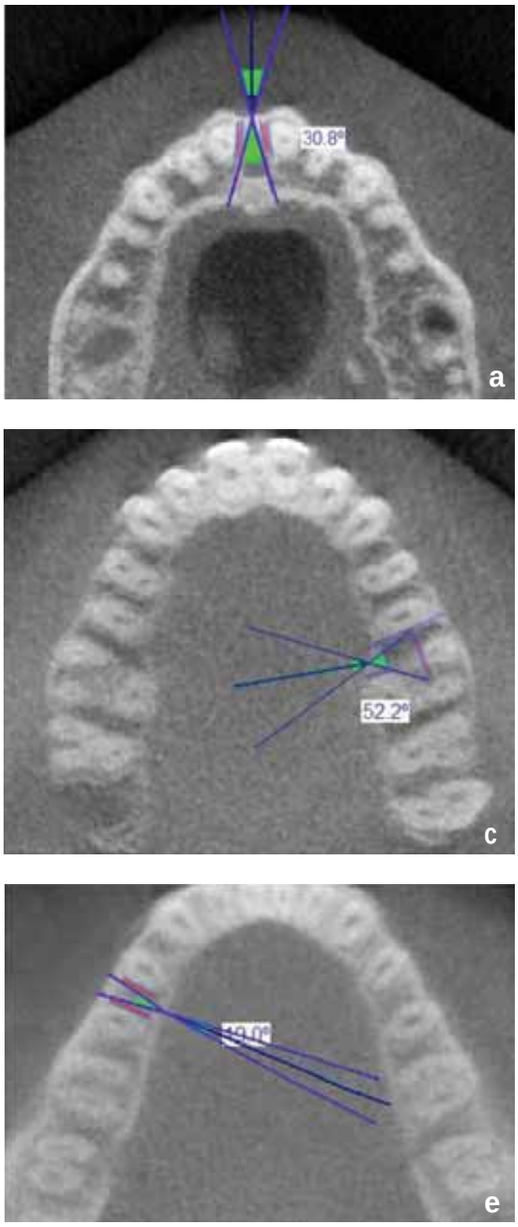

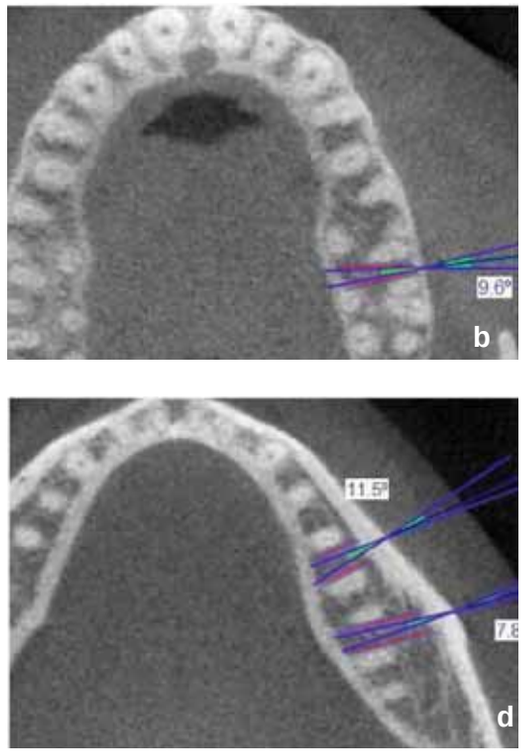

Figure 5: Miniscrew insertion angles calculated by computed tomography.

survey and an evaluation. Angle Orthod. 1997; 67 (1): 23-30;

2. Carano A, Velo S, Leone P, Siciliani G. *Clinical applications of the miniscrew anchorage system*. J Clin Orthod. 2005; 39: 9-24;

3. Block MS, Hoffman D R. *A new device for absolute anchorage for orthodontic.* Am J Orthod Dentofac Orthop. 1995; 107: 251-258;

4. Costa A. *Gli impianti come ancoraggio ortodontico*. Atti Relazioni Sido. 2000;

5. Costa A, Dalstra M, Melsen B. *The Aarhus Microanchorage System*. Atti XV Congresso Internazionale SIDO. Roma. 1999;

6. Travess HC, Willams PH, Sandy JR. *The use of osseointegrated implants in orthodontic*. Absolute anchorage. Dent. Update. 2004. Jul-Aug; 31 (6): 355-6. 359-60. 362;

7. Melsen B, Petersen JK, Costa A. *Zygoma ligatures: an alternative form of maxillary anchorage*. Clin OrthoD. 1998 Mar.; 32 (3): 154-8;

8. Keles A, Erverdi N, Sezen S. *Bodily distalization of molars with absolute anchorage*. Angle Orthod. Aug 2003; 73 (4): 471-482;

9. Sugawara JI, Daimaruya T, Unemori M, Nagasaka H, Takahashi I, Kawamura H, Mitani H. *Distal movement of mandibular molars in adult patients with the skeletal anchorage system*. Am J Orthod Dentofacial Orthop. Feb 2004; 125 (2): 130-138;

10. Umemori M, Sugawara J, Mitami H, Nagasaka H, Kawamura H. *Skeletal anchorage system for open-bite correction*. Am J Orthod Dentofacial Orthop. Feb 1999; 115 (2): 166-74;

11. Bae SM, Park HS, Kyung HM, Sung JH. *Ultimate anchorage control*. Tex Dent J. Jul 2002; 119 (7): 580-91;

12. Carano A, Velo S, Incorvati C, Poggio P. *Clinical applications of the Mini-Screw-Anchorage-System (M.A.S.) in the maxillary alveolar bone*. Prog Orthod. 2004; 5 (2): 212-35;

13. Park Y, Lee SY, Kim DH, Jee SH. *Intrusion of posterior teeth using mini-screw implants*. Am J Orthod Dentofacial Orthop. 2003; 123: 690-694;

14. Park HS, Kyung HM, Sung JH. *A single method for molar uprighting with microimplants anchorage*. J Clin Orthod. 2002; 36: 592-596;

15. Kanomi R. *Mini-implant for orthodontic anchorage*. J Clin Orthod. 1997; 31: 763-767;

16. Siwerdsen JH, Jaffnay DA. *Cone-beam computed tomography with a flat-panel imagery*. Med Phys. 26: 2635-47. 1999;

17. Mozzo P, Procacci C, Tacconi A et al. *A new volumetric CT machine for dental imaging based on the cone-beam technique: preliminary results*. Eur Radio. 18: 1558-64. 1998;

18. Hassfeld S, Streib S, Stahl H, et al. Low-dose-computertomographie des kiefernochens in der praimplantologischen. Diagnostik Mund Kefer Gesichss Chir 2: 188-193. 1998

19. Petee A, Geoffrey B. *Statistica Medica. Metodi statistici per la ricerca in medicina*. 3° edizione. ed. it. a cura di Mario Bolzan. McGraw-Hill;

20. Nawarat Wara-aswapati, Waranuch Pitiphat, Neerapa Chadrapho, Charunee Rattanayatikull, and Nadeem Karimbus. *Thickness of palatal masticatory mucosa associated with age*. J. Periodontol October. 2001; 72: 1407-1412;

21. Sherwood KH, Burch JG, Thompson WJ. *Closing anterior open bites by intruding molar with titanium miniplate anchorage*. Am. J Orthod. 122: 593-600. 2002;

22. Werhbein H, Merz BR. *Aspect of the use of endosseous palatal implants in orthodontic therapy*. J. Esth Dent. 199; 10: 315-324;

23. Costa A. *Ancoraggio a vite con impianti a vite nella terapia ortodontica*. Mondo Ortodontico. 6/2001. pp 481-488;

24. Costa A, Levrini L, Tagliabue A. *Implant osteointegration for orthodontic anchorage*. Italian Journal of Oral Implantology. Vol 2. 3 2000. pp 133-139.

Geistlich Biomaterials

Bio-Oss® collagen

Bio-Oss®- The Leading bone substitute of natural origin - has been proven in clinical use for over 20 years.

In collaboration with over 100 universities and the best dental surgeons, Bio-Oss® is used, tested and developed in the most varied indications. Outstanding results with Bio-Oss® are documented in more than 500 studies - and this number is increasing constantly. Bio-Oss® is regarded as the standard material in dental bone regeneration.

IMPLANTS FOR AFRICA
UNIT 30B, PLATINUM JUNCTION BUSINESS PARK,
SCHOOL ROAD, MILNERTON 7441
Tel: 021 552 0889 • Fax: 021 552 6885
Email: ifa@mweb.co.za • Website: implants4africa.co.za
Brett: 072 245 7021 (KZN)
Brian: 082 456 2154 (W.Cape & Gauteng)