

Apical seal versus coronal seal

Pierre Machtou

Introduction

The biological basis of endodontics is well established and underlines the dominant role of bacteria in the initiation, development and persistence of periapical disease (Kakehashi S et al, 1965) or apical periodontitis (AP) according to the terminology currently in use. The aim of clinical procedures is to prevent or eliminate bacterial infection from the root canal system (Orstavik D, Pitt-Ford TR, 1998). For many years, inadequate obturation of the root canal was widely accepted as the cause of continuing endodontic infection (Figure 1). However, more recently attention has focused on the lack of effective sealing of the coronal restoration after endodontic treatment and the impact of this on the ultimate outcome. The current dilemma is based on ascertaining which of these two factors is the predominant cause of endodontic failure (Sriharan A, 2002) because the literature is abundant on each of these two issues and is dogged by controversy.

Apical seal

For some time now it has been accepted that the 'triad' of preparation, disinfection and canal obturation is the key to success in endodontics. However, in the past a significant share of this 'triad' was allocated to the filling stage, especially after the 'hollow tube' theory was suggested by Rickert and Dixon (1931) and this remained accepted philosophy for 30 years.

To explain the presence of periapical lesions in badly sealed teeth, along with voids in the apical area, small tubes of hypodermic needles were implanted in rabbits' backs. Following an undefined postoperative period, the tissue reaction around the tubes was examined microscopically. Significant inflammation was visible, particularly around the lumens of the tubes, leading the authors to conclude that 'the elements circulating through the lumen of the tubes were not tolerated by the living tissues'. Following a similar protocol, placement of extracted sealed and unsealed

sterile teeth in the skin or muscles of a rabbit corroborated the results of the initial study. It was concluded that the apical fluids, with their primary source being blood serum, diffuse into the empty canal spaces, stagnate, undergo degradation and then act as a physicochemical irritant when they diffuse back into periapical tissues.

In support of this theory of stagnation, in 1955 Dow and Ingle showed that the majority of the endodontic failures were the result of inadequate or incomplete obturation of the canal space. Indeed, after having immersed extracted sealed teeth in a radioactive iodine solution, the well-sealed teeth did not suffer any penetration from radiographic isotopes. Conversely, massive penetration was observed in the teeth where obturation was defective. This *in vitro* study established that the situation was similar to that found *in vivo*, thus confirming the hollow tube theory.

A study of treated cases was undertaken at the University of Washington to evaluate success and failure rates over a two-year period. The study also assessed the various factors related to the failures. This study was published for the first time in 1965 in *Endodontics*, then systematically reviewed in all later editions of the work (2002). The most striking aspect of the study was a reported failure rate of 58% to 66% due to incomplete obturation of the canal. Although similar to Strindberg's first study (1956) on the same aspect of failure but demonstrating many bias, the Washington

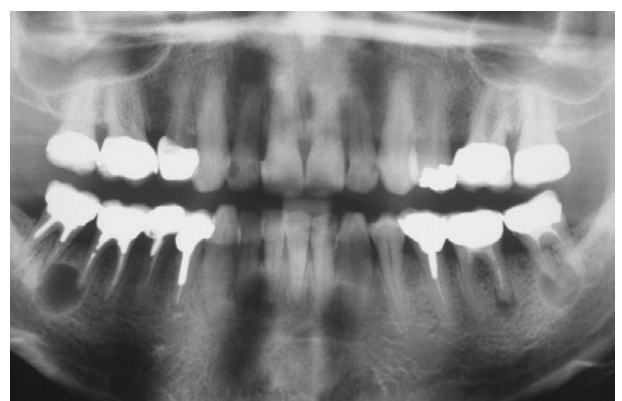


Figure 1: Inadequate and under-sealed endodontic treatments are often associated with periapical pathology.

Pierre Machtou, DDS, FICD, Private Practice, Paris, France

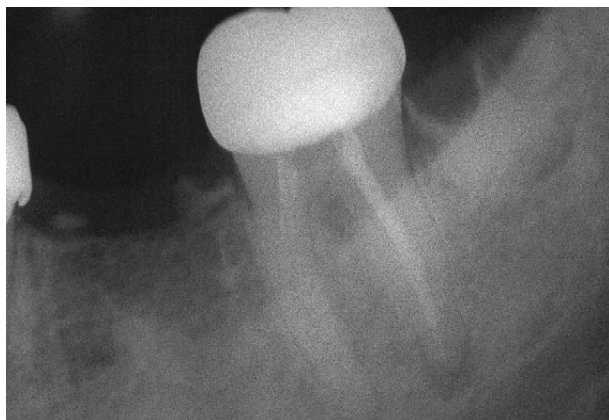


Figure 2a: Presence of an acute apical periodontitis under the crown of 37 inadequately treated. Apical leakage or coronal leakage?

study had a considerable impact in endodontics and for many years was quoted as an essential reference (Figures 2a and 2b).

As a result of this data, numerous studies were undertaken to evaluate the apical sealing of root-treated teeth. All the various techniques and all the obturation materials available at the time were assessed in vitro using various means:

- Radioactive tracers (Czonstkowski M et al, 1985)
- Electrochemical percolation (Mattison GD, Von Fraunhofer JA, 1983)
- Infiltration of dye (Robertson DC, Leeb JJ, 1982)
- Filtration of fluids under pressure (Derkson GD et al, 1986)
- Specific bacterial colonies (Soluti A, 2000)
- Lipopolysaccharides (Trope M et al, 1995)
- Mixed cultures of lipopolysaccharide and bacteria (Alves J et al, 1998).

The conclusion drawn from the review of literature is undisputed; there is no canal obturation technique or material that makes it possible to obtain and maintain a long-term apical seal.

Coronal seal

Although apical percolation has always been considered a factor in the failure of endodontic treatment, over the last

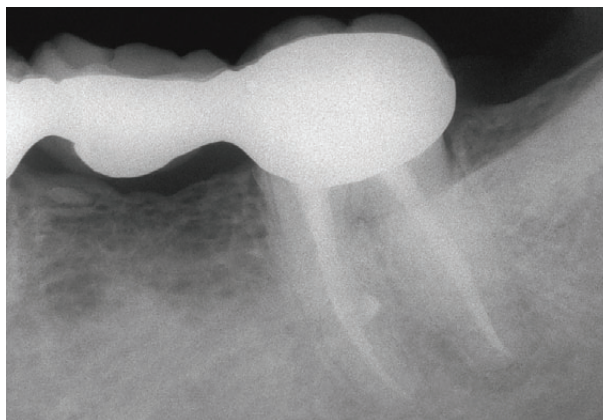


Figure 2b: After retreatment and new restoration, complete healing at one year.

10 years or so there has been a significant focus on the contamination of the root canal system via the coronal route of an inadequate restoration (Figures 3a, 3b and 3c) (Saunders WP, Saunders EM, 1997). Several disconcerting elements were brought to the fore following review of the literature, leading researchers to suggest that bacteria from the oral environment, their cellular components, their soluble derivative products or saliva could diffuse via defective coronal restorations along the interface of the obturated canals and impact on the potential success of endodontic treatment.

These elements are detailed below.

- The obvious contradiction between the high clinical success rate of endodontic treatment when it is well carried out and the absence of complete sealing as observed in vitro, even under ideal conditions
- The observation, after exhaustive examination of data collected in epidemiologic studies, that evidently under-sealed teeth (Figure 4a) remain in a normal state of periapical health (Allard U, Palmqvist S, 1986; Boucher Y et al, 2002; Bickley M, Spangberg LSW, 1995; De Cleen MJH et al, 1993; De Moor RJ et al, 2000; Eckerbom M et al, 1987; Eckerbom M et al, 1989; Eriksen HM et al, 1988; Eriksen HM et al, 1991; Eriksen HM et al, 1995; Imfeld TN, 1991; Marques MD et al, 1998; Odesjo B et al, 1990; Petersson K et al, 1986; Petersson K et al, 1991; Petersson

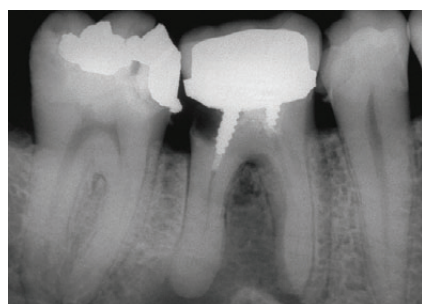

Figure 3a: Decay under the crown leads to coronal leakage.

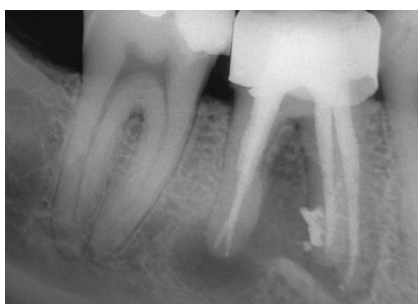


Figure 3b: Completed retreatment.

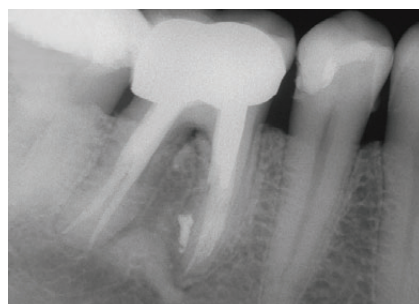


Figure 3c: A new restoration is quickly placed. The outcome is obvious one year later.

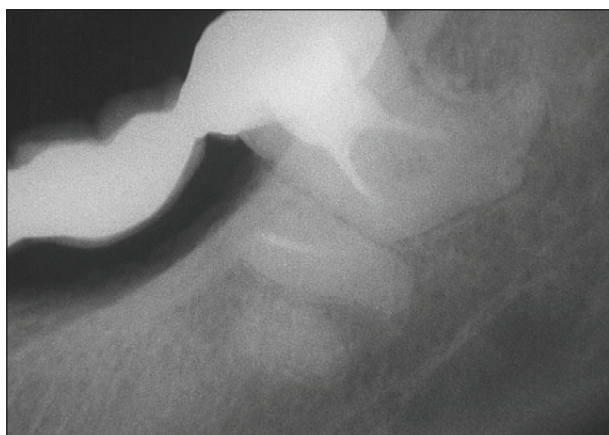


Figure 4a: Certain teeth maintain periapical health in spite of insufficient canal obturation.

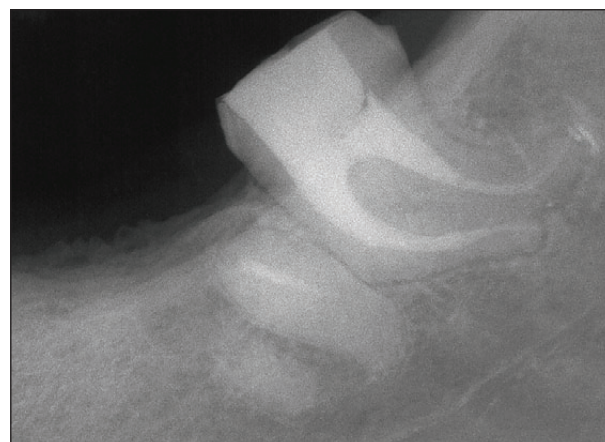


Figure 4b: A new bridge is required, the root canal is retreated.

K, 1993; Saunders WP, Saunders EM, 1997; Saunders WP et al, 1997; Sidaravicius B et al, 1999; Soikkonen KT, 1995). The opposite observation is even more disconcerting: why do we find a 20-30% failure rate in well-sealed teeth evaluated radiographically?

- The fact that a one-year period is considered sufficient by some to evaluate the appearance of an AP or its ultimate healing (Figures 2, 3 and 5), and that there is more success than failure after late endodontic treatment (Orstavik D, 1996), would lead us to believe that factors other than the quality of the obturation contribute to the development of an AP that appears more than a year after endodontic treatment

- In 1995, Ray and Trope published a retrospective clinical study based upon long-cone radiographic assessment on a population of patients with a high incidence of apical pathology (39% of 1,010 examined teeth). For the first time, the incidence of AP according to the quality of the coronal restoration was evaluated. The study showed that the absence of AP is significantly more frequent on teeth with a good coronal restoration than on those inappropriately restored (Table 1). The authors' conclusion affirmed that 'the quality of the coronal restoration is significantly more important than the quality of the endodontic treatment for periapical health'. This certainly disturbed the endodontic community, as it openly flaunted the rationale of endodontics that underscores the importance of canal obturation in creating a barrier against bacteria, while the coronal restoration is there to protect the tooth and restore it to function (Tronstad L, 1991). This research also highlighted various other studies, which had been previously unrecognised, that emphasized the potential impact of contamination coronally on the periapical tissues (Marshall FJ, Massler M, 1961; Swanson K, Madison S, 1987; Safavi KE et al, 1987). Among the most outstanding of these in vitro studies are:

1. In 1990, Torabinejad et al studied the penetration of *Staphylococcus epidermidis* and *Proteus vulgaris* on 45 single-rooted extracted teeth sealed by lateral condensation with Roth sealer, but without a coronal restoration. In 19 days, 50% of the canals were contaminated to their full length after exposure to *S. epidermidis*. The same result was obtained with *P. vulgaris* but over 52 days

2. In 1991, Magura et al evaluated the effect of salivary percolation over three months on 150 single-rooted teeth, sealed by lateral condensation with Roth sealer. The evaluation was made using a dye and by means of histology. The conclusion drawn was that it is preferable, before the placement of a final restoration, to retreat those teeth with canals that were coronally contaminated by exposure to the oral environment over a three-month period or greater

3. In 1993, Khayat et al exposed 30 single-rooted teeth to human saliva under the same conditions, extracted and sealed by lateral and vertical condensation with Roth sealer, and evaluated the penetration of saliva with a dye. All the canals were contaminated in less than 30 days, irrespective of the obturation technique used

4. In 1995, Trope et al studied the penetration of

Table 1: Percentage of success in endodontic treatment, depending on the quality of the treatment and the quality of the coronal restoration (Ray and Trope, 1995)

Quality of the endodontic treatment	Quality of the coronal restoration	% success (absence of PA)
Good	Good	91.4
Good	Poor	44.1
Poor	Good	67.7
Poor	Poor	18.1

endotoxins coronally on extracted teeth that had been sealed but not restored. The endotoxins reached the apical foramen in less than 20 days, more quickly than the bacteria that produce them

5. In 1997, Barrieshi et al used a mixture of anaerobic bacteria to evaluate in vitro the bacterial penetration on canals sealed after post space preparation. Penetration occurred between 48 and 84 days

6. In 1997, Alves et al tested the coronal penetration of endotoxins derived from a mixture of anaerobic bacteria on sealed canals that were then prepared to receive a post. To penetrate 5mm of residual obturation, it took an average time of 23 days for the endotoxins and 62 days for the bacteria

7. Fox and Gutteridge (1997) studied coronal percolation on three groups of 10 sealed teeth restored with posts and cores. Each group used a different technique: post + inlay-core + cement with Zn phosphate; pre-manufactured post + composite + adhesive; provisional crown with post + provisional cement of ZnO. The recommendation was unequivocal: 'to avoid reinfection of the root canal system, it is preferable to immediately restore the tooth with a pre-manufactured post and a composite, rather than to place a provisional restoration and a post or an inlay-core with post.'

However, even the best restorations do not seal (Goldman M et al, 1992) and do not constitute sufficient protection against percolation. Freeman et al (1998) evaluated restoration failure due to the disintegration of the cement joint induced by chewing and leakage through crown margins placed on three systems: Para-post + bonded composite (Tenure/Core Paste); Flexi-Post + bonded composite (Tenure/Core Paste); and cast Inlay-core with post (Palladium-Ag alloy). After fatigue testing up to a load of 3.5kg/72cycles/min, the three groups all showed percolation. This type of preliminary failure is not clinically detectable but allows leakage between the restoration and the tooth, which can extend to the placed post.

Bachicha et al (1998) compared the seal of two restorative systems: steel post and carbon fiber post, sealed with various cements. When the two types of posts are sealed with dentin adhesive cements (C&B Metabond and Panavia-21), the leakage is less than when they are sealed with non-adhesive cements (Zn Phosphate and glass ionomer).

The outlook is bleak and it is interesting to note that after the study of Ray and Trope (1995), most of the in vitro leakage studies have been repeated using the same methodology but instead testing for coronal leakage. All restorative procedures have been evaluated, including all types of temporary cement, provisional crowns, all types of posts and the final restoration itself. For an objective review

Table 2: Percentage of success in endodontic treatments, depending on the quality of the treatment and the quality of the coronal restoration (Tronstad et al, 2000)

Quality of the endodontic treatment	Quality of the coronal restoration	% success (absence of PA)
Good	Good	81
Good	Poor	71
Poor	Good	56
Poor	Poor	57

of the problem, refer to Heling et al (2002). However, all the results confirm the same thing; nothing is coronally sealed.

Discussion

Nowadays it is commonly agreed that the hollow tube theory is no longer credible. The protocols used, even though they were considered correct at the time, have now been invalidated. The tubes were made out of steel and their length was not controlled. They caused wounds and, as a consequence, inflammation when the rabbits moved. In addition, possible corrosion of the steel, as well as the question of an aseptic environment, was largely neglected. No information was available on the amount of time that passed between the placement of the tubes and the microscopic observation of the tissues. The effects of trauma from the placement procedure itself were also not taken into account.

Years later, the same experiments were repeated on rats with short polyethylene tubes, under aseptic condition with microscopic examination of the tissues after a sufficient postoperative period (Goldman M, Pearson AH, 1965; Phillips JM, 1967; Torneck CD, 1966). The results showed no inflammation at the open ends of the implanted tubes when they were sterile and clean. The majority of the implants showed the presence of fluids inside the lumens of the tubes. These fluids did not circulate and were compatible with normal cellular function in adjacent tissues even after a long period of placement. In certain tubes with wide-open ends, new connective tissue had invaded the entire length of the implant, in spite of the presence of fluids. From the results, it was concluded that the presence of a space, even if fluid-filled, is not sufficient to initiate and perpetuate an inflammatory reaction.

These studies were continued by Torneck (1967) with tubes filled with sterile or infected/necrotic tissue. The results showed that there was no tissue reaction when infected tissue was present. On the other hand, the presence of sterile necrotic tissue caused only little or no inflammation. This data was firmly corroborated by Möller

et al (1981).

Whereas the Washington study proposed incomplete obturation of the canal as the primary etiology of endodontic failure, up to 20 other factors can be blamed (Stabholz A et al, 1994). Today, it is accepted that the presence of intracanal bacteria is the causative agent in the development of AP (Kakehashi S et al, 1965; Möller AJT et al, 1981; Sundqvist G, 1976).

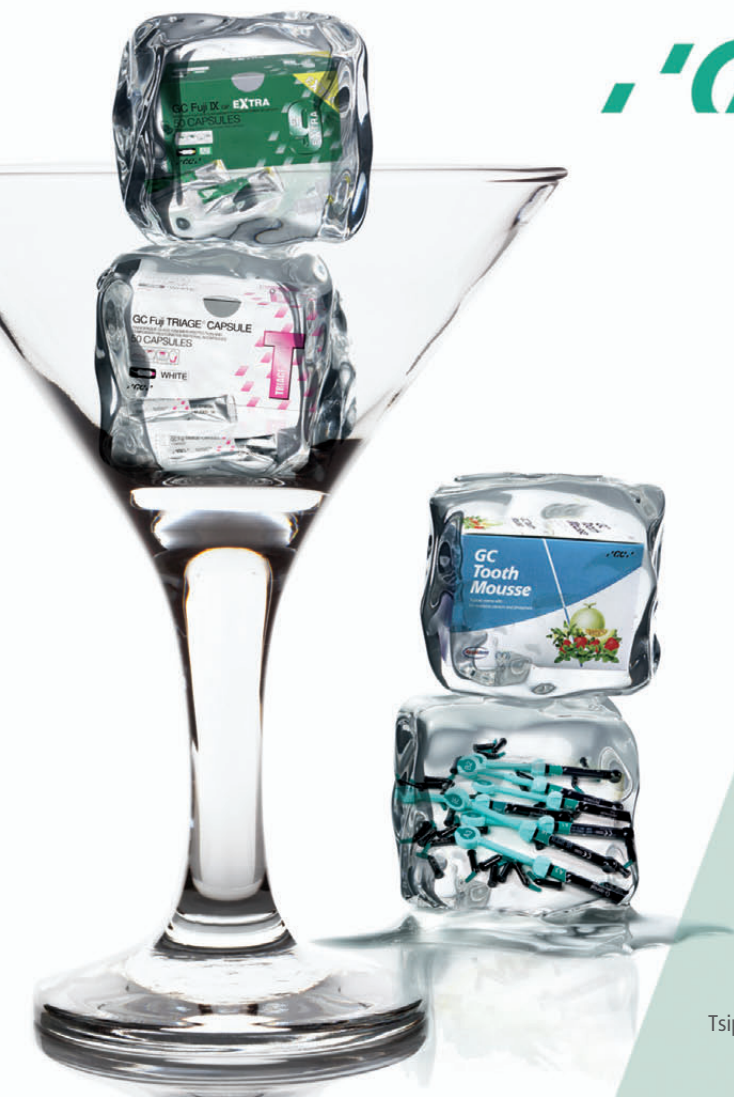The presence of bacteria in the root canal system after conventional endodontic treatment is either the result of insufficient cleaning of the root canal system (residual infection) or the consequence of contamination from bacterial leakage along the interface of the coronal restoration and the obturated canal (acquired infection). As for unsealed canal space, percolation of apical fluids is not itself a factor in failure but is the substrate for residual bacteria and their proliferation (Sundqvist G, Fidgor D, 1998).

The lack of apical and coronal seal has been exhaustively proven by in vitro studies. However, the validity of the methodology used in these investigations and their correlation with the in vivo situation has also been

questioned. In addition, the results appear to be largely overestimated and hardly comparable to the clinical situation (Kersten HW, Moorer WR, 1989; Pitt-Ford TR, 1983; Wu MK, Wesselink PR, 1993), a concept confirmed by Barthel et al (1999) who, after comparing the penetration of dyes and bacteria, found no correlation between these two methods of testing. The animal model used by Friedman et al (1997), which consists of sealing dental plaque under a restoration to test for leakage of the obturated canal, seems closer to clinical reality and should be used more often.

Since the study by Ray and Trope (1995), it has become necessary to undertake similar clinical studies to confirm the validity of the results. In 2000, Kirkevang et al evaluated the relationship between the quality of the endodontic treatment, the coronal restoration and periapical health, on a sample of the Danish population. While the study gave some credence to Ray and Trope's work, it primarily confirmed the importance of combining good canal preparation with good obturation to ensure successful clinical outcome.

The same year, Tronstad et al (2000) duplicated the Ray



'GC'



Dear Valued GC customer/user
Thank you for your on-going support during 2012.

We wish you, your staff and your family a peaceful festive season and look forward to a prosperous 2013.

GC Africa will re-open on 7 January 2013.



and Trope study and found that the success rate was significantly lower when inadequate endodontic treatment is associated with either a good or defective restoration (respectively 56% and 57%) (Table 2). The results were in agreement with those of Sidaravicius et al (1999) and of Boucher et al (2002). These articles confirmed that even when canals are not correctly sealed, the quality of the coronary restoration has no influence on the outcome of the endodontic treatment (Table 2).

Ricucci et al (2000) undertook a retrospective study over a three-year period on 55 patients whose adequately filled canals had been exposed to the oral environment because of decay or loss of the coronal restoration. At the end of the observation period, 78% of the teeth showed identical periapical conditions to the initial situation and showed no sign of AP. The results suggest that: 'the problem of coronal percolation cannot be of as much clinical importance as many in vitro studies suggested, if preparation and obturation of the canal have been carefully accomplished'.

In a histological study on 48 feline mandibular canines, Soluti (2000) analysed the periapical tissue reaction in the presence or absence of coronal leakage. Some 16 teeth were left open to the oral environment after endodontic treatment, 16 were restored with an amalgam, six were used as positive control and six as negative control. The response was the same from the apical tissues in the two groups until the third month. After five months, the difference was statistically significant. The author concluded: 'retreatment is strongly indicated when the obturated canal was exposed to the oral environment for at least five months'.

A most interesting epidemiologic study on the relationship between the state of the periapical tissues and the quality of coronal restoration and canal obturation was carried out in Belgium by Hommez et al (2002). The authors supplemented the radiographs with a clinical examination of coronal restorations and highlighted the weak correlation existing between the two approaches. The clinical examination showed a large proportion had marginal defects. As suggested by Tronstad et al (2000), marginal defects do not influence the periapical state. When a glass ionomer base is placed on the obturated canal to protect it, the percentage of AP is significantly less (25.9% versus 41.3%). Teeth restored with composite suffered a greater number of failures than those restored with amalgam (40.5% versus 28.4%). The presence of a post had no influence on the state of the periapical tissues (Tronstad et al, 2000) except where the length of the residual obturation was less than 3mm (Boucher et al, 2002; Eckerbom et al, 1991; Kvist et al, 1989). The importance of an adequate coronal restoration and adequate canal obturation in length and density was

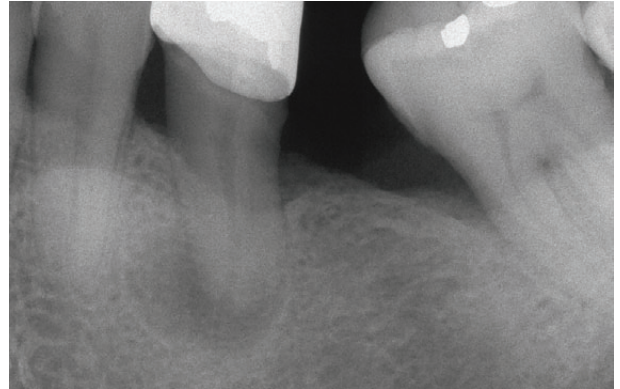


Figure 5a: The leaking crown has induced a PA

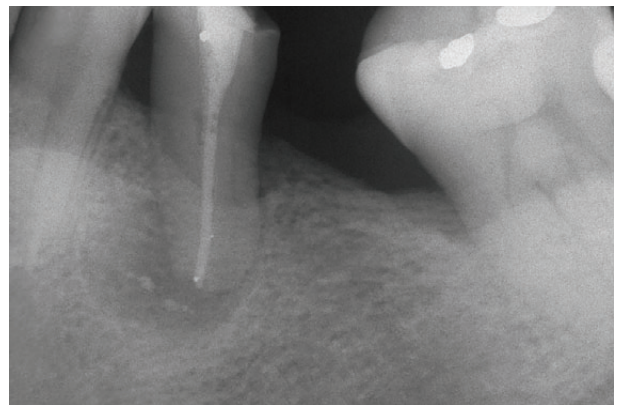


Figure 5b: Failure after first endodontic treatment

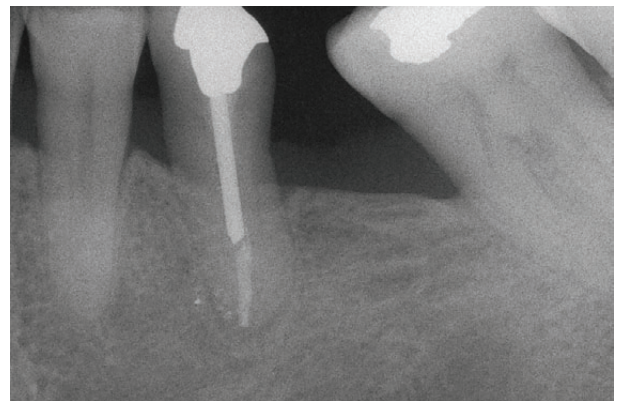


Figure 5c: Correct endodontic retreatment, quickly followed by a good restoration, optimises the outcome. Six-month follow-up

stressed, because the two procedures had a direct impact on apical health (Figures 5a, 5b, 5c).

Whilst the value of these types of study is undeniable, it is necessary to appreciate that the radiographic image of the final obturation does not reflect the total quality of the endodontic treatment (Eckerbom M, Magnusson T, 1997) and therefore gives some credit to the clinical study of Ricucci et al (2000) carried out on patients. Again Ricucci

and Bergenholtz (2003) analysed 39 correctly sealed roots histologically and bacteriologically, as well as the state of the periapical tissues of teeth exposed to the oral environment for three years or more, by loss of the coronal restoration, fracture or decay. AP appeared on only five teeth and seven obturations out of 39 showed signs of bacterial infiltration in the apical third. It thus appears that the prepared and sealed (optimally) root canal resists bacterial penetration even after long exposure to the oral environment.

Lastly, there is a significant difference between the results of studies undertaken in universities and specialist clinics (Caliskan MK, Sen BH, 1996; Friedman S et al, 1995; Friedman S et al, 1997; Grahnén H, Hansson L, 1961; Kerekes K, Tronstad L, 1979; Orstavik D, Horsted-Bindslev P, 1993; Orstavik D, 1996; Sjørgen U et al, 1990; Sjørgen U et al, 1997; Strindberg LZ, 1956) or in general practice. In universities and specialist clinics, the outcomes are excellent with about 96% success, whereas in general practice there was a high proportion of inadequate treatments (60% to 80%) associated with the presence of periapical pathology in 18% to 61% of cases (Allard U, Palmqvist S, 1986; Boucher Y et al, 2002; Buckley M, Spangberg LSW, 1995; De Cleen MJH et al, 1993; De Moor RJ et al, 2000; Eckerbom M, Magnusson T, 1997; Eriksen HM et al, 1988; Eriksen HM et al, 1991; Eriksen HM et al, 1995; Imfeld TN, 1991; Marques MD et al, 1998; Odesjo B et al, 1990; Petersson K et al, 1986; Saunders WP, Saunders EM, 1997; Sidaravicius B et al, 1999). This data confirms that the quality of endodontic treatment is very important in terms of outcome (Figures 5a, b, c) (Kirkevang LL et al, 2000; Molven O, Halse A, 1988).

Conclusion

The health of the periapical tissue is directly related to the quality of the endodontic treatment. An understanding of the complexity of the root canal system helps us to appreciate the importance of the need to adequately cleanse and obturate this system (Schilder H, 1974). Obturation is a barrier to the elimination of bacterial irritants and must be supplemented as soon as possible by coronal restoration (Davalou S et al, 1999; Helling I et al, 2002). This will optimize the outcome of the endodontic treatment.

Current research in endodontics is directed towards the use of new canal obturation materials containing resin (RealSeal, SybronEndo) that retains the same qualities as gutta percha, most notably thermoplasticity and solubility. The resin's ability to seal the prepared canal should help endodontists to perform a successful monobloc obturation hence creating a continuum with the coronal restoration.

This article was first published as 'Etanchéité apicale versus etanchéité coronaire' in Realités Cliniques 15(1): 5-20 and has been reproduced with permission

References

- Allard U, Palmqvist S (1986) A radiographic survey of periapical conditions in elderly anaerobic bacteria in a Swedish population. *Endod Dent Traumatol.* 2: 103-118
- Alves J, Walton RE, Drake D (1998) Coronal leakage: endotoxin penetration from mixed bacterial communities through obturated, post-prepared root canals. *J Endod.* 24: 587-591
- Bachicha WS, Difiore PM, Miller DA, Lautenschlager EP, Pashley DH (1998) Microleakage of endodontically-treated teeth restored with posts. *J Endod.* 24: 703-708
- Barrieshi KM, Walton RE, Johnson WT, Drake DR (1997) Coronal leakage of mixed anaerobic bacteria after obturation and post space preparation. *Oral Surg Oral Med Oral Pathol Oral Radiol Endod.* 84: 310-314
- Barthel CR, Moshonov J, Shuping G, Orstavik D (1999) Bacterial leakage versus dye leakage in obturated root canals. *Int Endod J.* 32: 370-375
- Boucher Y, Matossian L, Rilliard F, Machtou P (2002) Radiographic evaluation of the prevalence and technical quality of root canal treatment in a French subpopulation. *Int Endod J.* 35: 229-238
- Buckley M, Spangberg LSW (1995) The prevalence and technical quality of endodontic treatment in an American subpopulation. *Oral Surg Oral Med Oral Pathol Oral Radiol Endod.* 79: 92-100
- Caliskan MK, Sen BH (1996) Endodontic treatment of teeth with apical periodontitis using calcium hydroxide: a long-term study. *Endod Dent Traumatol.* 12: 215-221
- Czonstowski M, Michanovicz AM, Vasquez JA (1985) Evaluation of an injection of thermoplasticized low-temperature gutta percha using radio-active isotopes. *J Endod.* 11: 7-9
- Davalou S, Gutmann JL, Nunn MH (1999) Assessment of apical and coronal root canal seals using contemporary endodontic obturation and restorative materials and techniques. *Int Endod J.* 32: 388-396
- De Cleen MJH, Schuur AHB, Wesselink PR, Wu MK (1993) Periapical status and prevalence of endodontic treatment in an adult Dutch population. *Int Endod J.* 26: 112-119
- De Moor RJ, Hommez GM, De Boever JG, Delme KI, Martens GE (2000) Periapical health related to the quality of root canal treatment in a Belgian population. *Int Endod J.* 33: 113-120
- Derkson GD, Pashley DH, Derkson ME (1986) Microleakage measurement of selected restorative materials: a new in vitro method. *J Prosthet Dent.* 56: 435-440
- Dow PR, Ingle JJ (1955) Isotope determination of root canal failure. *J Oral Surg.* 8: 1100-1104
- Eckerbom M, Andersson JE, Magnusson T (1987) Frequency and technical standard of endodontic treatment in a Swedish population. *Endod Dent Traumatol.* 3: 245-248
- Eckerbom M, Andersson JE, Magnusson T (1989) A longitudinal study of changes in frequency and technical standard of endodontic treatment in a Swedish population. *Endod Dent Traumatol.* 5: 27-31
- Eckerbom M, Magnusson T (1997) Evaluation of technical quality of endodontic treatment – reliability of intraoral radiographs. *Endod Dent Traumatol.* 13: 259-264
- Eckerbom M, Magnusson T, Martinsson T (1991) Prevalence of apical periodontitis, crowned teeth and teeth with posts in a Swedish population. *Endod Dent Traumatol.* 7: 214-220
- Eriksen HM, Bjertness E, Orstavik D (1988) Prevalence of apical periodontitis and results of endodontic treatment in an urban adult population in Norway. *Endod Dent Traumatol.* 4: 122-126
- Eriksen HM, Bjertness E, Orstavik D (1991) Prevalence and quality of endodontic treatment in middle-aged adults in Norway. *Endod Dent Traumatol.* 7: 1-4
- Eriksen HM, Berset GP, Hansen BF, Bjertness E (1995) Changes in endodontic status (1973-93) among 35-year olds in Oslo, Norway. *Int Endod J.* 28: 129-132
- Fox K, Gutteridge DL (1997) An in vitro study of coronal microleakage in root canal treated teeth restored by the post and core technique. *Int Endod J.* 30: 361-368
- Freeman MA, Nicholls JJ, Kydd WL, Harrington GW (1998) Leakage associated with load fatigue-induced preliminary failure of full crowns placed over three different post and core systems. *J Endod.* 24: 26-32
- Friedman S, Lost C, Zarrabian M, Trope M (1995) Evaluation of success and

- failure after endodontic therapy using a glass ionomer cement sealer. *J Endod.* 21: 384-390
- Friedman S, Torneck CD, Komorowski R, Ouzounian Z, Syrtash P, Kaufman A (1997) In vivo model for assessing the functional efficacy of endodontic filling materials and techniques. *J Endod.* 23: 557-561
- Friedman S, Abitbol S, Lawrence HP (2003) Treatment outcome in endodontics: the Toronto study. Phase 1: Initial treatment. *J Endod.* 29: 787-793
- Goldman M, Pearson AH (1965) A preliminary investigation of the 'hollow tube' theory in endodontics: studies with neo-tetrazolium. *J Oral Ther Pharmacol.* 58: 618-626
- Goldman M, Laosonthorn P, White RR (1992) Microleakage – full crowns and the dental pulp. *J Endod.* 18: 473-475
- Grahnén H, Hansson L (1961) The prognosis of pulp and root canal therapy. *Odont Revy.* 12: 146-165
- Heling I, Gorfil C, Slutzky H, Kopolovic K, Zalkind M, Slutzky-Goldberg I (2002) Endodontic failure caused by inadequate restorative procedures: review and treatment recommendations. *J Prosthet Dent.* 87: 674-678
- Hommez GM, Coppens CR, De Moor RJ (2002) Periapical health related to the quality of coronal restorations and root fillings. *Int Endod J.* 35: 680-689
- Imfeld TN (1991) Prevalence and quality of endodontic treatment in an elderly urban population of Switzerland. *J Endod.* 17: 604-607
- Ingle J, Bakland LK (2002) *The Washington study in Endodontics.* 5th edition, BC Decker Inc., Hamilton-London, p.748
- Kakehashi S, Stanley HR, Fitzgerald RJ (1965) The effects of surgical exposures of dental pulp in germ-free and conventional laboratory rats. *Oral Surg Oral Med Oral Pathol Oral Radiol Endod.* 20: 340-349
- Kerekes K, Tronstad L (1979) Long-term results of endodontic treatment performed with a standardized technique. *J Endod.* 5: 83-90
- Kersten HW, Moorer WR (1989) Particles and molecules in endodontic leakage. *Int Endod J.* 22: 118-124
- Khayat A, Lee SJ, Torabinejad M (1993) Human saliva penetration of coronally unsealed obturated root canals. *J Endod.* 19: 458-461
- Kirkevang LL, Orstavik D, Horsted-Bindslev P, and Wenzel A (2000) Periapical status and quality of root fillings and coronal restorations in a Danish population. *Int Endod J.* 33: 509-515
- Kirkevang LL, Horsted-Bindslev P (2002) Technical aspects of treatment in relation to treatment outcome. *Endodontic Topics.* 2: 89-102
- Kvist T, Rydin E, Reit C (1989) The relative frequency of periapical lesions in teeth with root canal-retained posts. *J Endod.* 15: 578-580
- M agura ME, Kafrawy AH, Brown CE Jr, Newton CW (1991) Human saliva coronal microleakage in obturated root canals: an in vitro study. *J Endod.* 17: 324-331
- Marques MD, Moreira B, Eriksen HM (1998) Prevalence of apical periodontitis and results of endodontic treatment in an adult Portuguese population. *Int Endod J.* 31: 161-165
- Marshall FJ, Massler M (1961) The sealing of pulpless teeth evaluated with radioisotopes. *J Dent Med.* 16: 172-184
- Mattison GD, Von Fraunhofer JA (1983) Electrochemical microleakage study of endodontic sealer/cements. *Oral Surg Oral Med Oral Pathol Oral Radiol Endod.* 55: 102-107
- Möller AJR, Fabricius L, Daheln G, Ohman AE, Heyden G (1981) Influence on periapical tissues of indigenous oral bacteria and necrotic pulp tissues in monkeys. *Scand J Dent Res.* 89: 475-484
- Molven O, Halse A (1988) Success rates for gutta percha and Kloroperka N-O root fillings made by undergraduate students: radiographic findings after 10-17 years. *Int Endod J.* 21: 243-250
- Odesjo B, Hellden L, Saolonen L, Langeland K (1990) Prevalence of previous endodontic treatment, technical standard and occurrence of periapical lesions in a randomly selected adult general population. *Endod Dent Traumatol.* 6: 265-272
- Orstavik D, Horsted-Bindslev P (1993) A comparison of endodontic treatment results at two dental schools. *Int Endod J.* 26: 348-354
- Orstavik D (1996) Time course and risk analyses of the development and healing of chronic apical periodontitis. *Int Endod J.* 29: 150-155
- Orstavik D, Pitt-Ford TR (1998) *Essential endodontology. Prevention and treatment of apical periodontitis.* Blackwell Sciences, Hamilton-London
- Pandersson K, Petersson A, Holsson B, Hakansson J, Wennberg A (1986) Technical quality of root fillings in an adult Swedish population. *Endod Dent Traumatol.* 2: 99-102
- Pandersson K, Hakansson R, Hakansson J, Olsson B, Wenn-Berg A (1991) Follow-up study of endodontic status in an adult Swedish population. *Endod Dent Traumatol.* 7: 221-225
- Pandersson K (1993) Endodontic status of mandibular premolars and molars in Swedish adults. A repeated cross-sectional study in 1974 and in 1985. *Endod Dent Traumatol.* 9: 185-190
- Pitt-Ford TR (1983) Relation between seal of root fillings and tissue response. *Oral Surg Oral Med Oral Pathol Oral Radiol Endod.* 55: 291-294
- Phillips JM (2967) Rat connective tissue response to hollow polyethylene tube implants. *J Can Dent Assoc.* 33: 59-64
- Ray HA, Trope M (1995) Periapical status of endodontically-treated teeth in relation to the technical quality of the root filling and the coronal restoration. *Int Endod J.* 28: 12-18
- Rickert UG, Dixon CM (1931) The controlling of root surgery. Transactions, Eighth International Dental Congress, Section 111a,
- Ricucci D, Grondahl K, Bergenholtz G (2000) Periapical status of root-filled teeth exposed to the oral environment by loss of restoration or caries. *Oral Surg Oral Med Oral Pathol Oral Radiol Endod.* 90: 354-9
- Ricucci D, Bergenholtz G (2003) Bacterial status in root-filled teeth exposed to the oral environment by loss of restoration and fracture or caries. A histobacteriological study of treated cases. *Int Endod J.* 36: 787-802
- Robertson DC, Leeb JJ (1982) The evaluation of a transparent tooth model system for the evaluation of endodontically-filled teeth. *J Endod.* 8: 317-721
- Safavi KE, Dowden WE, Langeland K (1987) Influence of delayed coronal permanent restoration on endodontic prognosis. *Endod Dent Traumatol.* 3: 187-191
- Saunders WP, Saunders EM (1994) Coronal leakage as a cause of failure in root canal therapy: a review. *Endod Dent Traumatol.* 10: 105-108
- Saunders WP, Saunders EM (1997) The root filling and restoration continuum. Prevention of long-term endodontic failures. *Alpha Omega.* 90: 40-46
- Saunders WP, Saunders EM, Sadiq J, Cruickshank E (1997) Technical standard of root canal treatment in an adult Scottish sub-population. *Br Dent J.* 182: 382-386
- Schilder H (1974) Cleaning and shaping the root canal. *Dent Clin North Amer.* 18: 269-296
- Sidaraavicius B, Aleksejuniene J, Eriksen HM (1999) Endodontic treatment and prevalence of apical periodontitis in an adult population in Vilnius, Lithuania. *Endod Dent Traumatol.* 15: 210-215
- Sjorgen U, Hagglund B, Sundqvist G, Wink K (1990) Factors affecting the long-term results of endodontic treatment. *J Endod.* 16: 498-504
- Sjorgen U, Figdor D, Persson S, Sundqvist G (1997) Influence of infection at the time of root filling on the outcome of endodontic treatment of teeth with apical periodontitis. *Int Endod J.* 30: 297-306
- Soikkonen KT (1995) Endodontically treated teeth and periapical findings in the elderly. *Int Endod J.* 28: 200-203
- Soluti A (2000) Histologic study of periapical tissue reaction to endodontic treatment with and without coronal microleakage in cats. Oral research abstract no 19, 57th annual session AAE, Honolulu. *J. Endod.* 26: 540
- Sritharan A (2002) Discuss that the coronal seal is more important than the apical seal for endodontic success. *Aust Endod J.* 28: 112-115
- Stabholz A, Friedman S, Tame S (1994) Endodontic failures and retreatment, pp. 691-728. In: Pathways of the pulp. Cohen S and Burns RC (eds). 6th edition. Mosby, St Louis
- Strindberg LZ (1956) The dependence of the results of pulp therapy on certain factors. An analytic study based on radiographic and clinical follow-up examination. *Acta Odontol Scand.* 14: suppl. 21
- Sundqvist G (1976) Bacteriological studies of necrotic pulps. Thesis, Umea. Sweden
- Sundqvist G, Figdor D (1998) Endodontic treatment of apical periodontitis, pp. 242-269. In: Prevention and treatment of apical periodontitis. Orstavik D, Pitt Ford TR (eds). *Essential Endodontology*; London, Blackwell Science Ltd
- Swanson K, Madison S (1987) An evaluation of coronal microleakage in endodontically-treated teeth. Part I. Time periods. *J Endod.* 13: 56-59
- Torabinejad M, Ung B, Kettering JD (1990) In vitro bacterial penetration of coronally unsealed endodontically treated teeth. *J Endod.* 16: 566-569
- Torneck CD (1966) Reaction of rat connective tissue to polyethylene tube implants – I. *Oral Surg Oral Med Oral Pathol Oral Radiol Endod.* 21: 379-387
- Torneck CD (1967) Reaction of rat connective tissue to polyethylene tube implants – II. *Oral Surg Oral Med Oral Pathol Oral Radio Endod.* 24: 674-683
- Tronsdat L (1991) *Clinical endodontics. A textbook.* Thieme Medical Publishers Inc., New York
- Tronsdat L, Absjornsen K, Doving I, Pedersen I, Eriksen HM (2000) Influence of coronal restorations on the periapical health of endodontically-treated teeth. *Endod Dent Traumatol.* 16: 218-221
- Trope M, Chow E, Nissan R (1995) In vitro endotoxin penetration of coronally unsealed endodontically treated teeth. *Endod Dent Traumatol.* 11: 90-94
- Wu MK, Wesselink PR (1993) Endodontic leakage studies reconsidered. Part I. Methodology, application and relevancy. *Int Endod J.* 26: 37-43