

Treatment of a crown-root fracture using a composite endodontic post

Jozef Minčík,¹ Marián Tulenko²

With crown-root fractures, are tooth fractures in which one or more fracture lines comprise both portions of the crown and the root (Andreasen/Andreasen, 1994). In most cases, a fracture line runs from buccal-coronal to palatal-apical into the cervical root third, where it often takes a very abrupt course, before it discontinues in a slight degree toward coronal (Figure 1).

This complicated injury presents the practitioner with a difficult task, since surgical, endodontic, restorative and also orthodontic treatments are necessary to retain the tooth. We strive to avoid extracting the coronal fragments in most cases. This comes with multiple disadvantages. Firstly: Pulp extirpation must be carried out immediately under poor basic conditions (bleeding from the periodontium, poor visibility). Secondly: The gingiva covers the apical fragment within a short amount of time and must be removed. Thirdly: The patient has a massive aesthetic impairment. The best therapeutic alternative is thus conservation of the entire tooth with the assistance of internal splinting (Ebelseder et al., 1993). In such cases, the authors use glass fibre-reinforced, composite endodontic posts (Rebilda Post, VOCO).

¹ Jozef Minčík
Private practice, Košice, Slovakia. Director, Conservative Dentistry Section, Slovakian Dental Association
² Marián Tulenko
Dentist, member, Slovakian Dental Association, Slovakia

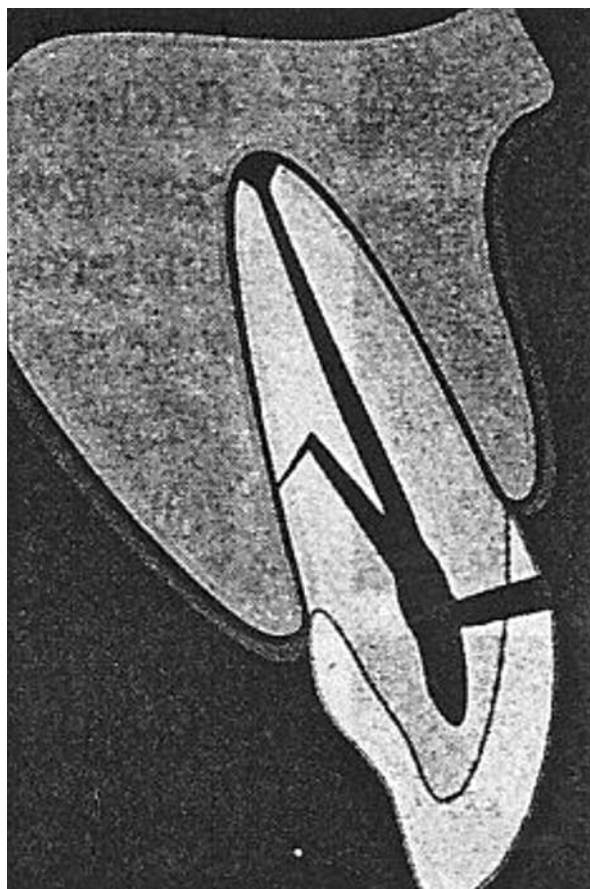


Figure 1: Typical progression of a crown-root fracture (Ebelseder/Glockner, 2000).

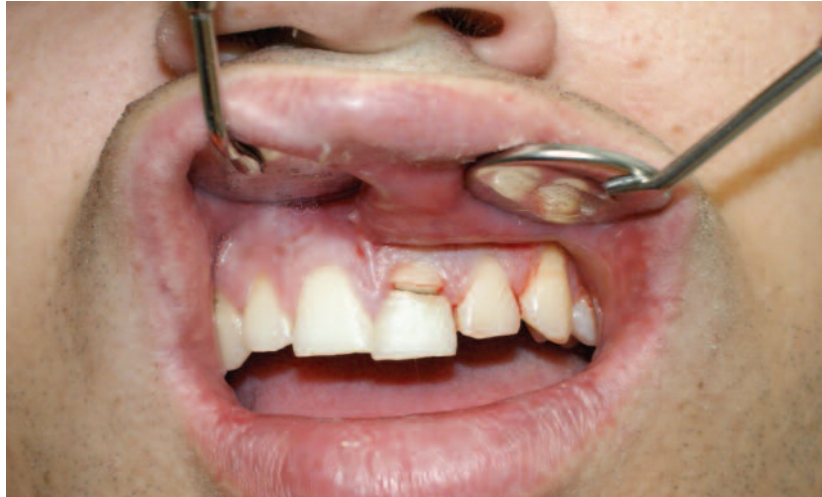

Figure 2: Crown-root fracture: The coronal opening communicates directly with the pulp.

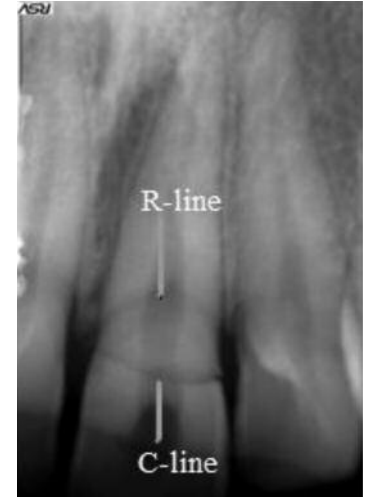

Figure 3: X-ray of tooth 21 with the typical progression.

Case report

A 20 year old patient presented at the surgery after an accident during a contact sport. The crown of tooth 21 was in a supra-occlusion and proved to be very mobile and sensitive. The cervical range of the crown exhibited a straight fracture that bled slightly (Figure 2).

The diagnosis of a combination crown-root fracture was confirmed with an x-ray, which showed an ill-defined ellipse. The bottom line displayed the intra-coronal portion of the fracture opening (C-line), the top line the intra-radicular portion (R-line) (Figure 3).

Exact reposition was carried out under local anesthesia immediately after the diagnosis. We sealed

the opening with light-curing, glass ionomer composite cement (Ionoseal, VOCO). The coronal fragment was splinted labially with a glass fibre strip, which was attached to the neighbouring teeth with composite (Figure 4). This immediately provided the patient with the ability to chew with only slight aesthetic impairment.

Trepanation and pulp extirpation were carried out after the splinting. A definitive endodontic treatment was not possible during the first treatment, because the root canal bled heavily. Calcium hydroxide was thus applied as a temporary filling. The root canal was then definitively treated in the second appointment (Figure 5).

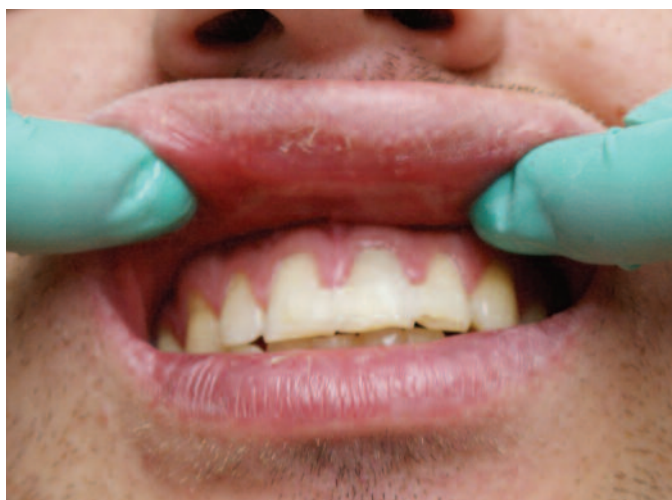

Figure 4: Splinting of the fragments that support the crowns using glass fibre strips and composite.

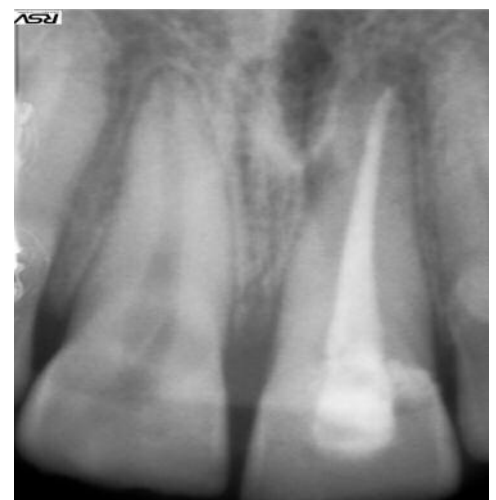

Figure 5: Definitive endodontic treatment of tooth 21.



Figure 6: Rebilda Post (VOCO).

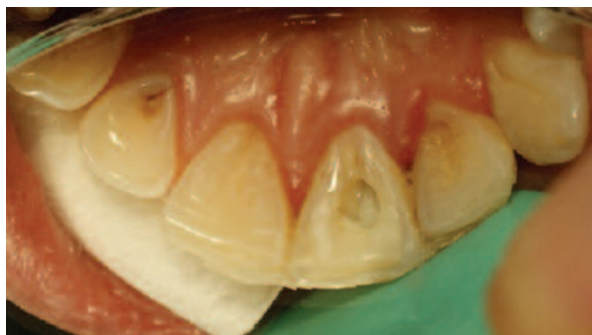

Figure 7: The inserted endodontic post Rebilda Post (palatal view).

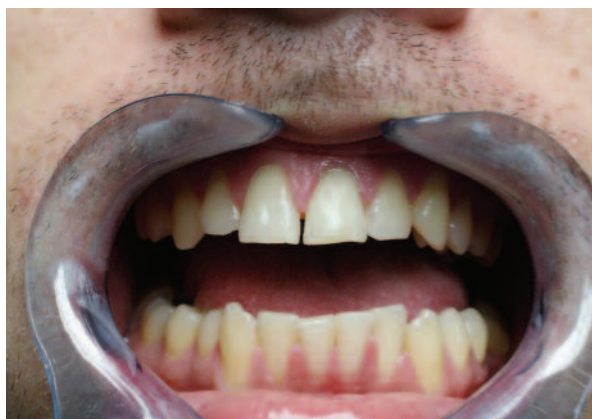

Figure 8: Tooth 21 after treatment.

The Ebelseder (Ebelseder et al., 1993) method of internal splinting was carried out to secure the refixation result, whereby the two fragments were connected with a glass fibre-reinforced composite endodontic post (Rebilda Post, VOCO, Figure 6).

The root canal was prepared – with the exception of the apical 4 mm – with the appropriate bur. The treatment then began by trying in the endodontic post and subsequently trimming the post to the necessary length extra-orally. After the application of a dual-curing, self-etching adhesive (Futurabond DC, VOCO), the endodontic post was inserted in the root canal with a twisting motion (Figure 7).

The combined labial splinting was eliminated after the internal fixation. The coronal fracture that was sealed with glass ionomer cement during the initial presentation and then covered it with a layer of highly aesthetic, light-curing composite (Amaris, VOCO) was then carefully ground out. The treated tooth could now withstand full chew loading and the natural aesthetic was restored (Figure 8).

Final remarks

It is also possible to restore crown-root fractured anteriors with the utilization of several dental partial disciplines. The conservation of the entire tooth using internal splinting with composite endodontic posts is a good treatment alternative. According to the authors' clinical experience, a durable and biologically faultless restoration can be achieved by employing this treatment alternative.

References

1. Andreasen, J. O./Andreasen, F. M.: Textbook and colour atlas of traumatic injuries of the teeth, Copenhagen, Munksgaard, 1994.
2. Ebelseder, K./Cartellieri, B./Polanski, R./Eskici, A.: Versuch der Erhaltung von Frontzähnen durch innere Schienung bzw. Transfixation, in: Quintessenz, 44, 1993 (9), S. 1597-1610.
3. Ebelseder, K./Glockner, K.: Zahnerhaltung nach Kronen-Wurzel-Fraktur, in: Stomatologie, 97, 2000 (6), S.11-14.