

# Inheriting the unhappy patient: an interdisciplinary case report

Vincent G. Kokich, David P. Mathews and Frank M. Spear

## Introduction

A serious problem that challenges any interdisciplinary team is inheriting treatment that is already in progress but not proceeding appropriately in the eyes of the patient. When the patient senses that the initial treatment plan, progress, or sequence is irregular and convoluted, rather than smooth and well executed, they may seek a second opinion. How do you handle these opinions when you know that the treatment could be improved? Do you call the doctors currently treating the patient? Do you refer the patient back to the original doctor with a note or recommendation? What if the patient has lost confidence in the current team and wants you and your team to complete the treatment? The following case report illustrates the unfortunate consequences of uncoordinated and unplanned multidisciplinary treatment that was recognised by the patient and brought to the attention of the treating dentist. We demonstrate the steps that were necessary to treat this patient in an interdisciplinary manner and satisfy her functional and aesthetic goals for her dentition.

## Diagnosis and etiology

The patient was a 29-year-old female who had been referred to an orthodontist to align her teeth prior to restorative dentistry with an implant to replace a missing tooth. The patient had been wearing orthodontic brackets on her teeth for about one year. She was congenitally missing maxillary and mandibular right and left second

premolars and the maxillary left first premolar. Prior to orthodontic treatment, she had a resin-bonded bridge connecting the remaining maxillary left primary second molar to the permanent canine, with a pontic replacing the maxillary left first premolar. Because the maxillary right and mandibular right and left second premolar edentulous sites had closed, there was a significant midline discrepancy (Figure 1). The original treatment plan involved removing the resin-bonded bridge, extracting the maxillary left primary second molar, shifting the dental midline, and placing an implant to replace the missing maxillary left second premolar.

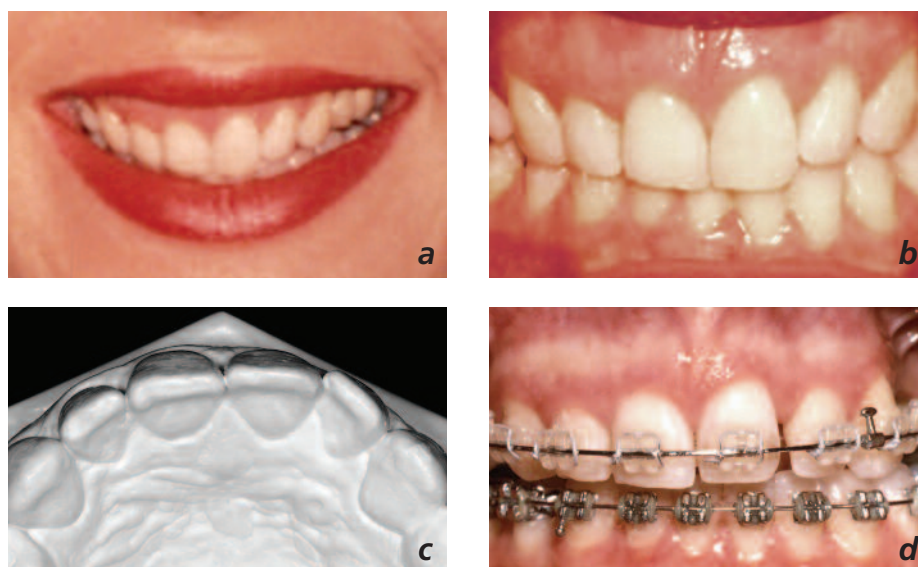
After one year of orthodontic treatment, the patient already had paid the entire orthodontic fee and the teeth had been aligned. However, the midline was still deviated and the maxillary left edentulous space was still open. In addition, the patient indicated to the dentist that her maxillary right incisors were shorter than the left (Figure 1). When the patient confronted the orthodontist about how he would treat this discrepancy, he referred her to a periodontist to explore the possibility of crown lengthening. Although the patient had slightly deeper labial sulci of the maxillary right anterior teeth than the left, the periodontist told her that perhaps the orthodontist should treat the crown length discrepancy. When the patient returned to the orthodontist with this recommendation, the orthodontist seemed puzzled, the patient became alarmed, and she sought a second opinion.

The orthodontist rendering the second opinion indicated that the midline was still uncorrected, the maxillary anterior crown lengths were significantly different, and too much space and insufficient bone existed at the site for the future implant. The second orthodontist suggested that the patient return to the original orthodontist to review the discrepancies that concerned her and ask how they would be corrected. When the patient again confronted the original orthodontist, he became alarmed and told her that perhaps she should seek treatment from a team that could provide an interdisciplinary approach to her multiple

*Frank Spear DDS, MSD.  
Affiliate Professor in the graduate prosthodontics program at the University of Washington. Private practice in Seattle*

*Vincent G. Kokich, DDS, MSD  
Professor, School of Dentistry, Department of Orthodontics,  
University of Washington. Seattle, Washington.  
Private Practice, Tacoma, Washington*

*David P. Mathews, DDS  
Affiliate Assistant Professor, School of Dentistry, Department of  
Periodontics, University of Washington. Seattle, Washington.  
Private Practice. Tacoma, Washington*



**Figure 1:** This patient was missing her maxillary and mandibular right and left 1st premolars and the maxillary left 2nd premolar. The maxillary left primary 1st and 2nd molars were still in place. As a result, the maxillary midline was shifted to her right side (A). The maxillary right central and lateral incisors and canine were shorter than the contralateral maxillary anterior teeth (B) due to incisal abrasion (C). The original orthodontist placed the brackets on the maxillary anterior teeth based upon the incisal edges. As a result, there was a gingival margin discrepancy following initial tooth alignment (D).

problems. The patient agreed, and she was referred to our team to plan and complete her orthodontic, periodontal, and restorative treatment. The records from the original orthodontist were forwarded to our team. However, no initial periodontal charting had been performed, no diagnostic wax set-up had been constructed, and no detailed orthodontic/periodontic/restorative treatment plan or sequence had been generated.

Transfer records, including dental casts, facial and intraoral photographs, panoramic, cephalometric and bitewing radiographs, as well as a complete periodontal charting, were obtained. In the interim, while the treatment was being planned, the orthodontic brackets were removed because they were not moving the teeth in the correct direction. Our team, consisting of an orthodontist, periodontist, and restorative dentist, met to identify the problem list, treatment objectives, treatment alternatives, and eventual treatment plan and sequence.

### Problem list and treatment objectives

After careful review of the patient's dental, occlusal, and aesthetic problems, followed by a consultation with the patient regarding her specific goals, our team identified the following treatment objectives:

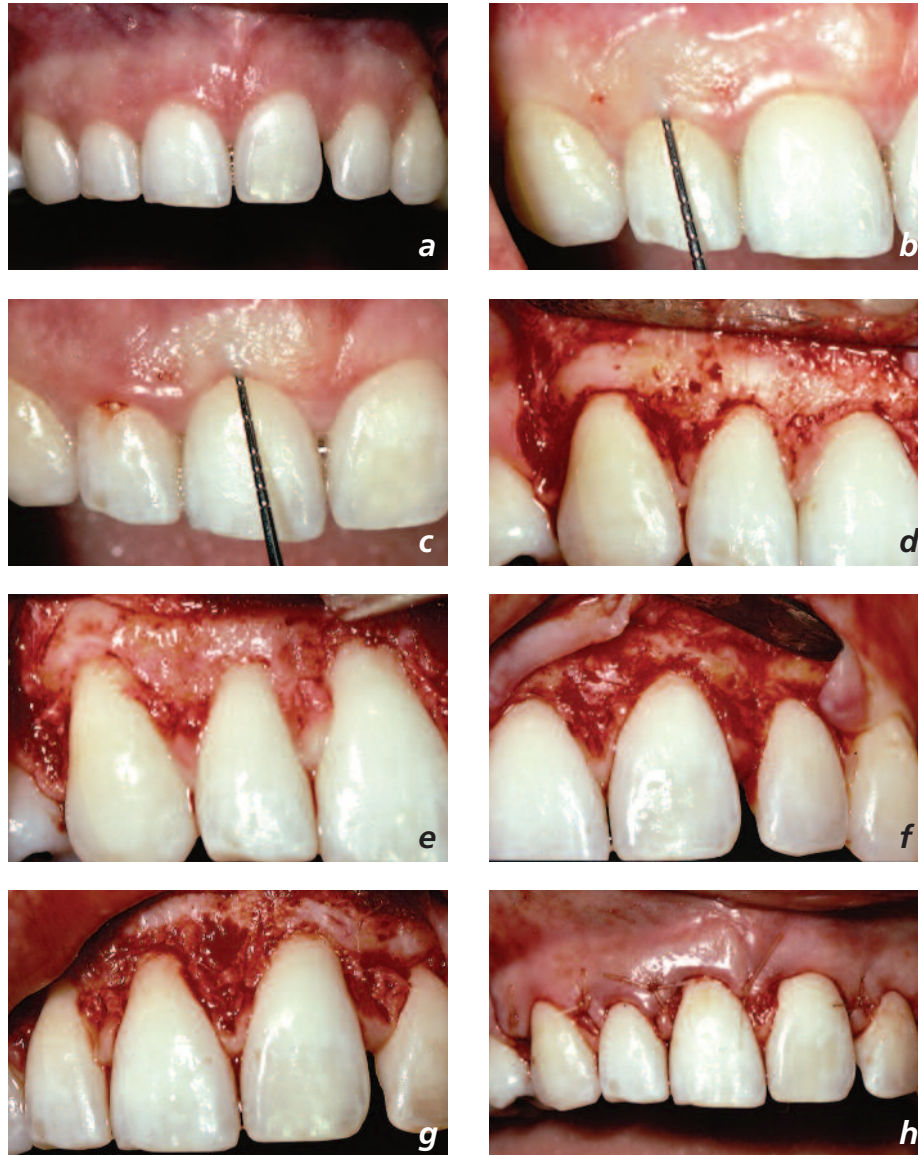
1. Align the maxillary dental midline with the facial midline.
2. Close part of the space in the maxillary left posterior region to leave 7mm of space for an implant and crown.

3. Level the gingival margins between the maxillary right and left central incisors, lateral incisors, and canines.
4. Reduce the amount of gingiva that shows during smiling.
5. Establish an Angle Class I canine relationship on the left side.
6. Create sufficient alveolar width for the placement of an implant in the maxillary left second premolar region.

### Treatment alternatives

Various alternatives were possible to achieve this patient's treatment goals. Orthognathic surgery could be used to close the edentulous space in the maxillary left posterior region and correct the maxillary dental midline. This option would provide a rapid change in the midline, avoid any loss of orthodontic anchorage, and easily close part or all of the maxillary posterior space. In fact, a bone graft could be accomplished at the same time in order to create sufficient ridge width for the implant. Alternatively, orthodontics could be used to correct the midline and close the space, but orthodontics would take more time. Both options were presented to the patient. She was opposed to any maxillary jaw surgery and chose the orthodontic option in spite of the longer treatment time.

The objectives of leveling the gingival margins, creating similar anterior crown lengths, and reducing the amount of gingival display on smiling could be accomplished with



**Figure 2:** After the original orthodontic appliances were removed (A), the orthodontist and periodontist had to decide who would correct the gingival margin discrepancies between the right and left anterior teeth. The bone sounding measurements of the right lateral (B) and central (C) incisors showed a 3mm biologic width, but the CEJ was located near the bone level, indicating altered active eruption. Elevation of a mucoperiosteal flap (D) confirmed that the bone levels were near the CEJ. The bone levels were moved surgically to a level about 2 mm from the CEJ (E). The same procedure was performed on the left anterior teeth (F, G). The flap was apically positioned so that the gingival margins were about 3 mm from the respective labial bone of each tooth (H).

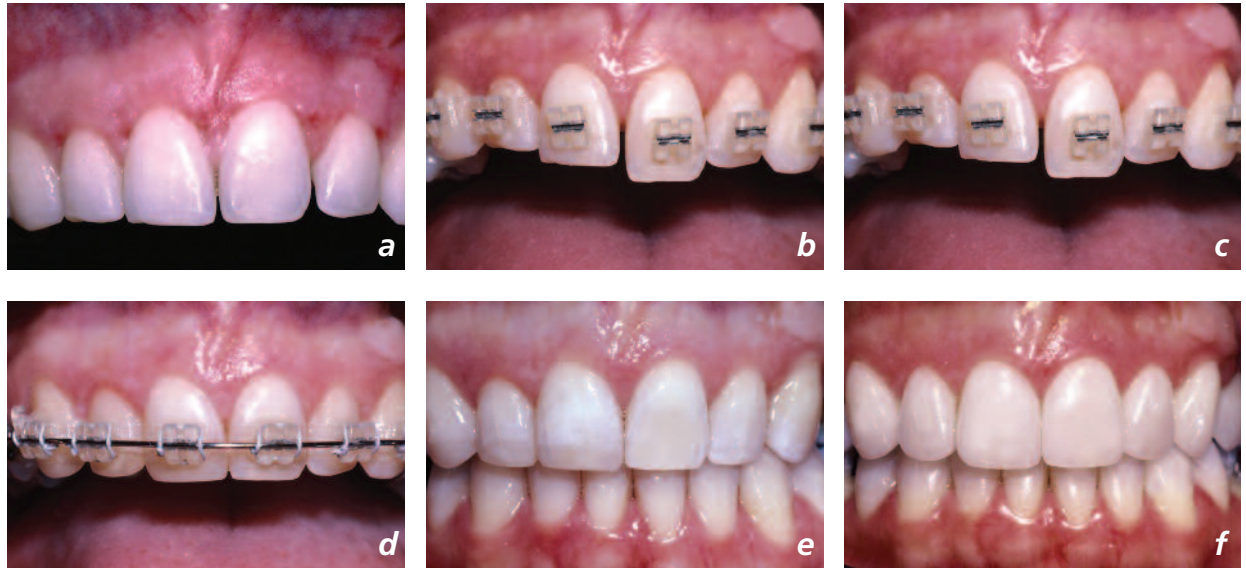
either periodontal crown lengthening (Pasquinelli 1999), orthodontic intrusion, or a combination of these two procedures. The team discussed the options, and in order to avoid exposure of cementum during crown lengthening, a combination of periodontal surgery and orthodontic intrusion of the maxillary right anterior teeth was chosen to achieve this treatment objective.

In order to create sufficient alveolar width for an implant in the maxillary left posterior region, bone augmentation would be needed (Nevins and Mellonig 1992). Either

autogenous bone, allograft, or xenograft could be used in combination with a resorbable or non-resorbable membrane (Buser et al 1993). For this patient, our team decided that decalcified, freeze-dried cadaver bone with a titanium-reinforced, non-resorbable membrane provided the best alternative (Simion et al 1996).

#### **Treatment plan and sequence**

In order to accomplish the treatment objectives, the following treatment plan and sequence were established:



**Figure 3:** One week after the gingival surgery, the gingival margins and CEJs of the right and left anterior teeth were still not commensurate (A), indicating that incisal abrasion had accounted for at least part of the crown length discrepancy. Therefore, during the initial stages of the orthodontics, the maxillary right central and lateral incisors and canine were intruded (B) until the gingival margins were at the same level as the left anterior teeth. In order to temporarily restore the crown length of these abraded teeth, the orthodontic brackets were removed (C), the incisal edges restored with composite, and the brackets replaced on the teeth (D). After holding the intruded teeth for at least six months, the orthodontic appliances were removed (E), leaving the right and left anterior gingival margins at the same levels. One year later, porcelain laminate restorations (F) were used to replace the direct composite restorations that were added during the orthodontic treatment.

1. Removal of all existing orthodontic appliances, followed by root planing and scaling to create a healthy environment in which to carry out the treatment plan.
2. Construction of a diagnostic wax-up to simulate the occlusion that would be produced and create a similar vision for all practitioners involved in this patient's treatment.
3. Periodontal surgery to reduce any existing excessive sulcular depth and create consistent biologic width between the alveolar crest and the gingival margins in the maxillary anterior region (Figure 2).
4. Placement of orthodontic brackets in a position that would facilitate orthodontic intrusion (Figure 3) of the maxillary right central incisor, lateral incisor, and canine to establish level gingival margins between the right and left sides. This option would also reduce the gingival display that was apparent on the right side pretreatment.
5. Temporary restoration of the incisal edges of the maxillary right central incisor, lateral incisor, and canine to create identical crown lengths with the maxillary left anterior teeth (Figure 3). This could be accomplished with a composite restoration that would last at least throughout the finishing portion of the orthodontics.
6. Orthodontic correction of the maxillary dental midline deviation and closure of part of the maxillary left posterior edentulous space (Figure 3).
7. Alveolar bone graft to the maxillary left posterior region

in order to establish sufficient width-of-bone to place an implant. This would be accomplished during the finishing stages of the orthodontics (Figure 4).

8. Placement of an implant in the maxillary left posterior region approximately 9 months after the alveolar bone graft, during the finishing stages of the orthodontic treatment (Figure 4).

9. Completion of the orthodontic treatment to establish the correct occlusion with adequate protrusive guidance and canine protected lateral excursions (Figure 5).

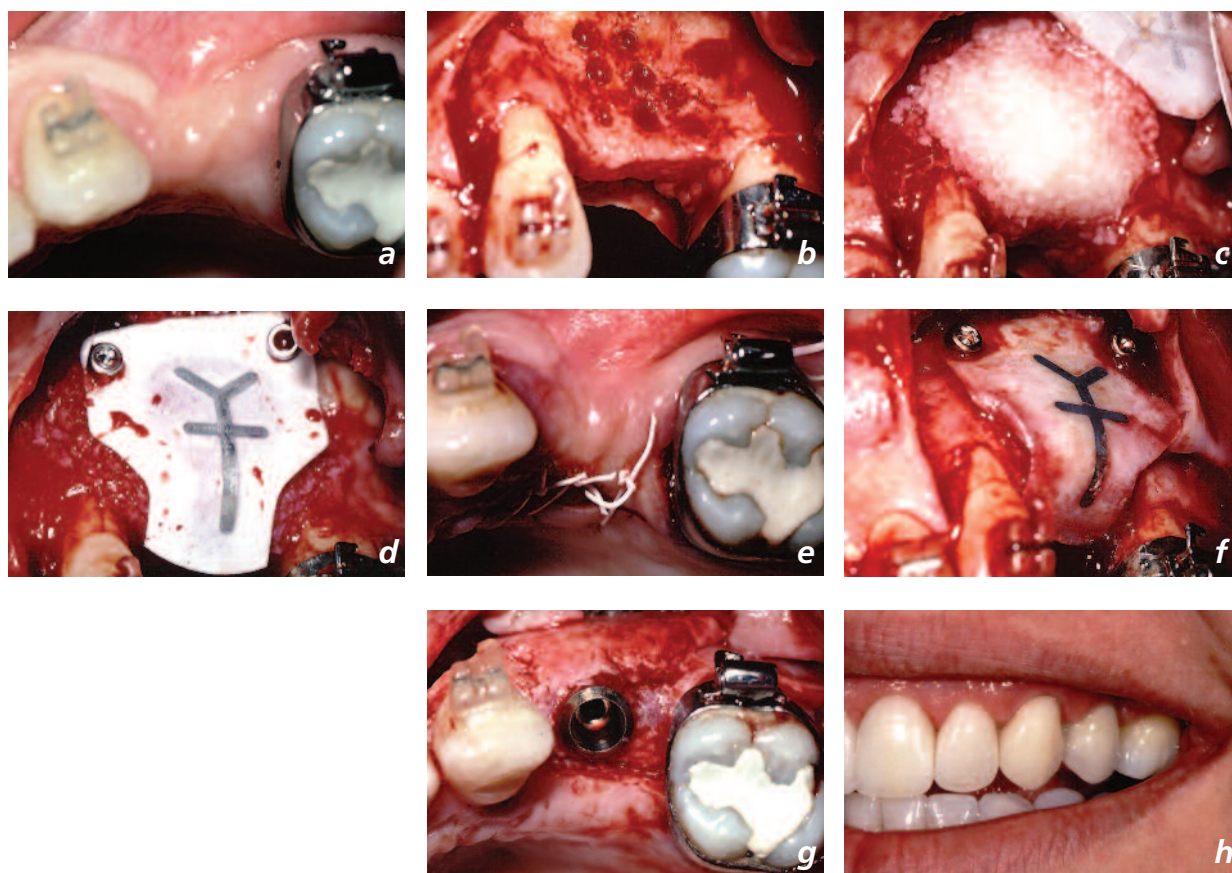
10. Orthodontic appliance removal and retention of the corrected malocclusion using a maxillary Hawley retainer with a plastic tooth in the edentulous space to prevent space closure.

11. Final restoration of the maxillary arch once the implant had integrated for six months (Figure 3).

12. Construction of a maxillary night guard to protect against any further asymmetric wear on the incisal edges of the anterior teeth.

### Treatment progress and results

After our team discussed the various alternatives and established the treatment plan and sequence, a diagnostic wax-up was constructed to simulate the final orthodontic tooth position, as well as the restorations that would be accomplished to restore function and esthetics. Then, separate consultations were performed by each of the



**Figure 4:** Part of the orthodontic treatment plan was to reduce the size of the maxillary left posterior edentulous space from 14 mm to 8 mm (A). Because the ridge width was deficient, the team decided to augment the ridge during the finishing stages of the orthodontics so that the implant could be placed near the end of orthodontics and restored soon thereafter. A mucoperiosteal flap was elevated, revealing the significant resorption of the ridge. Holes were made in the cortical bone (B) to provide a blood supply, and decalcified, freeze-dried bone (C) was placed over the area of the ridge deficiency. A titanium-reinforced membrane (D) was positioned over the bone graft material, and the membrane was secured with two screws. The flap margins were re-approximated and sutured (E). After nine months, a flap was re-elevated (F), the membrane removed, and an implant placed into the grafted site (G) during the finishing stages of the orthodontic treatment. After appliance removal and retention, a porcelain crown was placed on the implant (H) to restore function and aesthetics.

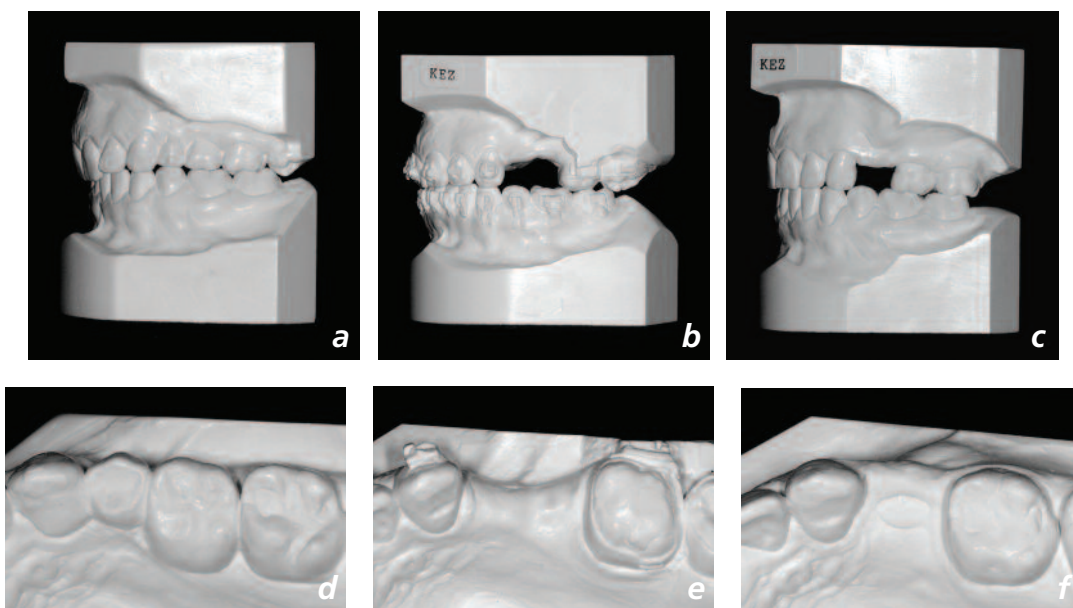
three practitioners involved in this patient's treatment. After the patient was fully informed of the plan, the treatment began according to the sequence described. This patient developed confidence in our approach because our plan was integrated, well planned, and she was able to visualise the proposed result on the diagnostic wax-up. These steps are absolutely necessary for accomplishing an interdisciplinary approach to treatment.

The crown lengthening was accomplished by the periodontist on our team. The amount of apical movement of the gingival margins was determined by the relative positions of the cemento-enamel junctions (CEJs) of the maxillary anterior teeth (Allen 1993, Becker et al 1998) (Figure 2). No attempt was made to completely level the gingival margins with the surgery. The goal was to establish similar distances between the CEJs of the adjacent teeth and the labial bone. Orthodontic intrusion would

then be used to level the gingival margins.

The orthodontic treatment was uneventful. The most difficult aspect of the orthodontics was correcting the dental midline without tipping the maxillary anterior teeth to the left during this process. Although intrusion of the maxillary right anterior teeth and correction of the midline could have been accomplished simultaneously, it was easier to intrude the teeth first (Figure 3) and then correct the midline in order to prevent tipping of the teeth during this process. After the right central incisor, lateral incisor, and canine were intruded, the brackets were temporarily removed so that the incisal composite restorations could be placed (Figure 3). This involved careful coordination of the appointments between the orthodontist and restorative dentist on the team so that the steps could all be completed on the same day.

The bone graft to the edentulous maxillary ridge (Figure



**Figure 3:** One week after the gingival surgery, the gingival margins and CEJs of the right and left anterior teeth were still not commensurate (A), indicating that incisal abrasion had accounted for at least part of the crown length discrepancy. Therefore, during the initial stages of the orthodontics, the maxillary right central and lateral incisors and canine were intruded (B) until the gingival margins were at the same level as the left anterior teeth. In order to temporarily restore the crown length of these abraded teeth, the orthodontic brackets were removed (C), the incisal edges restored with composite, and the brackets replaced on the teeth (D). After holding the intruded teeth for at least six months, the orthodontic appliances were removed (E), leaving the right and left anterior gingival margins at the same levels. One year later, porcelain laminate restorations (F) were used to replace the direct composite restorations that were added during the orthodontic treatment.

4) was accomplished after the maxillary left posterior space had been closed to about 8mm, but before the orthodontic appliances had been removed. This was done intentionally so that the implant could also be placed prior to bracket removal in order to reduce the time that a removable retainer would be necessary to maintain the edentulous space. During these procedures, the patient was seen by the orthodontist in the morning to remove the archwires, sent to the periodontist to perform the bone graft, and was then seen again by the orthodontist to replace the archwires on the same day. This degree of coordination is necessary to avoid losing any space in the area of the bone graft during the healing process.

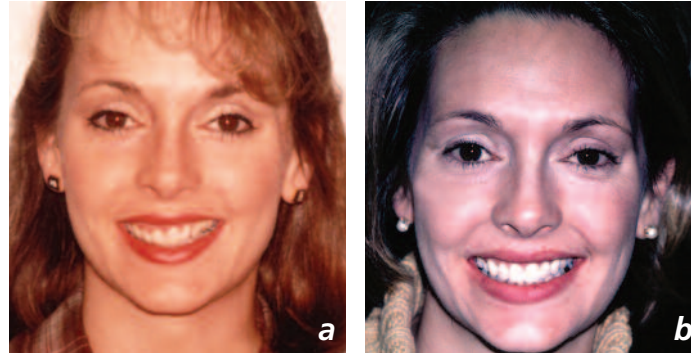
The patient was thrilled with the final esthetic result, and our team was gratified that we could satisfy this patient's objectives with a truly integrated and interdisciplinary approach. The midline deviation has been corrected, the space for the maxillary posterior implant is ideal (Figure 5), the lengths of the maxillary right and left anterior teeth now match one another, and the gingival levels of the contralateral maxillary anterior teeth are commensurate. The amount of gingival display is nearly equivalent during smiling (Figure 6), and the functional occlusion provides the patient with canine protected lateral excursions and adequate overbite to achieve posterior disocclusion in

protrusive excursion.

### Discussion

This patient's treatment illustrates the benefit of interdisciplinary dentistry (Kokich and Kokich 2005, O Connor et al 2000, Spear et al 1997). If the original team had adequately planned and choreographed the treatment initially, this patient would not have been searching for a second opinion. The first team did not discuss all facets of her treatment. They did not create a visual representation of the treatment in the form of a diagnostic wax-up (Kokich and Spear 1997). They did not create a sequence for treatment (Pasquinelli 1999) that included a step-by-step approach for not only the team to follow, but also one that the patient could understand. After all, this patient invested several thousands of dollars in order to achieve her objectives. It is not surprising that she lost trust in the first team. Her treatment was not going well, and her questions could not be answered by the original practitioners. It is simply not reasonable to ask patients to accept an expensive treatment plan that will be performed by several practitioners without first establishing a well-thought-out plan that they can understand and visualise before the treatment actually begins.

A diagnostic wax-up was an integral part of this patient's treatment. However, practitioners often avoid completing



**Figure 6:** Prior to orthodontic treatment, the patient exhibited a maxillary midline deviation, uneven gingival margins, uneven anterior crown lengths, and a 'gummy smile' on the right side. Well-planned and integrated interdisciplinary orthodontic, periodontal, and restorative therapies overcame these original problems and provided the patient with an improved aesthetic and functional result.

this vital step in the treatment planning process and, as a result, never know where their treatment is going. There are probably several reasons that diagnostic wax-ups are not constructed prior to treatment. Among them are time, expense, and lack of experience. The responsibility for the actual construction of the diagnostic wax-up depends upon who is involved in treating the patient. If an orthodontist is part of the treatment plan, then the orthodontist is responsible for constructing the wax-up (Kokich 1993). After all, only the orthodontist knows the amount of tooth movement that is realistic for each patient. The periodontist or surgeon will need to provide information to the orthodontist regarding spacing for implants. The restorative dentist will need to supply the orthodontist with information regarding the proposed restorations and how they affect final tooth position.

Armed with this information, which usually emerges from an interdisciplinary discussion among team members, the orthodontist constructs a realistic representation of the final occlusion based upon the collective input from the other members of the team. When the team approves this wax-up, it represents everyone's vision of where they are heading during their integrated treatment plan.

One of the patient's concerns about the original treatment was the discrepancy in the gingival margins between the right and left maxillary anterior teeth. The reason for the gingival margin discrepancy was a right-side protrusive bruxing habit that produced incisal abrasion of the maxillary right central and lateral incisors and right canine. As the teeth continued to wear with time, they erupted, which moved the gingival margins incisally. The original orthodontist had not recognized this discrepancy, and no effort was being made to correct the crown length

differences.

Generally, there are two ways to correct crown length discrepancies between maxillary anterior teeth: periodontal surgery (Pasquinelli 1999, Allen 1993, Becker et al 1998, Spear 2005) or orthodontic intrusion (Kokich et al 1984, 2001, Kokich 1993, 1996, 2002). In some situations, both techniques are appropriate. The best method for choosing the correct combination of these techniques is first determining the amount of the discrepancy. Previous research has shown that a crown length discrepancy between two central incisors of 1mm or less will generally not be noticed by laypersons (Kokich et al 1999). In the present situation, the discrepancy was nearly 2mm. The second step is to determine if the crown length discrepancy is due to a difference in sulcular depth between contralateral teeth. If so, the clinician must then determine the position of the CEJs of these teeth. If the CEJs are at the same level, but the sulcus depths differ, then the crown length discrepancy is corrected with gingival surgery (Allen 1993, Becker et al 1998). However, if the sulcus depths of contralateral teeth are similar and the CEJs are at different levels, then the crown length discrepancy is corrected by intruding or extruding teeth to level the CEJs, followed by either restoration or equilibration of the incisal edges to create similar crown lengths (Kokich et al 1984, 2001, Kokich 1993, 1996, 2002). In this patient, the sulcus depths differed between right and left maxillary anterior teeth, and the CEJs were also at different levels. Therefore, periodontal surgery was necessary first to create similar biologic widths between the alveolar bone levels and gingival margins of the contralateral anterior teeth. Then, orthodontic intrusion of the shorter maxillary right central incisor, lateral incisor, and canine could level the CEJs of all

anterior teeth.

Intrusion of maxillary anterior teeth produces a discrepancy of the incisal edges. This discrepancy must be corrected either by equilibrating the incisal edge of the longer central incisor or by restoring the incisal edge of the shorter central incisor. The decision about which solution to select should be based upon the width-to-length proportions of these anterior teeth. Previous authors have suggested that a normal range of width-to-length proportion of maxillary central incisors should be somewhere between 70% and 80% (Sterrett et al 1999). If the longer central incisor has a width-to-length proportion of less than 70%, then equilibration is appropriate. If the longer central incisor has a width-to-length proportion of between 70% and 80%, then restoration of the incisal edge of the shorter central incisor would produce the most pleasing aesthetic appearance lengths (Kokich et al 1984, 2001, Kokich 1993, 1996, 2002).

When maxillary anterior teeth are intruded, the principal fibres of the periodontium are stretched and their orientation becomes oblique (Reitan 1967). If the orthodontist simply removes the orthodontic appliances immediately after intrusion, the intruded teeth will re-erupt back to their original position. Therefore, these intruded teeth must be held in that position in order to allow the principal fibres of the periodontal ligament to become reoriented. Although studies of human periodontal ligament fiber reorganisation are not available, researchers have extrapolated from animal research (Reitan 1967) and believe that the process of fibre reorganisation takes at least six months (Kokich et al 1984, 2001, Kokich 1993, 1996, 2002). Therefore, the intruded teeth must be held in position for at least six months after intrusion to ensure a stable vertical tooth position after restoration of the abraded incisors.

The type of restoration for the intruded maxillary right central incisor, lateral incisor, and canine could be either a crown or a veneer. The decision of which type of restoration to choose is based upon several factors. These include the amount of ferrule remaining on the intruded teeth (Spear 2005, Nemcovsky et al 2001), the amount of incisal porcelain necessary to restore esthetics and function, the type of tissue surrounding the crown, and the vitality of the teeth to be restored. In this patient, the teeth were restored with a combination of veneers and all-porcelain crowns based on the existing circumstances.

After the maxillary right central and lateral incisors and canine had been temporarily restored, the next step was to orthodontically move the maxillary dental midline to the

left while the maxillary left posterior space was being partially closed. A major side effect of unilateral orthodontic space closure is tipping of the maxillary anterior teeth during this process. Prior to orthodontic treatment, the tooth contact between the maxillary central incisors was parallel to the long axis of the patient's face. As the maxillary posterior space was closed, the incisors began to tip, and the contact between the maxillary central incisors became oblique and not parallel with the long axis of the patient's face. Previous research<sup>18</sup> has shown that if the interproximal contact is parallel with the long axis of the face, a maxillary dental midline can deviate up to 4mm from the facial midline before laypersons would regard the change as unesthetic. However, if the mediolateral or axial inclination of the central incisor contact deviates by only 2mm, dentists and laypersons would regard the appearance of the teeth as unesthetic. Therefore, during the finishing stages of orthodontics, one of the most difficult aspects to correct was the axial inclination of the anterior teeth. The interproximal contacts were aligned with the long axis of the patient's face and, concomitantly, the maxillary right posterior edentulous space was partially consolidated.

Another concern in the treatment of this patient was the resorbed edentulous ridge in the maxillary left posterior region. Part of this space would be closed during the orthodontic treatment, but what happens when a tooth with a wider root is moved into an edentulous ridge that is narrower than the tooth root? Previous studies have evaluated this question in adult orthodontic patients (Stepovich 1979, Horn and Turley 1984). These studies show that the alveolus has the capacity to remodel as the tooth and its surrounding socket wall are moved into this narrower alveolar ridge. Bone will form over the root of the tooth in response to this remodeling process. Although the limitations of this type of tooth movement have not been tested experimentally, a guide would be the relative width of the edentulous ridge compared to the width of the root being moved into the ridge. If the edentulous ridge were at least half the width of the tooth being moved into that ridge, then the remodeling process would probably be successful (Kokich and Kokich 2005). However, if the edentulous ridge is less than half the width of the tooth root, then a dehiscence in the bone could form over the labial or lingual surfaces of the tooth root. In this patient, no dehiscence occurred after the edentulous space was partially closed to facilitate single-tooth implant placement.

After partial space closure, the remaining edentulous ridge was too narrow to receive an implant. Therefore, ridge augmentation was necessary. Several procedures

were possible to create a wider ridge for placement of the implant. These included splitting the ridge with an osteotome and placement of an autogenous bone graft, allograft, or xenograft (Nevins and Mellonig 1992, Buser et al 1993, Jovanovic and Nevins 1995, Summers 1994). In this patient, freeze-dried cadaver bone was selected for the ridge augmentation procedure. A non-resorbable, titanium-reinforced membrane was used as a barrier to enhance bone augmentation. In these situations, it is usually necessary to place the bone graft first, followed by a period of remodeling lasting approximately nine months. At that point, the graft is not completely remodeled, but the implant can be placed so that ridge resorption can be prevented during the remaining remodeling process.

When implants are placed in partially remodeled cadaver bone, the integration period for the implant increases. This is especially true in the maxilla, where the bone is more cancellous. In this patient, the implant was allowed to integrate for six months prior to restoration to ensure that the osseointegration process was complete.

The timing of the bone grafting and implant placement was intentionally sequenced during the orthodontic treatment, immediately after the maxillary left edentulous space had been partially closed. One advantage of performing the bone augmentation and implant placement during the finishing stages of the orthodontic treatment was to reduce the amount of time required to retain the edentulous space with a removable retainer after the orthodontic treatment. By placing the implant during active orthodontics, the provisional restoration could be placed soon after bracket removal. Another advantage was reducing the total treatment time for the patient.

### Conclusion

This case report illustrates a common problem that affects all dentists (i.e., inheriting a patient who is undergoing treatment with a team of dentists and specialists but is unhappy with the progress of the therapy). The points illustrated in this article emphasize the need for the team of orthodontist, periodontist, surgeon, and restorative dentist to completely understand the patient's goals and expectations. With this understanding, the treatment alternatives available to achieve these goals and expectations should be discussed. The team can then select the treatment alternative that has the least disadvantages. Once the general plan has been identified, a vision of the end result must be constructed in the form of a diagnostic wax-up. This representation of the proposed treatment plan will allow the team to create the sequence of steps

necessary for its completion. It will provide the patient with a much better understanding of what will take place and how, leading to acceptance of the treatment process. The result is a satisfied, happy patient and team members who experience personal satisfaction from knowing that their efforts were successful. We call this approach interdisciplinary dentistry.

*This paper was previously published in:  
Advanced Esthetics & Interdisciplinary Dentistry  
Vol. 1, No.3, 2005  
Aesthetic Dentistry Today Vol 3, No 4*

### References

1. Pasquinelli KL. Periodontal Plastic Surgery. J Calif Dent Assoc. 1999;27:597-610.
2. Nevins M, Mellonig JT. Enhancement of the damaged edentulous ridge to receive dental implants: a combination of allograft and the GORE-TEX membrane. Int J Periodontics Restorative Dent. 1992;12:96-111.
3. Buser D, Dula K, Belser U, et al. Localized ridge augmentation using guided bone regeneration. I: Surgical procedure in the maxilla. Int J Periodontics Restorative Dent. 1993;13:29-45.
4. Simion M, Trisi P, Piattelli A. GBR and an e-PTFE membrane associated with DFDBA: histologic and histochemical analysis in a human implant retrieved after 4 years of loading. Int J Periodontics Restorative Dent. 1996;16:338-347.
5. Allen EP. Surgical crown lengthening for function and esthetics. Dent Clin North Am. 1993;37:163-179.
6. Becker W, Ochsenein C, Becker BE. Crown lengthening: the periodontal-restorative connection. Compend Contin Educ Dent. 1998;19:239-240, 242.
7. Kokich VG, Kokich VO. Interrelationship of orthodontics with periodontics and restorative dentistry. In: Nanda, R. Biomechanics and Esthetic Strategies in Clinical Orthodontics. St. Louis: Elsevier Saunders; 2005:18.
8. O Connor RV. The exciting world of interdisciplinary dentistry. Int J Periodontics Restorative Dent. 2000;20:334-335.
9. Spear FM, Mathews DM, Kokich VG. Interdisciplinary management of single-tooth implants. Semin Orthod. 1997;3:45-72.
10. Kokich VG, Spear FM. Guidelines for managing the orthodontic-restorative patient. Semin Orthod. 1997;3:3-20.
11. Kokich V. Esthetics and anterior tooth position: an orthodontic perspective. Part III. Mediolateral relationships. J Esthet Dent 1993;5:200-207.

- 12.Spear F. Margin placement for anterior esthetic restorations. *Adv Esthetic Interdisc Dent.* 2005;1:4-9.
- 13.Kokich VG, Nappen DL, Shapiro PA. Gingival contour and clinical crown length: their effect on the esthetic appearance of maxillary anterior teeth. *Am J Orthod.*1984;86:89-94.
- 14.Kokich V. Esthetics and anterior tooth position: an orthodontic perspective. Part I. Crown length. *J Esthet Dent.* 1993;5:19-23.
- 15.Kokich VG. Esthetics: the orthodontic-periodontic restorative connection. *Semin Orthod.* 1996;2:21-30.
- 16.Kokich VG, Kokich VO, Spear F. Maximizing anterior esthetics: An interdisciplinary approach. In: McNamara JA, Kelly K, Jr., et al, eds. *Frontiers in Dental and Facial Esthetics.* Ann Arbor, MI: University of Michigan; 2001.
- 17.Kokich V. The role of orthodontics as an adjunct to periodontal therapy. In: Newman M, Takei H, Carranza F, eds. *Carranza's Clinical Periodontology*, 9th ed. Philadelphia: W.B. Saunders; 2002:704-718.
- 18.Kokich VO Jr, Kiyak HA, Shapiro PA. Comparing the perception of dentists and lay people to altered dental esthetics. *J Esthet Dent*, 1999;11:311-324.
- 19.Sterrett JD, Oliver T, Robinson F, et al. Width / length ratios of normal clinical crowns of the maxillary anterior dentition in man. *J Clin Periodontol.* 1999;26:153-157.
- 20.Reitan K. Clinical and histologic observations on tooth movement during and after orthodontic treatment. *Am J Orthod.* 1967;53:721-745.
- 21.Nemcovsky CE, Artzi Z, Moses O. Preprosthetic clinical crown lengthening procedures in the anterior maxilla. *Pract Proced Aesthet Dent.* 2001;13:581-588.
- 22.Stepovich ML. A clinical study on closing edentulous spaces in the mandible. *Angle Orthod.* 1979;49:227-233.
- 23.Hom BM, Turley PK. The effects of space closure of the mandibular first molar area in adults. *Am J Orthod.*1984;85:457-469.
- 24.Jovanovic SA, Nevins M. Bone formation utilizing titanium-reinforced barrier membranes. *Int J Periodontics Restorative Dent.* 1995;15:56-69.
- 25.Summers RB. The osteotome technique: Part 2. The ridge expansion osteotomy (REO) procedure. *Compend Contin Educ Dent.* 1994;15:422,424