

Bonding of an orthodontic tube to provisional prosthetic crowns: A technical procedure

Matheus Melo Pithon

Introduction

Orthodontists are often confronted with the presence of osseointegrated implants replacing posterior teeth in patients undergoing orthodontic treatment. Attaching the orthodontic appliance onto these dental implants depends on the proposed treatment plan.

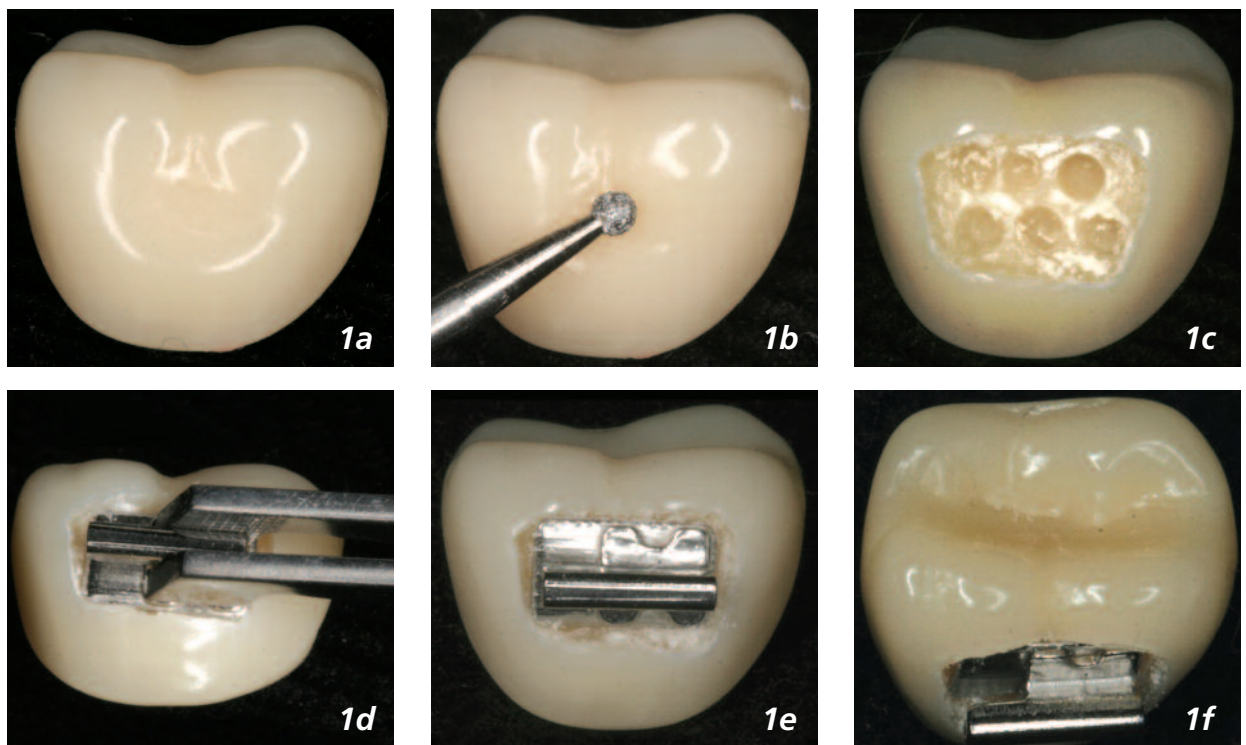
According to the type of proposed rehabilitation, provisional prosthetic implant crowns can be single or connected.^{1,2} In the former case, orthodontic bands can be placed on the implant crowns. On the other hand, a problem emerges when the crowns are connected. A

possible solution is to bond tubes, despite the higher debonding rate on, posterior teeth.³⁻⁵

In the attempt to find an alternative approach, this article describes a simple and effective technique for attaching orthodontic molar tubes to connected prosthetic crowns.

Procedure

This technique consists of making a groove on the provisional prosthetic crown (Figure 1a) of the teeth being bonded using a high-speed diamond drill (Figure 1b). This groove should be slightly larger than the base of the tube



Doctor of Orthodontics at the School of Dentistry, Federal University of Rio de Janeiro – UFRJ, Brazil
Address for Correspondence: Rua México, 78
Vitória da Conquista, Bahia, Brazil
CEP: 45020-390. E-mail: matheuspithon@bol.com.br

Figure 1a: Prosthetic crown; 1b – groove made by diamond drill; 1c – groove with retentions; 1d – insertion of tube inside the groove; 1e – tube bonded inside the groove; 1f – upper view of the tube;

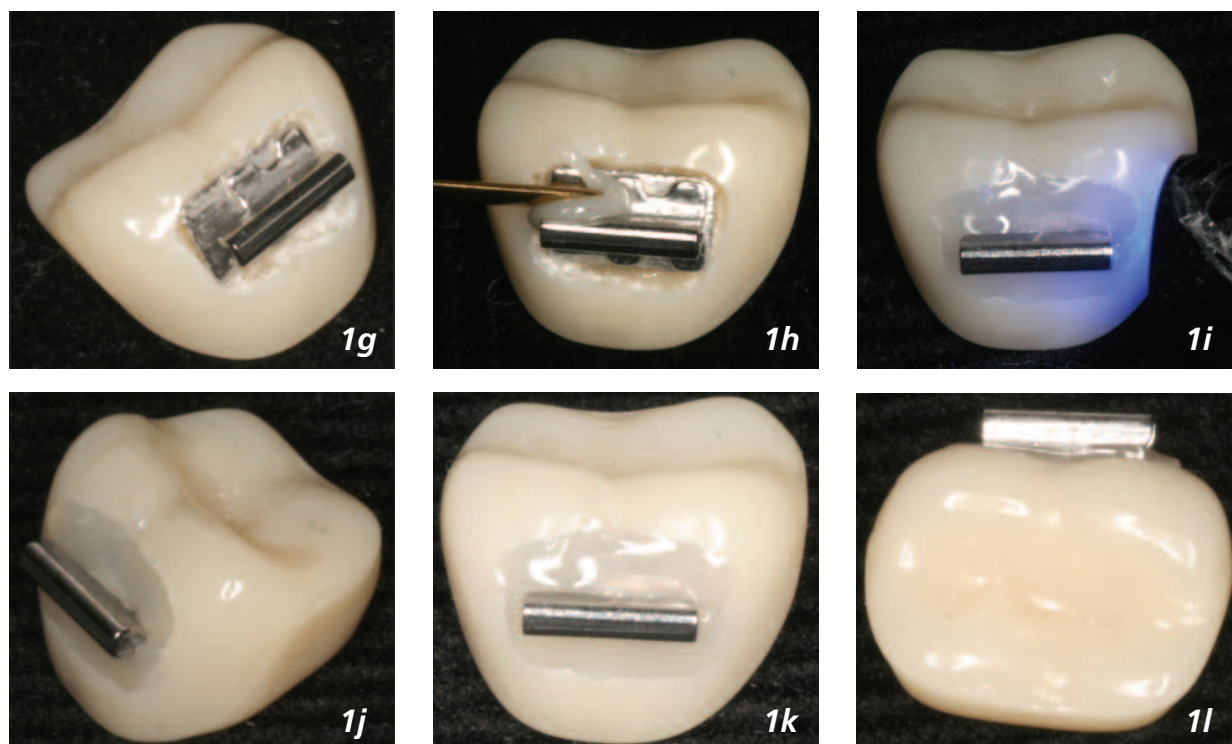


Figure 1g: lateral view of the tube; 1h – tube’s base being covered; 1i – light-curing of resin composite; 1j – lateral view of bonded tube; 1k – frontal view; and m – occlusal view.

to facilitate its adjustment.

Making retentions in the bottom of the groove was thought to be important to provide a greater bond strength (Figure 1c). Furthermore, the groove had to accommodate the base of the tube inside its inner wall (Figure 1e-g). A light-curing resin composite is then applied (Figure 1h). After light-curing (Figure 1i), the tube is ready to be subjected to masticatory and orthodontic forces (Figure 1j-m and Figure 2).

The advantage of this method is that the improved retention provided by the groove decreases the possibility of bracket debonding, which causes discomfort and delay in orthodontic treatment.

References

1. Adeyemi AA, Lyons MF, Cameron DA. The acrylic tooth-denture base bond: effect of mechanical preparation and surface treatment. *Eur J Prosthodont Restor Dent* 2007;15:108-114.
2. Youn YA, Lee YK, Lee DY, Kim NY, Lim YK. Effect of surface treatment and type of cement on the retentive strength of orthodontic bands on gold alloy crowns. *Am J Orthod Dentofacial Orthop* 2007;132:728 e721-726.
3. Ulusoy C, Irmak O, Bagis YH, Ulusoy OI. Temperature rise and shear bond strength of bondable buccal tubes bonded by various light sources. *Eur J Orthod* 2008;30:413-417.
4. Berk N, Basaran G, Ozer T. Comparison of sandblasting, laser irradiation, and conventional acid etching for orthodontic bonding of molar tubes. *Eur J Orthod* 2008;30:183-189.
5. Chung K, Hsu B, Berry T, Hsieh T. Effect of sandblasting on the bond strength of the bondable molar tube bracket. *J Oral Rehabil* 2001;28:418-424.

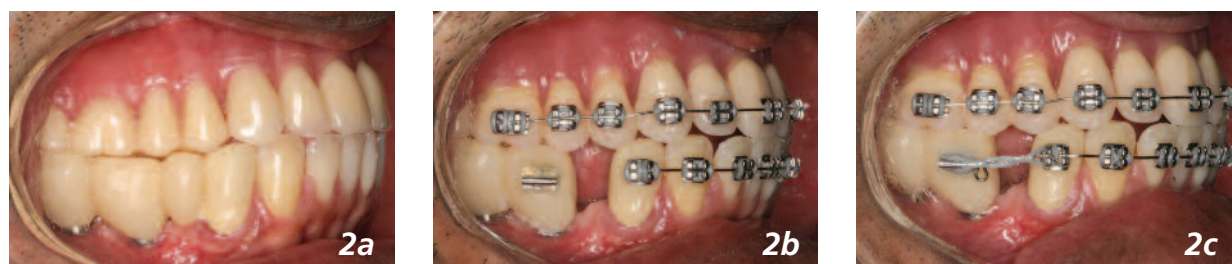

Figure 2a: Lateral view of the arch prior to attaching the orthodontic appliance; 2b – bonded tube; 2c – tube supporting orthodontic arch and elastic force of 180 gf.