

# IMPLANT SUPPORTED MILLED BAR MANDIBULAR OVERDENTURE WITH LOCATOR ATTACHMENTS: CLINICAL CONSIDERATIONS AND LABORATORY TECHNIQUES

SAAD A. AL-HARBI

## Abstract

Both fixed and removable implant-supported restorations successfully address problems associated with complete dentures in edentulous mandibles. Implant-supported overdentures are frequently the restoration of choice in complex restorative situations where facial support is needed or when cost is of primary concern to the patient. Two implant overdentures with isolated or bar and clip attachments may be considered in the treatment of elderly patients. However this design allows a significant amount of rotation and vertical movement which may be limited in its use in patients with dentate maxilla, severe alveolar bone loss, sensitive mucosa or with high retention and stability needs. This report describes a technique which combines a milled bar with a locator attachment for a patient with a dentate maxilla who suffers from a sensitive mandibular alveolar ridge mucosa. The use of this design provided the patient with stability and retention.

## Introduction

The successful use of endosseous dental implants in the treatment of mandibular edentulism is well-documented for both fixed and removable prosthodontic reconstructions.<sup>1-6</sup> Both fixed and removable implant-supported restorations successfully address problems associated with complete dentures in edentulous mandibles.<sup>1,2,6</sup> Implant-supported overdentures are frequently the restoration of choice in complex restorative situations where facial support is needed or when cost is of primary concern to the patient. They are relatively simple to construct, can restore both dental and alveolar tissues, are economical and are able to satisfy the esthetic demands of complex restorative situations.<sup>3,4</sup> Available research on the clinical performance of implant supported overdentures with one to twelve-year follow-up data reports success rates approaching 100%.<sup>4,5,7</sup>

Implant overdentures vary in design, according to the method of attachment and amount of support to be derived from implant and ridge mucosa.<sup>8</sup> No absolute rules have been established for overdenture case design with dental implants. Patient demand, biomechanical principles, the amount of available restorative space and financial capabilities of the

Saad A. Al-Harbi, BDS, MSci  
Consultant Implant And Prosthetic Dentistry, Retal Clinic, Jeddah, Saudi Arabia  
Research Fellow, University of Texas Health Science Center San Antonio, Dental School, San Antonio, Texas

Mailing address:  
RETAL CLINC, P. O. BOX 126242, JEDDAH 21352, SAUDI ARABIA,  
E-mail: amharbi@hotmail.com

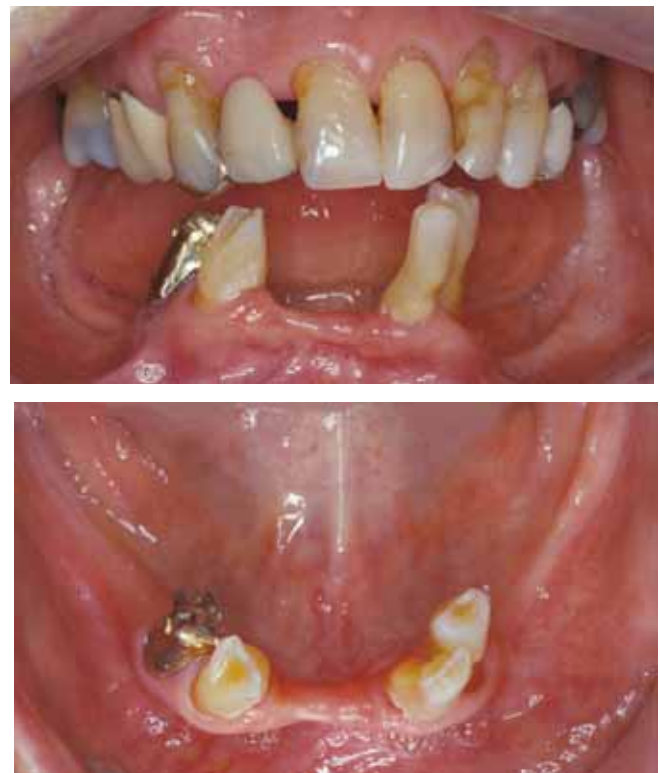

Figure 1a and b: Initial presentation. a, frontal view. b, occlusal view.

patient all contribute to the determination of the overdenture design.<sup>9</sup> Two implant overdentures with isolated or bar and clip attachments may be considered in the treatment of elderly patients<sup>10</sup> and have shown greater patient satisfaction when compared to conventional complete dentures.<sup>11-13</sup> However this

design allows a significant amount of rotation and vertical movement and requires an optimal extension and fit of the denture base for functional success.<sup>14</sup> Its use in patients with dentate maxilla, severe alveolar bone loss, sensitive mucosa, or with high retention and stability needs.<sup>14-17</sup> may thus be limited. Four to six implants, splinted with a bar, are usually prescribed to achieve a sufficient amount of support, stability and retention.<sup>18</sup> In this type of prosthesis, more support is derived from the implants than the alveolar ridge mucosa where pressure is minimized, eliminating the need for a denture base extension.<sup>16</sup> A variety of prefabricated bar designs exist. However, due to a lack of accurate adaptation of the denture base to the bar superstructure, rotation and lateral movement of the denture are unavoidable. Electrical Discharge Machining (EDM) and spark erosion can be used to improve the fit of overdenture framework<sup>19</sup>, but this procedure is costly and technique-sensitive.<sup>20</sup> Milled bars have been suggested as a less expensive alternative to EDM.<sup>21-23</sup> Unlike prefabricated bars, a custom-fabricated bar could be accurately milled to develop guide planes that allow accurate adaptation of the denture base to the milled bar providing stability and resistance against rotational and lateral forces.<sup>23-25</sup> Custom-made bars are also more likely to follow the ridge shape when pronounced ridge curvature is encountered, without invading the tongue space. Incorporating an attachment system of choice is another advantage of using this bar design. Several attachment systems are available in the market, such as O-rings, ball attachments, ERA and locator attachments. All available attachment systems are designed to prevent vertical movement of the denture, and can be used as an isolated attachment mounted directly to the implant or attached to a bar system. No scientific data that support the use of one attachment system over another is available<sup>26,27</sup>. However incorporating a locator attachment as a retentive component has several advantages over other systems. Locator attachments provide dual retention through both external and internal mating surfaces, a self-aligning feature which is helpful in guiding patients when placing their denture and can be combined with guide planes on a milled bar for a common path of insertion. Furthermore, cast-to-locator has a vertical height of 2.5mm that allows bar fabrication of adequate strength, especially in cases of reduced vertical inter-arch space. Locator attachments require low maintenance and offer high durability and long lasting performance for over 60,000 insertion cycles (equivalent to 10 years of clinical function).<sup>28</sup>

This report describes a technique where a milled bar is combined with a locator attachment in a patient with a dentate maxilla who suffers from a sensitive mandibular alveolar ridge mucosa.

### Case history

A 65-year-old healthy woman with a dentate maxillary arch and partially edentulous mandibular arch presented for

treatment. Her chief complaint was pain in the mandibular ridge mucosa due to her existing mandibular partial denture (RPD). The patient reported several unsuccessful attempts at relining her mandibular RPD in an effort to relieve her symptoms. She expressed a desire for a removable denture that was stable and comfortable.

### Diagnosis and Treatment planning

Clinical and radiographic evaluation revealed a maxillary dentition

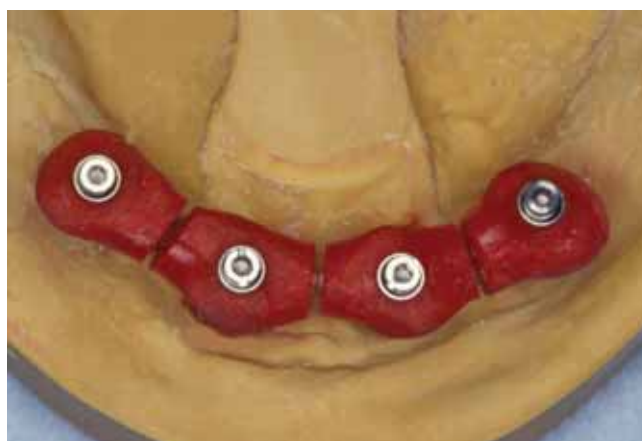


Figure 2a: Open tray impression coping splinted with autopolymerized acrylic resin and sectioned vertically to allow reassembly in the patient's mouth.

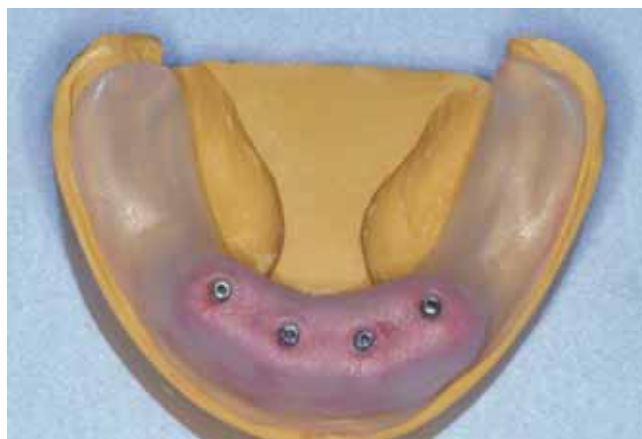

Figure 2b: Impression tray with individual opening to each guiding pin.

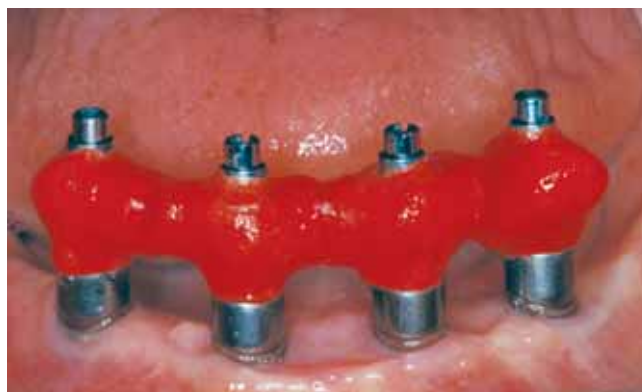

Figure 2c: Open tray impression copings placed on corresponding implants and reassembled in the patient's mouth using an autopolymerized resin.

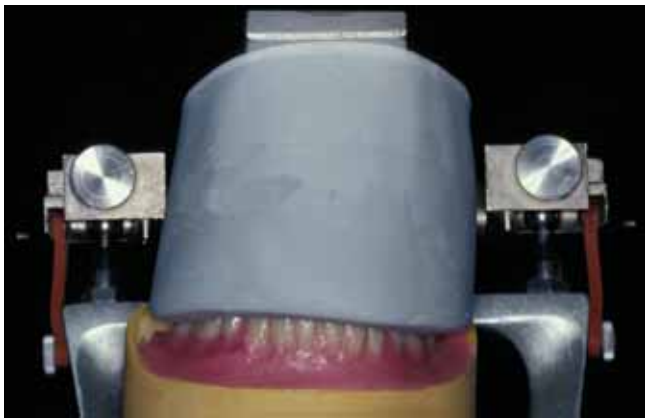


Figure 3: Occlusal silicon index covering the incisal and occlusal half of the teeth mounted to the upper member of the articulator.

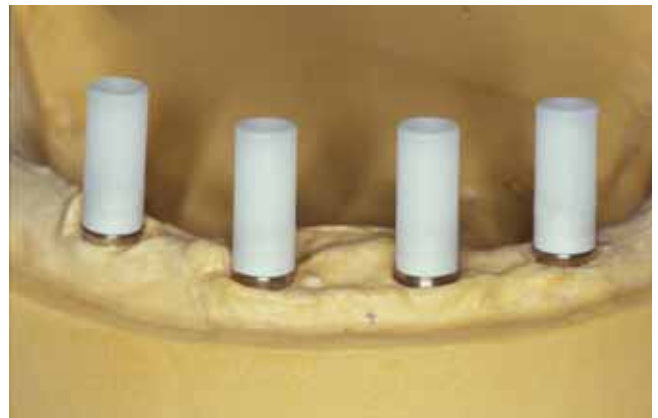


Figure 4: UCLA-type abutments screwed to the implant fixture analogues.

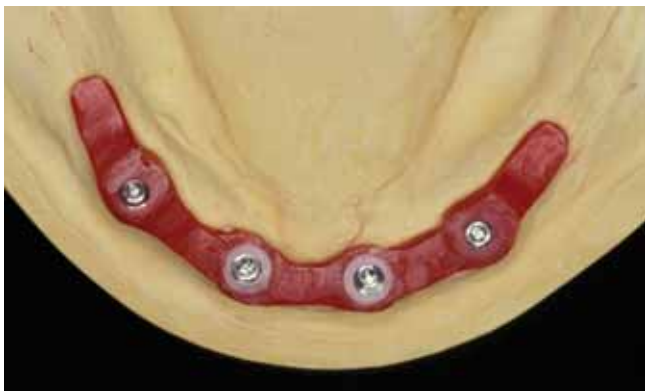

Figure 5: Bar pattern developed initially to ideal contour on the master cast.

that was in need of periodontal maintenance, with remaining mandibular teeth which had severe bone loss and increased mobility. However, an adequate band of attached gingiva and anterior mandibular ridge of acceptable dimension for implant placement was present (Figure 1, a and b). The posterior mandibular ridges exhibited severe bone loss and a deficiency in both height and width. Diagnostic impressions were made. Diagnostic teeth set-up at appropriate vertical dimensions was done to assess the available restorative space, jaw relationship and teeth position for the best esthetic and function results. Based on the diagnostic work-up, a Class I skeletal relationship existed and 15mm of restorative space was available.

After discussing the clinical and radiographic findings with the patient, the following decisions were made: extraction of the remaining mandibular teeth; alveoloplasty to eliminate the knife edge coronal portion of the anterior mandibular ridge; placement of four root form implants in the inter-foramina area of the mandible and a milled bar-supported, locator-retained overdenture as a definitive prosthesis.

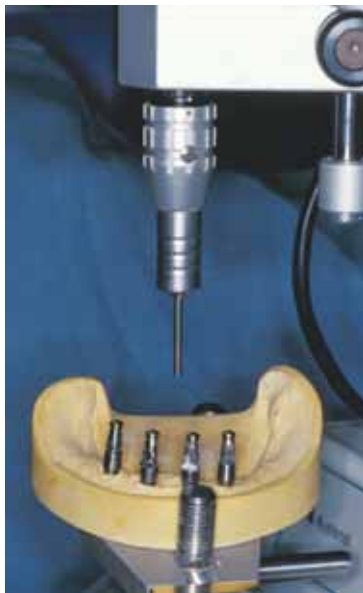### Surgical implant placement

Optimal surgical implant positioning is essential for the success of implant supported restorations. Properly placed, distributed and aligned fixtures allow for axial loading of the implants and the incorporation of prosthetic components without compromising the esthetic, contours and hygiene space of the restoration.<sup>29</sup> A detailed description of the proposed implant

positions and distribution was provided to the implant surgeon together with a surgical guide fabricated from the diagnostic work-up. The position, distribution and number of implants to be placed were determined based on the predesigned restoration, the available ridge dimension, and the limitation of the anatomical structures. Adequate inter-implant distance should be maintained to allow adequate space for incorporation of the retentive components. Based on the available ridge dimension and the position of the mental foramina four 3.75 X 15 Brånemark MK III TiUnite implants (Nobel Biocare Inc, Carlsbad, CA, USA) were placed in the anterior mandible maintaining a 10mm distance. A 10mm inter-implant distance from center to center allowed for a 4mm locator female attachment and 3mm on each side. Healing abutments of 5mm height (Nobel Biocare Inc, Carlsbad, CA, USA) were fastened to the implants to allow undisturbed soft tissue healing and to provide stability for the immediate restoration. Immediate dentures made of the diagnostic work-up were placed in the patient's mouth. The intaglio surface of the denture was relieved, to allow enough room for the application of the soft tissue conditioning material while avoiding direct contact between the denture acrylic and the healing abutments. Soft tissue conditioning material (Tokuyama, Tokuyama Dental Corp, Tokyo, Japan) was applied to the intaglio surface of the denture according to the manufacture's directions and the excess liner material trimmed. The denture was finished, polished and inserted into the patient's mouth. The patient was seen on a regular follow-up visits and the denture relined as needed.

### Prosthodontic procedures

Accurate transfer of the implants position to the master cast is a primary requirement to insure a passive fit restoration. An impression procedure that implements a ridge splinting of the impression coping is therefore recommended.<sup>30,31</sup> For an accurate master impression, open tray impression copings (Nobel Biocare Inc, Carlsbad, CA, USA) were mounted to the primary cast implant analogues and splinted with autopolymerized acrylic resin (GC Pattern Resin, GC Corp, Tokyo, Japan). The resin splint then sectioned vertically



*Figure 6a: A common path of insertion is determined by surveying the master cast on the milling machine surveying table.*



*Figure 6b: Impression copings splinted to the milling machine at the established path of insertion.*

between the impression copings to allow accurate reassembly in the patient mouth (Figure 2a). A custom tray (Triad, Dentsply Int Inc, York, PA, USA) was fabricated with occlusal openings to allow individual access to each guide pin (Figure 2b). At the time of taking the master impression, the open tray impression coping with the acrylic index was brought to the patient's mouth, screwed to the corresponding implant and reassembled with the addition of an autopolymerized resin (GC Pattern Resin, GC Corp, Tokyo, Japan) (Fig.2,C). The resin was allowed to reach final setting and a rubber base impression (Kerr Dental, Romulus, MI, USA) was made. The guide pins were loosened and the impression removed from the patient's mouth. The implant analogues (Nobel Biocare Inc, CA, USA) were placed and the impression poured in improved dental stone (Microstone, Whip Mix Corp, Louisville, KY, USA). A record base incorporating two non-engaging temporary cylinders (Nobel Biocare Inc, Carlsbad, CA, USA) was fabricated using light polymerized acrylic resin (Triad, Dentsply Int Inc, York, PA, USA). Jaw relation was recorded by injecting vinyl polysiloxane (Regisil 2x, Dentsply Int Inc, Milford, DE, USA) while manipulating the patient's mandible into a centric relation position. The master cast was then mounted on a semi-adjustable articulator and a teeth set-up incorporating a group function occlusion on lateral mandibular excursion was made and tried for patient approval. Esthetic, phonetics and vertical dimension of occlusion were evaluated. An occlusal silicon index (Sil-Tech, Ivoclar Vivadent, Amherst, NY, USA) incorporating the incisal edges and the occlusal half of the mandibular denture teeth set-up was fabricated and mounted to the upper member of the articulator (Figure 3). The occlusal silicon index would be used during bar fabrication procedures to facilitate accurate repositioning of the denture teeth in relation to the master cast.

### Milled bar construction

To simplify the laboratory procedure of the milled bar construction, the fabrication process is presented in a step-by-



*Figure 6c: Implant fixture analogues mounted to the impression coping and a stone index made on the magnetic table of the milling machine to form a fixed stone index.*

step manner to allow easy replication by clinicians and laboratory technicians who are interested in using this type of prosthesis in their patients. The following steps were used when fabricating the milled bar with locator attachment in our patient:

- UCLA-type abutments (3i, Palm Beach Gardens, FL, USA) are screwed to the master cast implant analogues and cut to appropriate height (Figure 4).
- A bar pattern is built using autopolymerized resin (GC Pattern Resin, GC Corp, Tokyo, Japan). The amount of the available restorative space, hygiene requirements and biomechanical principles govern the developed bar dimension.
- The bar pattern should be built to a 4mm height to allow the development of adequate guide plans<sup>20</sup>, a 5mm width to accommodate the locator attachment, a 10-12mm distal extension to prevent fatigue fracture of the cantilevered portion of the bar<sup>9</sup>. (Figure 5)
- A 1.5mm hygiene space should be maintained under the bar to allow easy access by the patient .
- The bar pattern is removed and the impression copings mounted to the master cast, which is transferred to the surveyor table of the milling machine.
- A common path of insertion must be established (Figure 6a). The determination of a common path is essential for the



Figure 7: Bar pattern secured to the implant analogues in the stone index and milled to 4 degrees using a laboratory carbide milling bur.




Figure 8: Parallel placement of the locator cast-to female using the paralleling plastic post.

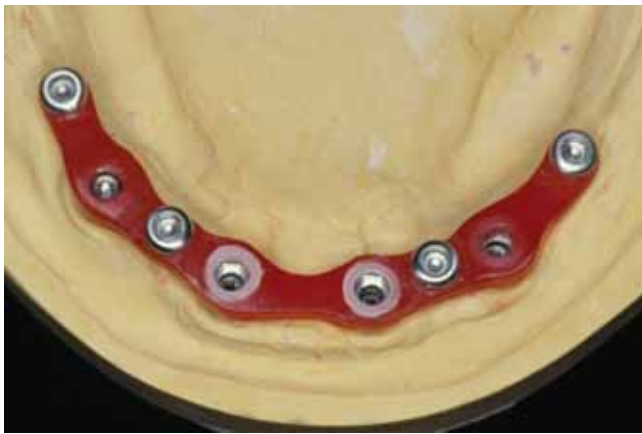

Figure 9: Bar pattern incorporating the locator cast-to female ready for casting procedures.

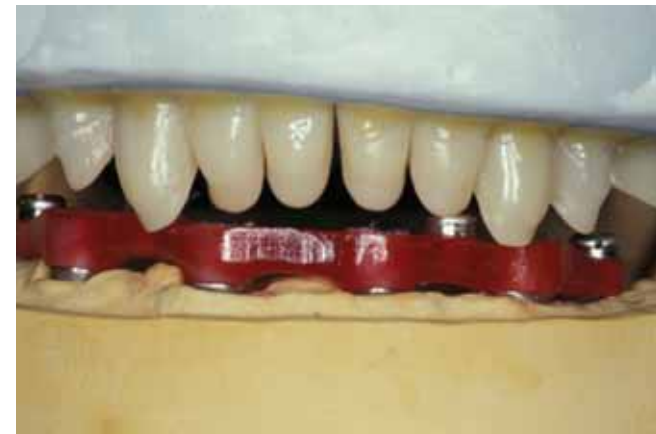

Figure 10: Bar pattern secured to the master cast. The master cast and occlusal silicon index is mounted to the articulator to verify the relationship of the bar to the denture flanges and teeth.



Figure 11: Completed milled bar secured to the master cast. White block-out rings were placed and a metal housing/black processing male cap snapped on each cast-to female part. Undercuts were blocked out using dental stone.

accurate development of guide planes on the milled bar and for the placement of locator retentive components.

- An old acrylic bur is mounted to the milling machine handpiece and the impression copings rigidly splinted to allow the accurate transfer of the implant analogues positions to the stone index at the established path of insertion (Figure 6b).

- The master cast is removed, the impression coping unscrewed, implant analogues attached and replaced on the milling machine indexing table. A mounting stone is poured to form a fixed stone index (Figure 6c).
- The bar pattern is secured to the stone index on the milling machine table and, using a 4-degree tapered milling bur, a guide plane is created on both lingual and facial sides of the bar pattern (Figure 7).
- The milling bur is replaced with an appropriate size round bur, and a hole drilled through the bar pattern to allow accurate positioning of the locator cast-to female components.
- The locator paralleling plastic post (provided with locator cast-to female) is mounted to the milling machine handpiece and the stainless steel locator cast-to females placed on the superior aspect of the bar pattern (Figure 8). Ensuring a parallel placement of the attachment to the path of insertion is essential to ensure a longer life span of the attachment and ease of insertion for the patient.
- The locator female attachment is secured to the bar pattern using autopolymerized acrylic resin. Special attention should be given to ensure accurate adaptation of the locator female

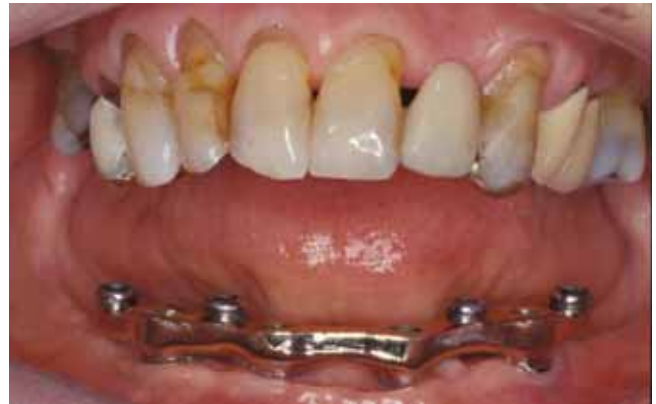
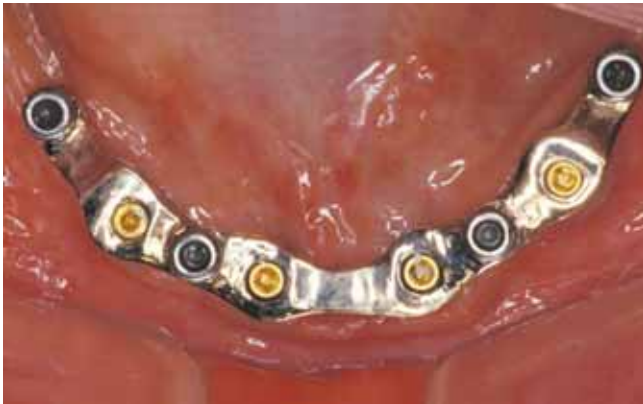
Figure 12: Bar seated in the patient's mouth. 12 a: Frontal view. 12b: Occlusal view.

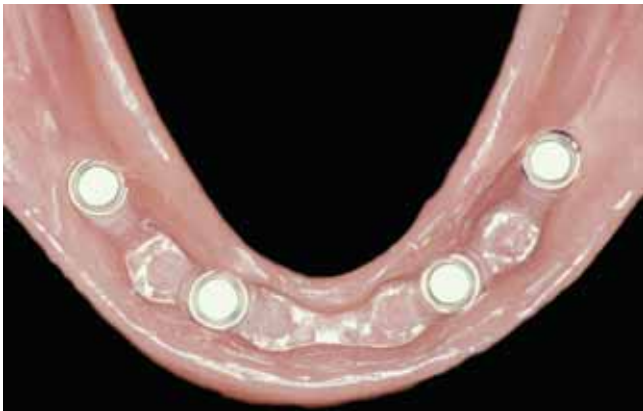


Figure 13: A close-up of the intaglio surface of the denture showing an accurate replication of the milled bar surface in the denture-base resin.

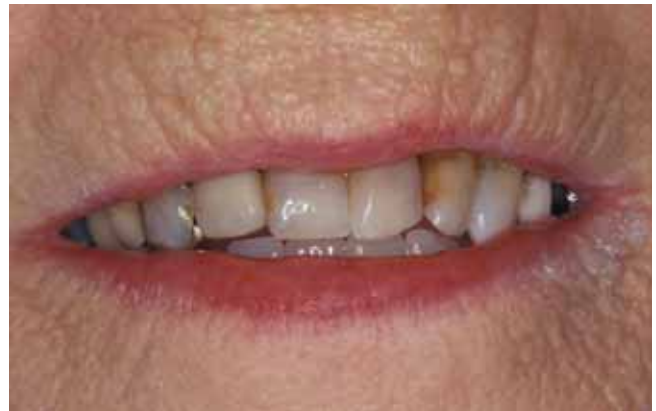

Figure 14: Smile view with overdenture in place.

component to the bar surface in order to prevent casting porosity (Figure 9).

- The milled bar pattern is secured to the master cast and the relationship of the bar pattern to the denture flange and teeth verified by replacing the silicon index and the master cast on the articulator (Figure 10).
- The bar pattern is sprued, invested and cast in type IV gold alloys or an alloy of choice.
- After divesting and cleaning the casting, the sprues are removed and, under magnification, any casting irregularities removed. The bar is secured to the milling machine table, the milled surfaces refined and any present irregularities removed. Finish and polish to a high shine using appropriate laboratory procedures.
- The fit of the restoration is then verified using a single screw test.<sup>32</sup> If the implant abutment junctions are not visible a periapical radiograph can be taken to verify the fit.
- The bar is seated to the master cast. White block-out spacer is placed on the female locator components and the metal housing/black processing male cap snapped on. The undercuts are blocked out using dental stone (Resin Rock, Whip Mix Corp, Louisville, KY, USA). Milled surfaces should

be exposed to allow accurate adaptation of the denture acrylic to the milled bar (Figure 11).

- The master cast and silicon index are replaced back on the articulator and the denture waxed-up to the final form. The denture is then flaked and processed in heat polymerized acrylic resin.
- Finish and polish using appropriate laboratory procedures.

#### Placement of completed prosthesis

The finished bar is brought to the patient's mouth, seated and the abutment screws (Gold-tite uniscrew, 3i, Palm Beach Gardens, FL, USA) torqued down to 32 Ncm according to the manufacturer's directions (Figure 12a and b). The screw opening is obturated with a light polymerized composite resin (Fermit, Ivoclar Vivadent, Amherst, NY, USA). The denture is then tried, fitted and extensions adjusted in the usual manner. The intimate fit of the intaglio surface of the denture to the milled bar may provide enough retention for the prosthesis during this procedure (Figure 13). Centric relation records were obtained and a laboratory remount for final occlusal refinement was done. The male processing cap was removed and replaced with a light retention replacement male cap (Zest

Anchor). Male caps of different retention force are available from the manufacture, giving the clinician the opportunity to select the amount of retention force that best meets the patient's demands and expectations. It is advised that the amount of retention is increased gradually according to the patient's needs and manual capability.

Home care instructions were discussed with the patient who was then trained on the insertion and removal of her new denture. At a one week follow-up the patient was satisfied with the amount of the retention and stability provided and satisfied with her new denture (Figure 14).

## Discussion

Thorough evaluation and treatment planning that addressed the patient's needs, expectations, clinical and radiographic findings resulted in a provision of the final restoration design that met our patient functional and esthetic needs. The patient's desire to have a stable removable overdenture with minimal extension and the least amount of pressure on the alveolar ridge mucosa as well as the presence of adequate restorative space to accommodate a milled bar with locator attachment without compromising the integrity of the bar design or the thickness of denture base or the position of the denture flanges and teeth led to the choice of this design. The need to have an overdenture design of superior stability and retention was recognized at an early stage of the treatment plan, allowing implant placement with optimal distribution. The use of a milled bar with accurately developed guide planes allowed intimate adaptation of the denture base to the milled bar providing a great amount of stability and resistance against rotational and lateral forces. Incorporating a locator attachment provided the patient with sufficient retention to prevent vertical movement of the denture. As it shares a common path of insertion with the milled bar, a longer performance of the retentive plastic components can be expected. Moreover, the subsequent reduction in the number of clinical visits needed for attachment maintenance is more convenient to the patient. Due to the exceptional stability of milled bar system and the adequate number of implants used, the extension of the overdenture base was kept to the minimum, which can be especially beneficial to patients with a gag reflex. This design may also be indicated in patients with dentate maxilla, severe alveolar bone loss, sensitive mucosa, or with high retention and stability needs.

## Summary

The clinical and laboratory steps for fabricating a milled bar implant supported overdenture with a locator attachment has been presented in this article. This design is cost effective and simple, but provides an exceptional stability and retention.

## References

1. Adell R, Lekholm U, Rockler B, et al. A 15-Year study of osseointegrated implants in the treatment of the edentulous jaw. *Int J Oral Surg.* 1981;10 :387-416.
2. Lindquist LW, Carlsson GE, Jemt T. A prospective 15-year follow up study of

mandibular fixed prostheses supported by osseointegrated implants. *Clinical results and marginal bone loss. Clinical Oral Impl Res.* 1996; 7:329-336.

3. Engquist B, Bergendal T, Kallus T, et al. A retrospective multicenter evaluation of osseointegrated implants supporting overdenture. *Int J Oral Maxillofac Implants.* 1988; 3: 129-134.

4. Jemt T, Chai J, Harnet, J, et al. A 5-Year prospective multicenter follow-up report on overdenture supported by osseointegrated implants. *Int J Oral Maxillofac Implants.* 1996; 11: 291-298.

5. Neart I, De Clercq M, Theuniers G, et al. Overdentures supported by osseointegrated fixtures for the edentulous mandible: A 2.5-Year report. *Int J Oral Maxillofac Implants.* 1998; 3: 191-196.

6. Albrektsson T. A multicenter report on osseointegrated oral implants. *J Prosthet Dent.* 1988; 60:75-84.

7. Attard NJ, David LA, Zarb GA. Immediate loading of implants with mandibular overdentures: one-year clinical results of a prospective study. *Int J Prosthodont.* 2005;18:463-70.

8. Burns DR. Mandibular implant overdenture treatment: Consensus and controversy. *J Prosthodont.* 2000; 9:37-46.

9. English CE. Bar patterns in implant prosthodontics. *Implant Dent.* 1994; 3:217-229.

10. Feine J, Carlsson G. Implant overdentures the standard of care for edentulous patients. Quintessence Publishing Co Inc. 2003:155-157.

11. Wismeijer D, Waas M, and Vermeeren J. Overdentures supported by ITI implants: A 6.5-Year evaluation of patient satisfaction and prosthetic aftercare. *Int J Oral Maxillofac Implants.* 1995; 10:744-749.

12. Raghoobar G, Meijer H, Stegenga B, et al. Effectiveness of three treatment modalities for the edentulous mandible. *Clin Oral Impl Res.* 2000; 11:195-201.

13. Bakke M, Holm B, and Gotfredsen K. Masticatory function and patient satisfaction with implant-supported mandibular overdentures: A prospective 5-Year study. *Int J Prosthodont.* 2002; 15:575-581.

14. Sadowsky, SJ. Mandibular implant-retained overdentures: A literature review. *J Prosthet Dent.* 2001; 86:468-473.

15. Batenburg R, Meijer H, Raghoobar G, et al. Treatment concept for mandibular overdentures supported by endosseous implants: A literature review. *Int J Oral Maxillofac Implants.* 1998;13:539-545.

16. Sadowsky SJ. The implant-supported prosthesis for the edentulous arch: design considerations. *J Prosthet Dent.* 1997;78(1):28-33.

17. DeBoer J. Edentulous implants:Overdenture Versus fixed. *J Prosthet Dent* 1993;69:386-390.

18. Wismeijer D, Van Waas MA, Kalk W. Factors to consider in selecting an occlusal concept for patients in the edentulous mandible. *J Prosthet Dent* 1951; 74:380-384.

19. Sillard R. Fixed removable dental implant system. United State patent No. 4,931,016,1990.

20. Lefkove MD, Beals R. Spark erosion fixed detachable prosthesis for completely edentulous maxilla. *J Oral Implantol* 1992; 18:386-393.

21. Davodi A, Nishimura R, Beumer J 3rd. An implant-supported fixed-removable prosthesis with a milled tissue bar and Hader clip retention as a restorative option for the edentulous maxilla. *J Prosthodont.* 1997; 78:212-217.

22. Ercoli C, Graser GN, Tallents RH, Hagan ME. Alternative procedure for making a metal suprastructure in a milled bar implant-supported overdenture. *J Prosthet Dent.* 1998; 80:253-258.

23. Brudvik JS, Chigurupati K. The milled implant bar: an alternative to spark erosion. *J Can Dent Assoc.* 2002 Sep;68(8):485-488.

24. Galindo DF. The implant-supported milled-bar mandibular overdenture. *J Prosthodont.* 2001; 10:46-51.

25. Hebel KS, Galindo D, Gajjar RC. Implant position record and implant position cast: minimizing errors, procedures and patient visits in the fabrication of the milled-bar prosthesis. *J Prosthet Dent.* 2000; 83:107-116.

26. Trakas T, Michalakis K, Kang K, Hirayama H. Attachment systems for implant retained overdentures: a literature review. *Implant Dent.* 2006;15:24-34.

27. Chung KH, Chung CY, Cagna DR, Cronin RJ Jr. Retention characteristics of attachment systems for implant overdentures. *J Prosthodont* 2004;13:221-6.

28. Schneider AI, Kurtzman GM. Bar overdentures utilizing the locator attachment. *Gen Dent.* 2001; 49:210-214.

29. Al-Harbi SA, Verrett RG. Fabrication of a stable surgical template using staged tooth extraction for immediate implant placement. *J Prosthet Dent* 2005;94:394-397.

30. Assif D, Fenton A, Zarb G, et al. Comparative accuracy of implant impression procedures. *Int J Periodontics Restorative Dent.* 1992;12:112-121.

31. Assif D, Marshak B, Schmidt A. Accuracy of implant impression techniques. *Int J Oral Maxillofac Implants.* 1996;11:216-22.

32. Jemt T. Failure and complications in 391 consecutively inserted fixed prostheses supported by Brånemark implant in edentulous jaw: a study of treatment from the time of prostheses placement to the first annual checkup. *Int J Oral Maxillofac Implants* 1991;6:270-276.