

Silver diamine fluoride: a practical guide

Louis Mackenzie¹

The COVID-19 pandemic and subsequent limitations on the use of aerosol generating procedures has renewed interest in the use of silver diamine fluoride (SDF) as a simple, minimally invasive method for stabilising and arresting carious lesions.^{1,2,3}

Silver diamine fluoride (SDF)

SDF is a colourless alkaline (pH 9-10) solution containing silver (~25%) and fluoride (~5%) stabilised in ammonia. It has been used internationally for caries management for decades but is currently only licenced as a desensitising agent in the UK, with one CE marked product: RIVA STAR (SDI, Australia) – Figure 1.

Silver has been used as an antimicrobial agent worldwide for over a century, as it has been demonstrated to be capable of destroying bacterial cell walls, inhibiting bacterial metabolism and enzyme activity and reducing biofilm formation. In SDF, this combines with the remineralising properties of fluoride to offer a range of clinical indications and reported advantages, listed in Table 1.^{1,2,3}

The principal disadvantage of SDF is a potential for black/brown discolouration of carious dentine, caused by precipitation of metallic silver and silver oxide, which limits its acceptance aesthetically. Staining may be reduced with the use of potassium iodide solution.

Contraindications for SDF are listed in Table 2 and other cautions include the following:

- Unaesthetic staining of restorative margins
- Staining, irritation or burns of mucosa and skin
- Damage to worktops and clothing
- Slight metallic taste/ammonia odour (but generally well tolerated)
- May reduce bond strengths of glass ionomer and resin composite materials (but may stabilise hybrid layers)

¹ Louis Mackenzie, BDS
Clinical Lecturer, School of Dentistry,
University of Birmingham, UK
Private Practice, Birmingham UK
Head Dental Officer, Denplan

Clinical procedure for SDF caries treatment

Silver diamine fluoride is available in a range of concentrations eg 12-40%, with 38% considered to be the most effective.

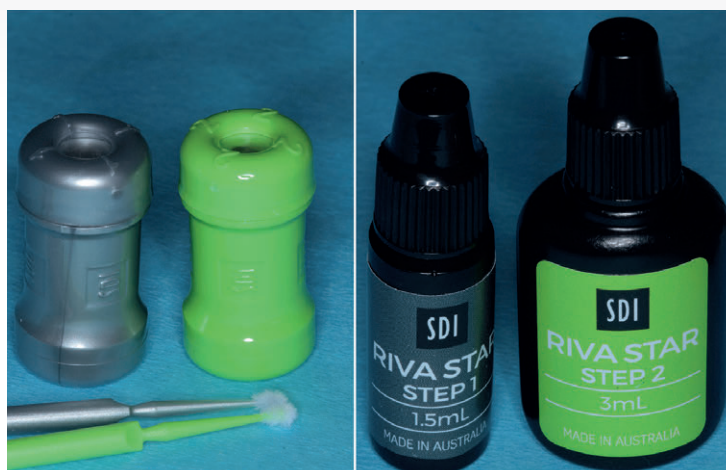

Figure 1. RIVA STAR (SDF) delivery systems.

The following step-by-step stages have been recommended for treatment of carious lesions^{1,2,3} and key clinical stages are simulated on an extracted tooth (Figure 2A)

- Cover worktops and protect the patient's clothing with a plastic bib
- Apply a suitable barrier material (eg petroleum jelly) to protect the patient's lips
- Remove visible plaque
- Excavate soft, necrotic, infected dentine eg using a hand instrument (Figures 2B,C)
- Isolate the treatment area eg rubber dam, liquid dam (provided in kit) or cotton wool rolls

Table 1: Clinical indications and advantages of SDF

Immediate relief of dentine hypersensitivity (Silver iodide blocks dentine tubules and has low solubility) eg cervical abrasion cavities
Relief of symptoms from carious cavities (especially occlusal lesions)
Promotes minimally invasive cavity preparation (eliminating the need for extensive caries excavation)
Minimises the need for aerosol generating procedures
Inexpensive and obviates the need for local anaesthesia
Quick and easy application makes it useful for patients who are: vulnerable, uncooperative, have behavioural problems and those with limited access to conventional dental treatment
Stabilisation/arrest of caries into dentine in deciduous teeth eg may avoid the need for hospital admission (GA/Sedation)
Stabilisation of deciduous teeth soon to be exfoliated
Stabilisation/arrest of caries in elderly patients eg root caries
Acclimatisation to dental treatment and stabilisation of multiple lesions
Remineralisation of incipient carious lesions (2-3 times more fluoride concentration than sodium fluoride varnish)
Endodontic irrigation and inter-appointment medicament

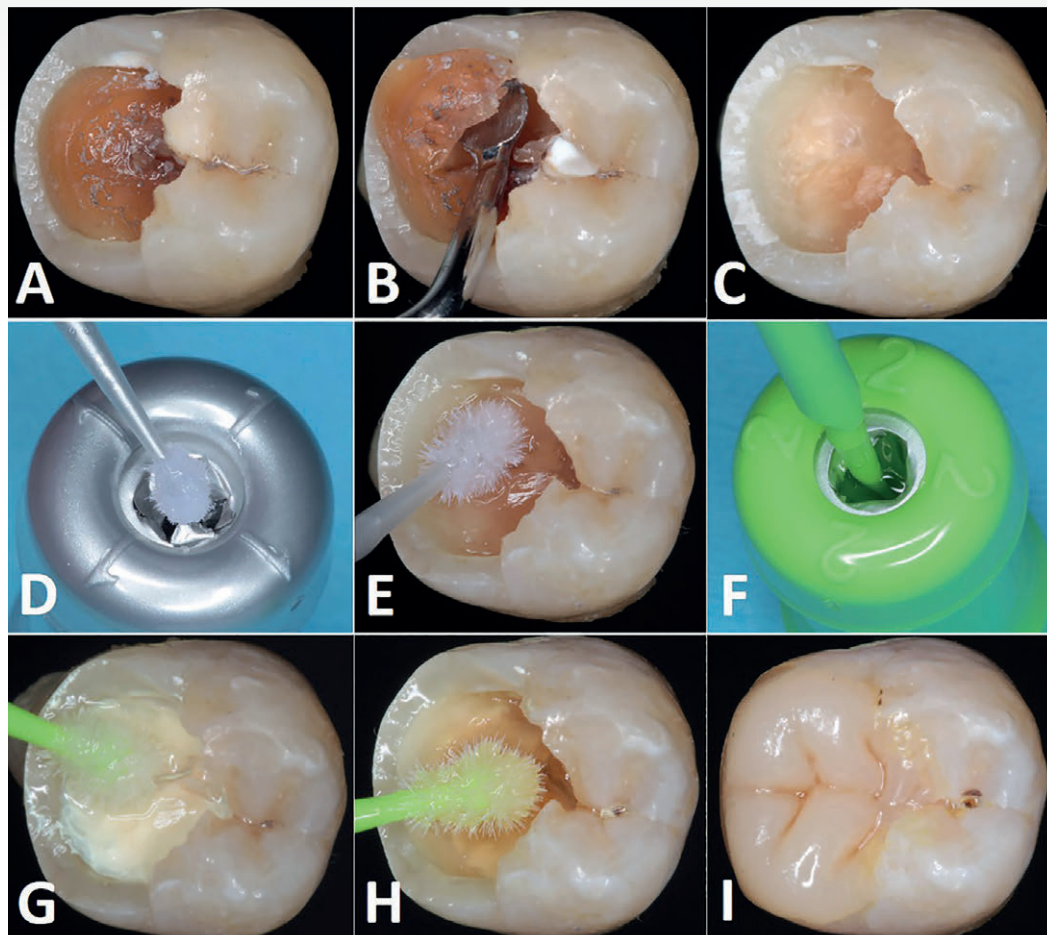


Figure 2. Practising the use of silver diamine fluoride (RIVA STAR, SDI) for caries management on an extracted natural mandibular molar.

- Pierce the SDF capsule (silver) with a microbrush and thoroughly wet the tip (no mixing is required) – Figure 2D
- A glass Dappens dish may also be used as a dispenser (the SDF capsule contains sufficient material to treat approximately five carious lesions)
- Apply to SDF to dentine caries (with care to avoid soft tissue contact) as in Figure 2E
- Blot excess with cotton wool or gauze
- Working time is approximately five minutes and once placed leave for 1-3 minutes
- Pierce the Potassium Iodide (KI) capsule (green) with a new (colour coded) microbrush (Figure 2F)
- Continuously apply KI to the SDF until the creamy white precipitate (Figure 2G) turns clear (Figure 2H)
- Repeat blotting of excess material
- Leave to dry completely
- Restore tooth as required eg resin composite or glass ionomer. It is recommended to rinse enamel with water first (Figure 2I)
- Remove isolating materials
- Safely dispose of single-use capsules and used microbrushes
- Review patient for signs of arrest in around 2-4 weeks

Table 2: Contraindications for SDF.¹

Silver/heavy metal allergy
Pregnancy and breastfeeding (risk of overloading developing thyroid with iodide)
Lesions close to the pulp/possible pulpal involvement (avoids silver ions in pulp chamber)
Signs and symptoms of periapical pathology (clinical and/or radiographic)
Ulceration, mucositis or stomatitis
Restoration of permanent anterior teeth

(large cavities may need a second SDF application)

- Six monthly re-application is recommended for SDF treated lesions that are not definitively restored
- Successful use of SDF will be significantly enhanced as part of a comprehensive prevention/caries management programme

Prescribing SDF

SDF is licenced for use in the UK as a desensitising agent (and cavity cleanser). Its use beyond the approved indications is considered to be off-licence prescribing. If used for caries management, the Medicines and Healthcare Regulatory Agency (MHRA) guidelines must be followed regarding prescribing in the patient's best interest, based on

the best available evidence and when there is no suitable alternative treatment.³

References

1. Greenwall-Cohen J, Greenwall L, Barry S. Silver diamine fluoride – an overview of the literature and current clinical techniques. *BDJ*. June 2020; Vol 228, No11: 831-838.
2. Crystal YO. Silver diamine fluoride (SDF): its role in caries management. *Dental Update*. Dec 2019; 46: 1016-1022.
3. Timms L, Deery C, Stevens S, Rodd H. COVID-19. Time to use silver diamine fluoride for caries arrest in general dental practice. *Dental Update*. Sept 2020; 47: 548-558.