

# Guided full arch implant surgery - a novel approach using a chrome cobalt bone reduction guide: A case report

Gert Sauer<sup>1</sup>, Riyaz Rahbeeni<sup>2</sup>, Mogammad Thabit Peck<sup>3</sup>, Johan Blaauw<sup>4</sup>, Benjamin Calitz<sup>5</sup>

<sup>1</sup> Dr Gert Sauer  
BChD (UWC) Post Grad Course in Implantology (Pret)  
Private Practice Pretoria Gauteng  
1201 Justice Mahomed Street  
Brooklyn Pretoria  
(+27) 12 346 7521  
gsauer@telkomsa.net

<sup>2</sup> Dr Riyaz Rahbeeni  
BChD, MChD Prosthodontics  
Private Practice Durbanville, Cape Town  
and part time Clinical Consultant in Prosthodontics at the University of the Western Cape, Cape Town, South Africa  
(+27) 21 9765552  
rahbeeni@iafrica.com

<sup>3</sup> Dr Mogammad Thabit Peck  
BChD, MSc, MChD, MRD, FDS RCSEd, MTD FRCSEd, MBA, PGDip MedEd, PhD  
Private Practice Periodontist, Cape Town,  
ORCID Number: 0000-0002-4755-0574

<sup>4</sup> Dr Johan A D Blaauw  
BChD (Pret) Post Grad Course in Implantology (Pret)  
Private Practice Lichtenburg, North West province  
(+27) 18 6323677  
jblaauw@worldonline.co.za

<sup>5</sup> Benjamin Fredeman Calitz  
Btech Dental Technology (Tshwane University of Technology)  
Oracav Dental Laboratory  
56 15th Street, Menlo Park, Pretoria 0081  
(+27) 82 695 7756  
callie@oracav.co.za

## Corresponding author

Gert Sauer  
Tel: +27(12) 346 7521 / Fax: 086 687 3685 / Address: 1201 Justice Mahomed Street Brooklyn Pretoria 0181 / Email: gsauer@telkomsa.net

## Abstract

**Introduction.** Many patients require solutions to shift from a failing dentition to a full arch rehabilitation using dental implants. Placement of four implants through guided surgery combined with an interim, immediately loaded prosthesis constitutes a predictable treatment for full arch rehabilitation. The aim of this report was to present the digital workflow and clinical use of a chrome cobalt bone reduction guide, which can simplify implant rehabilitation in terminal dentitions and increase precision and predictability of treatment outcome.

**Material and Methods.** The patient was treated with a full arch implant-based fixed maxillary prosthesis with immediate function. A virtual patient was created and implant planning software was used to create three guides: a tooth-supported guide, stabilized by three stabilizing pins, a bone reduction guide fabricated from chrome-cobalt, and an implant guide that fit onto the bone reduction guide.

**Results and discussion.** In this case of full-arch prosthetic implant-based rehabilitation in the maxilla, the use of a chrome cobalt bone reduction guide was successful in increasing stability, resistance to fracture and predictability of the alveoloplasty procedure.

**Conclusions.** This novel approach using a chrome cobalt bone reduction guide can be particularly useful when working in areas with reduced bone density.

**Key-words:** Guided implant Surgery, Full Arch Implant Rehabilitation, Digital implant Workflow, surgical Guide, implant planning software

**Short title:** Chrome Cobalt Bone Reduction Guide for Implant Rehabilitation

## Introduction

In clinical practice, many patients require solutions to shift from a failing dentition to a full arch rehabilitation using dental implants. These cases often present with a high level of complexity. Placement of four or six implants through guided surgery and installation of an interim, immediately loaded and functional prosthesis constitutes a predictable restorative treatment for full arch rehabilitation, with high medium to long-term implant survival rates.<sup>1</sup> This approach is beneficial for the patient, as it contributes to maintenance of the vertical dimension of occlusion (VDO) and the lower facial



Figure 1. Extraoral digital photograph with patient displaying an exaggerated smile.

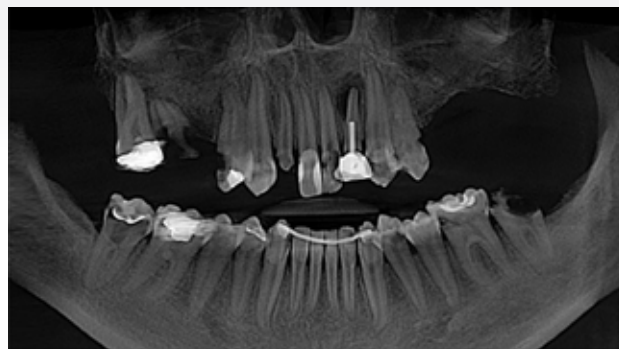

Figure 2. Panoramic image of patient displaying failing dentition with several pathological conditions, further restricting the available bone for implant placement.

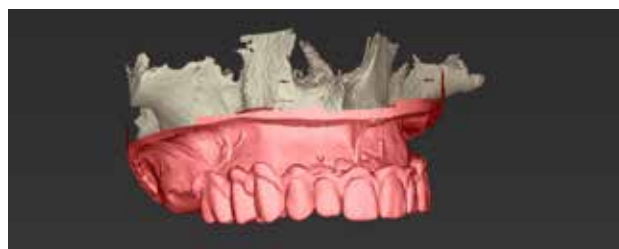

Figure 3. Digital design of immediate interim prosthesis to aid in virtual implant planning.

height, while providing protection to the extractions sockets. Immediate complete dentures have high patient acceptance as it can restore the patient's appearance and self-esteem, reducing the psychosocial effects of edentulism.<sup>2</sup>

In general, precision and predictability of dental implant treatment have improved due to digital technologies and 3D implant software. A virtual patient can be created to assist with the planning of prosthetically driven implant placement through the integration of CBCT Digital Imaging and Communication in Medicine (DICOM) files, digital scanning Standard Tessellation Language (.STL) files, and JPEG files from digital photographs, which enables accurate planning of the oral rehabilitation procedures from a craniofacial virtual perspective.<sup>3,4</sup>

The success of full arch rehabilitations with dental implants using digital technologies greatly relies on surgical guides fabricated through computer aided design/computer aided manufacturing (CAD/CAM) technology.<sup>5</sup> Guided implant surgery present several advantages, including lower risk of damage to anatomic structures, limited risk for complications, such as bone dehiscence and fenestration, use of restorative-based surgical plans and higher predictability. However,

when surgical guides are used, the resulting increase in surgical steps requires the surgeon to become familiar with the guided workflow in order to avoid inaccuracies.<sup>6</sup>

In terms of type of support, there are three different types of implant surgical guides: bone-supported, mucosa-supported and tooth-supported guides. Mucosa and bone supported guides are frequently used in the rehabilitation of patients who present a terminal dentition and those who are fully edentulous.<sup>7</sup> Stabilizing pins are used in order to improve the stability of mucosa and bone supported guides, limiting movement of the guide during surgery. In spite of the use of stabilizing pins, bone and mucosa supported guides have been reported to present lower stability when compared to tooth supported guides.<sup>8</sup>

The sequential use of multiple surgical guides has been previously described in the literature in the rehabilitation of patients with a failing dentition.<sup>4</sup> The "three guide technique" uses three reference osteotomies for three stabilizing pins. The same osteotomies are repeatedly used to fixate the first guide (a tooth supported reference guide), the second guide (used for bone reduction), and the third guide, which is used for surgical implant placement. The accurate fit of

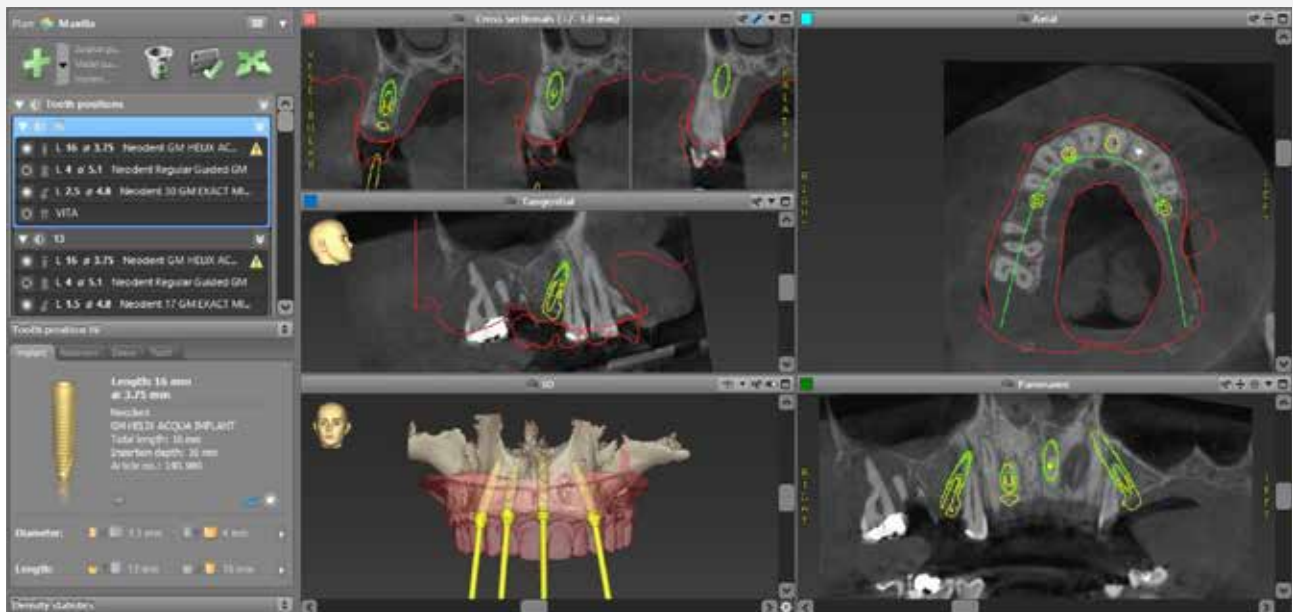


Figure 4. 3D surgical plan for computer-guided implant surgery.

each guide is essential, since it will reflect the precision of the planning and affect final implant positions.<sup>9</sup>

In many cases, terminal dentitions are associated with poor alveolar bone quality, often presenting associated pathologies. Because bone density cannot accurately be measured through cone beam computed tomography (CBCT), frequently bone type can only be confirmed after teeth extraction.<sup>10</sup> In type III and IV bone, use of the same reference osteotomies for three different guides can lead to wear of the osteotomies due to the repetitive insertion and removal of stabilizing pins. This reaming can decrease accuracy of fit, potentially affecting final implant position and treatment outcomes. Hence, reinsertion of reference pins for multiple guides can be challenging in poor quality bone.

In patients with a failing dentition, bone reduction (alveoloplasty) is often part of the surgical treatment plan, with the aim of optimizing the shape of the alveolar ridges, creating adequate inter-arch space or hiding the transition zone between the superior border of the denture and the mucosa in the maxilla in order to improve aesthetics in patients with high smile lines.<sup>4</sup> When using traditional reduction guides made from resin, there is a risk of breakage while securing it in place prior to alveoloplasty.<sup>11</sup>

In order to overcome this limitation, we created a rigid bone reduction guide made from chrome cobalt, which includes the final implant placement guide through the

addition of five extra stabilizing pins. The chrome cobalt bone reduction guide adapts to the labial and buccal surface of the maxilla and, after alveoloplasty, the implant placement guide is anchored to the reduction guide through five pins, with a palatal stop used as the sixth reference point. To our knowledge, no previous studies have reported the use of chrome cobalt bone reduction guides that connects to the implant placement guide. The aim of this technique report is to present the digital workflow and clinical use of a chrome cobalt bone reduction guide, which can simplify implant rehabilitation in terminal dentitions and increase precision and predictability of treatment outcome.

### Case Report

A 27-year-old female in good general health with several missing and compromised teeth in the maxilla presented for treatment (Figure 1). Upon clinical examination, it was concluded that the remaining maxillary dentition was severely compromised due to caries and dental fractures. Those findings were confirmed by a panoramic x-ray, which also revealed severe periapical pathology on tooth 22 (Figure 2). There were no noises or deviations in the temporomandibular joint and the patient did not present limitation when opening her mouth. Upon palpation, there was no tenderness in the masticatory muscles.

Extra oral and intraoral digital photographs were taken

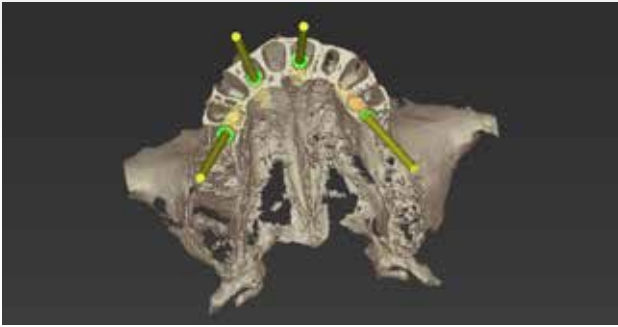


Figure 5. The desired bone reduction was virtually performed on the CBCT DICOM images using the virtual implant planning software.

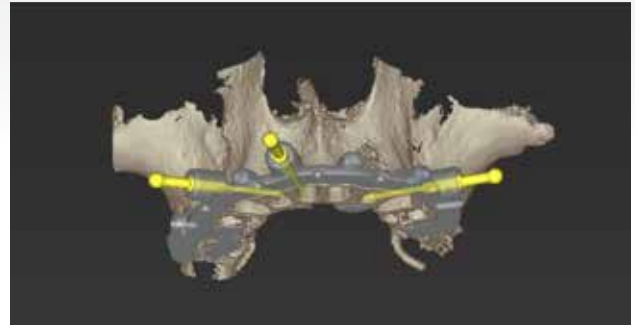


Figure 6. Bone reduction guide with 3 reference guide pins.

and exported as Joint Photographic Experts Group (JPEG) files. Through full face extra oral photographs, maxillary lip position and gingival display were recorded.

After the initial clinical and radiographic evaluations, the patient was diagnosed with a terminal maxillary dentition and presented with different treatment options. The most predictable option to meet the patient's expectations in terms of rehabilitation treatment was a full arch implant-based fixed maxillary prosthesis with immediate function and the possibility of salvaging and restoring the lower dentition.

### Treatment planning

The patient was subjected to a pre-operative cone beam computer tomography (CBCT) (Orthophos, Dentsply Sirona) scan for analysis of the alveolar ridge anatomy pertinent to implant placement. An intraoral scan (Omnicam, Dentsply Sirona) was performed and the resulting standard tessellation language (.STL) data files provided information on dental hard and soft tissues.

All files containing diagnostic information, i.e. intraoral scanning .STL files, CBCT DICOM files, extra and intraoral

photographs were exported to a specialized dental laboratory (Oracav Dental Laboratory, Pretoria, South Africa). Using DICOM files as the foundation, 3D volumetric data of the craniofacial hard tissues and remaining dentition were segmented and inserted into a virtual implant planning software (coDiagnostiX, Dental Wings, Montreal, Canada). The STL data of hard and soft tissues were included into the virtual implant planning software and combined with the DICOM data.

A digital denture was designed using Cares Visual, Dental Wings CAD/CAM software by selecting and importing maxillary teeth from an online library, which were edited in terms of shape and position to match the patients' smile and occlusion (Figure 3).<sup>12</sup> The final digital denture was imported into the implant planning software and a prosthetically driven surgical plan for computer-guided implant surgery was generated in the implant planning software (Figure 4,5,6).

The location of three stabilizing pins was defined after the virtual creation of the tooth-supported guide. This reference guide is highly accurate in replicating the position of the

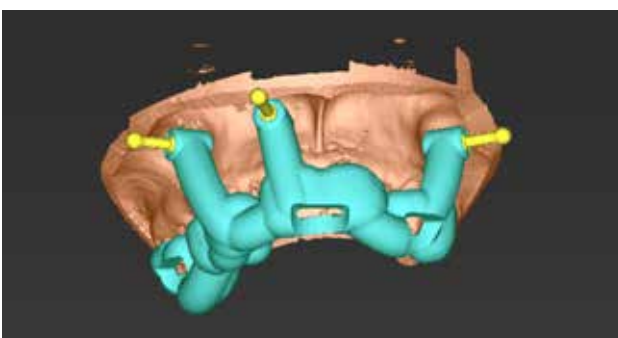


Figure 7. Tooth supported guide to accurately transfer positions of osteotomies for stabilization pin placement.

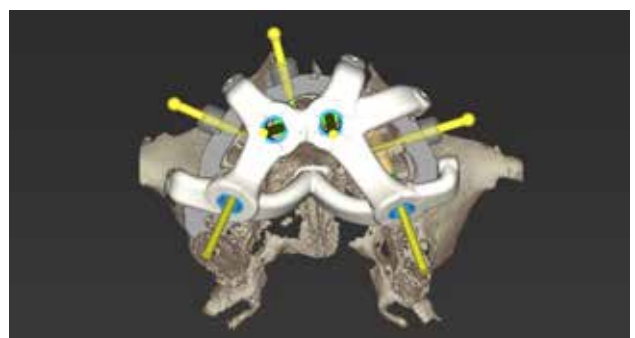


Figure 8. Implant placement guide fixates on bone reduction guide and additional positive palatal stop as reference.



Figure 9. A) Tooth supported reference guide fitted onto a 3D printed model of the maxilla with the 3 anchor pins fitting the guide to the bone.

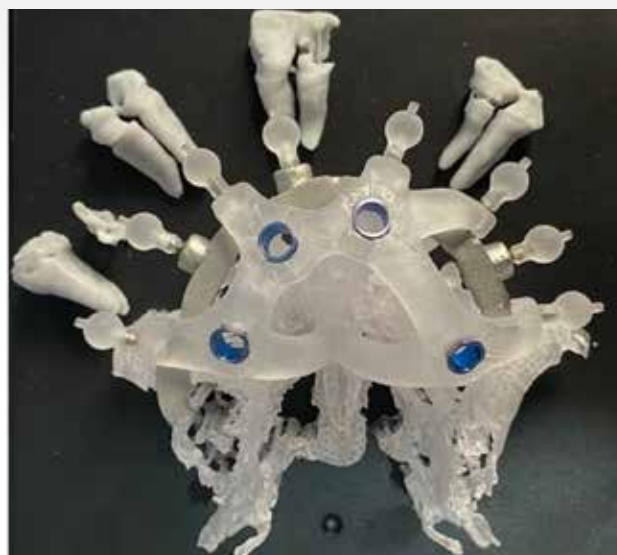


Figure 9. B) Chrome cobalt bone reduction guide with the implant placement guide fitted onto the 3D printed maxilla with planned bone reduction.

stabilizing pins for the subsequent guides, being supported by the residual dentition (Figure 7).

Next, the bone reduction guide was created keeping the exact same location of the stabilizing pins used for the first surgical guide. Five additional stabilizing pin slots were created by the dental technician to allow anchorage of the implant placement guide onto the bone reduction guide. Lastly, the implant placement guide was designed with a positive palatal stop, used as an additional reference point (Figure 8).

All three surgical guides, i.e. the reference guide, bone reduction guide and implant placement guide, were exported as STL files for 3D printing (Straumann Rapid Shape, Heimshein, Germany).

The dental technician transformed the bone reduction guide into a chrome cobalt guide, which adapts to the labial and the buccal surfaces of the maxilla. All three guides were carefully examined for fit prior to surgery on 3D printed models (Figure 9). An immediate denture was manufactured for immediate loading.

### Surgical procedure

The surgery was performed in a hospital setting under general anaesthesia. After precise fitting of the reference tooth supported guide, three 1.4 mm osteotomies were created by perforation of soft tissues and penetration of the alveolar bone with surgical drills, followed by the insertion of three stabilizing pins (Figure 10).

The tooth supported guide was removed and all residual maxillary teeth were extracted as atraumatically as possible. The chrome cobalt bone reduction guide was secured and

stabilized through stabilizing pins, which were located at the exact same positions as the initial tooth-supported guide (Figure 11).

Bone reduction was performed through piezo surgery to the desired bone level as planned, with the reduction guide in place (Figure 12).

After completion of bone reduction, the implant placement guide was fitted through five additional pre-planned stabilizing pins in the bone reduction guide (Figure 13). Shortened stabilizing pins were used to secure the implant guide in place. The final reference point was confirmed through a positive stop in the palate.

A guided implant kit was used for implant placement with the guide in place after confirmation of all reference points, according to the manufacturer's instructions (Neodent Grand Morse Guided implant kit). Following the drilling protocol recommended by the manufacturer, four Neodent implants (Grand Morse Helix Acqua) were placed with a fully guided protocol. Final insertion torque ranged from 45 to 60 Ncm per implant. The cumulative or composite torque across the four implants was 220Ncm. This torque value was deemed high enough for immediate loading. For a four-implant approach with minimal bone-to-implant contact for all implants, a composite insertion torque has been suggested by Jensen & Adams (2012) in order to help the clinician establish a quantitative threshold to allow for immediate function.<sup>13</sup> This threshold has been clinically established to be 120 Ncm, with minimum of 30 Ncm per

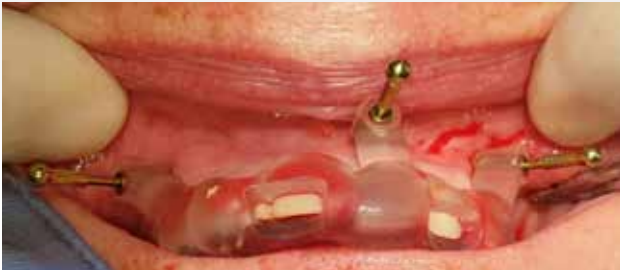

Figure 10. Accurate fitting of tooth supporting reference guide stabilized by three anchor pins.

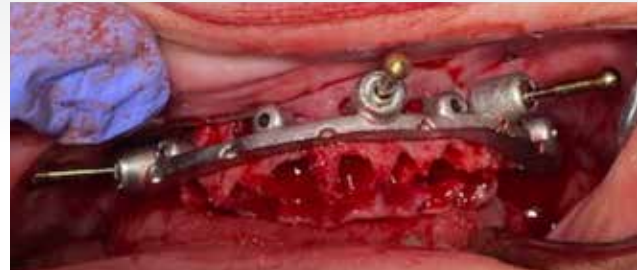

Figure 11. Chrome cobalt bone reduction guide fitted with three anchor pins inserted into the three initial osteotomies used for the tooth supported guide.

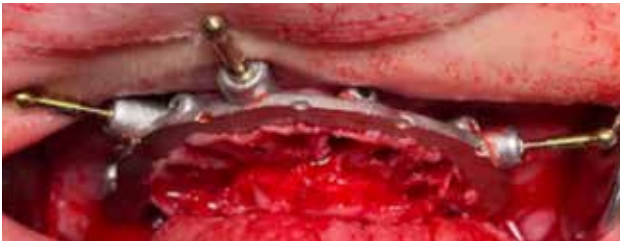

Figure 12. Completion of bone reduction, using the reduction guide as reference.

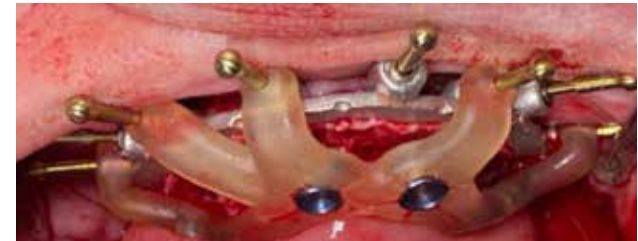

Figure 13. Implant placement guide slotted into the bone reduction guide through five additional slots.

implant.<sup>14</sup> After primary stability was confirmed, multi-unit abutments 17 or 30 degrees were connected to the tilted implants for adequate orientation of screw access holes.

The following is a description of the four implant locations with the mini conical abutment connected to each implant to facilitate ideal screw access location.

15: 30° 2.5 4.8 Neodent GM Exact Mini Conical Abutment

11: 17° 2.5 4.8 Neodent GM Exact Mini Conical Abutment

22: straight 2.5 4.8 Neodent GM Straight Mini Conical Abutment

25: 30° 2.5 4.8 Neodent GM Exact Mini Conical

### Abutment

Straight and angled multi-unit abutments were used for the anterior implants. Temporary titanium cylinders were secured to the abutments and a pre-fabricated denture was retrofitted to function as a fixed provisional prosthesis. The provisional prosthesis was fitted 12 hours after implant surgery. All implants were splinted with a metal bar incorporated in the temporary prosthesis (Figure 15). A postoperative

panoramic radiograph was taken, as well as final intra and extra-oral photographs (Figures 14, 15 and 16).

### Discussion

In this article, the successful use of a novel chrome-cobalt bone reduction guide as part of a guided full-arch implant-supported rehabilitation of a patient who has a terminal dentition is presented. To the best of our knowledge, no studies in the literature have previously reported the use of a computer-generated bone reduction guide made from chrome-cobalt.

With regard to dental implant planning, patients with a terminal dentition greatly differ from edentulous patients, who often present some degree of alveolar bone resorption. A terminal dentition typically needs reduction of the alveolar bone after teeth extraction, particularly in the maxilla.<sup>4</sup> The alveoloplasty procedure optimizes the anatomy of the alveolar ridge in order to facilitate implant placement and installation of the prosthesis.<sup>15</sup> Precision is key when performing this surgical procedure, as incomplete, uneven or exaggerated reduction can result in less than ideal implant location, which can in turn compromise the restorative stage. The efficacy of guided dental implant protocols relies on

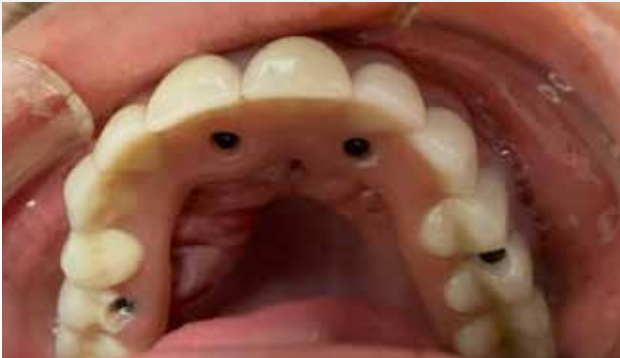

Figure 14. Prefabricated denture fitted to temporary titanium cylinders and secured to multi-unit abutments

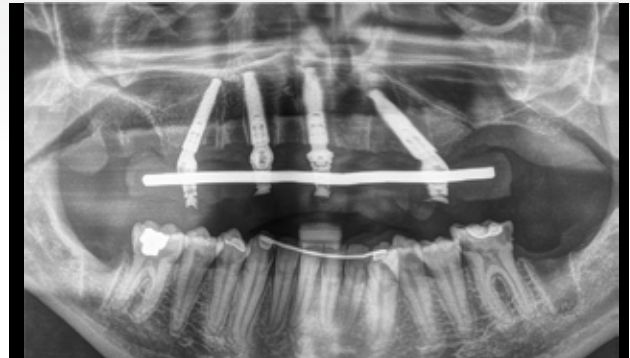


Figure 15. Postoperative panoramic image displaying completed treatment.



Figure 16. Postoperative clinical photo 12 hours after surgery.

the precision of the transfer of information from the virtual to the oral environment through surgical guides. Computer-generated guides are an integral part of the digital workflow in implant rehabilitation, and the transfer of information depends on the fit of the guide, its accuracy and stability during surgery.<sup>16-18</sup>

In our clinical experience, due to the highly invasive nature of the bone reduction that is often required in terminal dentitions, the stability of the surgical guide is usually put to the test during surgery, particularly when dealing with poor density alveolar bone. Computer-generated stereolithographic guides are typically made of dental resin.<sup>19</sup> We have observed that during extensive alveoloplasty, particularly in poor density alveolar bone (types III and IV), there is always

a risk for breakage or dislodgement of the resin guide due to wear of the osteotomies after repeated inserted stabilizing pins. Lack of stability can ultimately affect alveolar bone reduction and implant positioning.<sup>20</sup> In case of movement or collapse of the guide during surgery, the procedure is likely to become compromised, potentially leading to detrimental changes to workflow and unpredictable treatment outcomes.<sup>21</sup>

This report describes the clinical application of a chrome cobalt bone reduction guide, which presented a few advantages in relation to resin surgical guides. Firstly, the metallic nature of the guide significantly increased resistance to fracture during surgery. Secondly, the creation of five additional stabilizing pins in the implant placement guide improved its stability. Guide stability is essential, as it determines the accuracy of the surgical outcome in relation to the planned treatment<sup>20</sup>, reason why this novel approach seems promising.

When compared to conventional procedures, digital technologies present several advantages for dental implant treatment, such as the possibility of digitally creating the desired shape of the alveolar ridge (Fig 6+7), ideal implant positioning and occlusion of the prosthesis before going into the oral environment.<sup>7</sup> The use of advanced virtual implant planning software and the creation of a virtual version of the patient have made it easier to simulate and plan implant positioning based on functional, aesthetic, prosthetic and anatomical factors.<sup>22</sup>

The use of digital technologies greatly diminishes the risk for unexpected intra-operative situations, providing a realistic view of relevant anatomic landmarks. For the dental surgeon, this can result in increased treatment predictability

and decreased stress during surgery, while for the patient, it leads to a better overall experience and improved aesthetic outcomes.<sup>23,24</sup>

As a technique report, this study has limitations, mainly due to the lack of comparison between chrome-cobalt and resin guides in terms of precision, accuracy and treatment results. This should be evaluated in future studies with adequate sample size. Another potential limitation of the technique described is the higher cost of chrome-cobalt guides, as compared to resin guides

## Conclusions

In a case of full-arch prosthetic implant-based rehabilitation in the maxilla, the use of a chrome cobalt bone reduction guide was successful in increasing stability, resistance to fracture and predictability of the alveoloplasty procedure. This has led to the successful oral rehabilitation of our patient in this case report. This novel approach can be particularly useful when working in areas with reduced bone density.

## References

1. Tallarico M, Meloni SM, Canullo L, Caneva M, Polizzi G. Five-year results of a randomized controlled trial comparing patients rehabilitated with immediately loaded maxillary cross-arch fixed dental prosthesis supported by four or six implants placed using guided surgery. *Clin Implant Dent Relat Res* 2016;18 (5):965-72.
2. Hassan B, Greven M, Wismeijer D. Integrating 3D facial scanning in a digital workflow to CAD/CAM design and fabricate complete dentures for immediate total mouth rehabilitation. *J Adv Prosthodont* 2017;9 (5):381-86.
3. Joda T, Gallucci GO. Short Communication The virtual patient in dental medicine. *Clin Oral Implant Res* 2015;26 (6):725-26.
4. Alzoubi F, Massoomi N, Nattestad A. Bone reduction to facilitate immediate implant placement and loading using cad/cam surgical guides for patients with terminal dentition. *Journal Oral Implantol* 2016;42(5):406-10.
5. Bidra AS, Taylor TD, Agar JR. Computer-aided technology for fabricating complete dentures: Systematic review of historical background, current status, and future perspectives. *J Prosthet Dent* 2013;109 (6):361-66.
6. Trobough KP, Garrett PW. Surgical guide techniques for dental implant placement. *Decisions in Dentistry* 2018;4 (8):11-13.
7. Scherer M. Simplifying Full-Arch Implantology With Digital Dentistry. *Dent Today* 2019;(2):76-79.
8. Geng W, Liu C, Su Y, Li J, Zhou Y. Accuracy of different types of computer-aided design/ computer-aided manufacturing surgical guides for dental implant placement. *Int J Clin Exp Med* 2015;8 (6):8442-49.
9. Sigcho López DA, García I, Da Silva Salomao G, Cruz Laganá D. Potential deviation factors affecting stereolithographic surgical guides: a systematic review. *Implant Dent* 2019;28 (1):68-73.
10. Bilhan H, Arat S, Geckili O. How precise is dental volumetric tomography in the prediction of bone density? *Int J Dent* 2012;(1):1-8.
11. Cascón WP, de Gopegui JR, Revilla-León M. Facially generated and additively manufactured baseplate and occlusion rim for treatment planning a complete-arch rehabilitation: A dental technique. *J Prosthet Dent* 2019;121 (5):741-45.
12. Coachman C, Calamita M, Sesma N. Dynamic Documentation of the Smile and the 2D/3D Digital Smile Design Process. *Int J Periodontics Restorative Dent* 2017;37 (2):183-93.
13. Jensen OT, Adams MW, Smith E. Paranasal bone: the prime factor affecting the decision to use transsinus vs zygomatic implants for biomechanical support for immediate function in maxillary dental implant reconstruction. *Int J Oral Maxillofac Implants* 2014;29 (1):e130-38.
14. Jensen OT, Cottam JR, Ringeman JL, Graves S, Beatty L, Adams MW. Angled dental implant placement into the vomer/nasal crest of atrophic maxillae for all-on-four immediate function: a 2-year clinical study of 100 consecutive patients. *Int J Oral Maxillofac Implants* 2014;29 (1):e30-35.
15. Beretta M, Poli PP, Tansella S, Maiorana C. Virtually guided alveolar ridge reduction combined with computer-aided implant placement for a bimaxillary implant-supported rehabilitation: A clinical report. *J Prosthet Dent* 2018;120 (2):168-72.
16. Farley NE, Kennedy K, McGlumphy EA, Clelland NL. Split-mouth comparison of the accuracy of computer-generated and conventional surgical guides. *Int J Oral Maxillofac Implants* 2013;28 (2):563-72.
17. D'Haese J, Van De Velde T, Elaut L, De Bruyn H. A prospective study on the accuracy of mucosally supported stereolithographic surgical guides in fully edentulous maxillae. *Clin Implant Dent Relat Res* 2012;14 (2):293-303.
18. Costa AJ de M, Teixeira Neto AD, Burgoa S, Gutierrez V, Cortes ARG. Fully digital workflow with magnetically connected guides for full-arch implant rehabilitation following guided alveolar ridge reduction. *J Prosthodont*



2020;29 (3):272-76.

19. Patel N, Fratianne S. Stereolithography: the future of dental fabrication. *Decisions in Dentistry* 2017;3(11):18-23.

20. Shen P, Zhao J, Fan L, Qiu H, Xu W, Wang Y, Zhang S, Kim YJ. Accuracy evaluation of computer-designed surgical guide template in oral implantology. *J Cranio-Maxillofacial Surg* 2015;43 (10):2189-94.

21. Moon S-Y, Lee K-R, Kim S-G, Son M-K. Clinical problems of computer-guided implant surgery. *Maxillofac Plast Reconstr Surg* 2016;38 (1).

22. Bover-Ramos F, Viña-Almunia J, Cervera-Ballester J, Peñarrocha-Diago M, García-Mira B. Accuracy of implant

placement with computer-guided surgery: a systematic review and meta-analysis comparing cadaver, clinical, and in vitro studies. *Int J Oral Maxillofac Implants* 2018;33 (1):101-15.

23. Jung RE, Schneider D, Ganeles J, Wismeijer D, Zwahlen M, Hämmerle CHF, Tahmaseb A. Computer technology applications in surgical implant dentistry: a systematic review. *Int J Oral Maxillofac Implants* 2009;24:92-109.

24. Vermeulen J. The accuracy of implant placement by experienced surgeons: guided vs freehand approach in a simulated plastic model. *Int J Oral Maxillofac Implants* 2017;32:617-24.