

RESTORATION OF A SINGLE CENTRAL INCISOR WITH AN ALL-CERAMIC CROWN: A CASE REPORT

BASIL MIZRAHI

Abstract

Optimum aesthetics can be obtained using an etchable, glass based ceramic crown (Empress, Ivoclar Vivadent, Liechtenstein) in combination with a resin cement. The specific stages in treatment are described, as are the stages for actual bonding of the crown. The importance of a good temporary crown is also emphasised and discussed.

The restoration of a single central incisor is a demanding procedure. The patient's aesthetic expectations are normally very high and the final result is heavily dependant on the dental technician. It is usually necessary for the technician to spend time with the patient at various stages while fabricating the crown and it is not uncommon for the crown to be remade if the aesthetic objectives are not achieved at first. These factors may increase the treatment time and patient needs to be made aware of this from the outset. The dentist needs to understand the technical difficulty and skill required to match a single crown to natural adjacent teeth and the high costs involved. Besides creating the optimal hard and soft tissue environment for the crown, the dentist needs to facilitate the opportunity for the technician to meet with the patient on one or more occasions if necessary. The initial meeting between the patient and dental technician should be at one of the patient's dental appointments. This allows for any meaningful discussion to take place between all three parties.

Another important factor for success in these cases is the temporary crown. A well made temporary crown will immediately satisfy the aesthetic, functional and biologic requirements of the patient and dentist. Once this has been accomplished, time becomes a friend rather than an enemy and can be utilised by both dentist and technician to ensure success in all aspects of the final restoration - good things take time.

In order to utilise the temporary crown to its full potential, the dentist needs to ensure that it is an improvement on the existing situation. Failure to do this will be detrimental to treatment and increase the patient's anxiety, reduce their confidence in the dentist and limit the time available for

treatment. The dentist therefore needs to be able to create a temporary crown with good form, function and colour and be skilled in the use of materials that allow for this.

Methylmethacrylate acrylic resin is the author's material of choice for the fabrication of all temporary restorations. The advantages of acrylic resin over the more popular bis-acryl automix products include (Mizrahi 2007):

- Increased versatility in modification of shape and colour. Acrylic resins consist of a powder and a liquid that can be combined in various different consistencies and applied in various ways.
- More amenable to remargination which allows for the creation of well fitting margins that in turn create healthy gingival tissue.
- Better polishability and resistance to longterm discolouration. Surface glazes should not be used as they create a rough surface and tend to stain after a short period of time.
- Because of their lower modulus of elasticity they can be easier removed from the underlying tooth without damage.

Early on in treatment, a decision needs to be made as to what type of crown to fabricate and the temporary crown will aid in this decision making process. Factors such as effect of the underlying tooth colour and the space available for restorative material can be assessed via the temporary crown. When attempting to match natural adjacent teeth, all ceramic crowns offer better potential for colour match than traditional porcelain fused to metal crowns (Douglas and Przybylska 1999). Much work has been carried out by Burke et al who have shown good long-term success with 'dentine bonded crowns' (Burke et al 1995, 1998, 2007, Burke and Qualtrough 2006, Burke 1999, 2000). There are two families of all-ceramic crowns to choose from:

- Low strength, etchable, glass based ceramics.

*Basil Mizrahi, BDS, MSc (Rand) MEd, Cert in Prosthodontics (USA)
Private Practice, London, UK*

- High strength, non-etchable alumina or zirconia based ceramics.

The following case outlines the technique involved in restoring a single central incisor with a resin bonded, etchable, glass based ceramic crown (Empress, Ivoclar Vivadent, Liechtenstein) in order to achieve a predictable aesthetic and functional result with a good long-term prognosis.

Case report

The patient was a 33 year-old female in good health. Her main complaint concerned tooth #21 (Figures 1 and 2). Fifteen years previously, the tooth received a traumatic blow and was root treated and restored with a composite restoration. Over the years, the composite restoration was replaced and the patient now requested a restoration with improved longevity and aesthetics.

On the study cast, the shape of the tooth was minimally modified with wax. A matrix was then made using silicone laboratory putty in an impression tray to be used for fabrication of the chair-side temporary crown (Figure 3). The existing composite restoration was removed and due to the favourable colour of the underlying tooth substrate and the possibility of keeping the margins equi-gingival in enamel, it was decided to utilise a resin bonded, etchable, glass based ceramic crown (Empress Emax).

Tooth preparation edges for all ceramic crowns should be rounded with no sharp angles to create internal stresses in the crown (Figure 4). In addition, margins should be extremely smooth and uniform to allow the technician to fabricate precise, well fitting and strong ceramic margins. Any unevenness on the ceramic margins will lead to increased fragility of the margin with and increased susceptibility to cracking.

After tooth preparation, especially when existing restorations are removed, the gingivae are often inflamed or traumatised and bleeding is usually present. As such making the impression should be delayed until a subsequent appointment (about two weeks later) once tissue health has been re-established in the presence of a temporary crown with precisely fitting and highly polished margins.

Following tooth preparation, a methylmethacrylate acrylic resin (Palavit 55VS, Heraeus Kulzer, GMBH), temporary crown was fabricated, utilising the silicone matrix formed on the modified study model (Figures 5-8). The temporary crown was cemented with a non-eugenol containing temporary resin cement (TempBond Clear, Kerr, Orange County, USA) and the

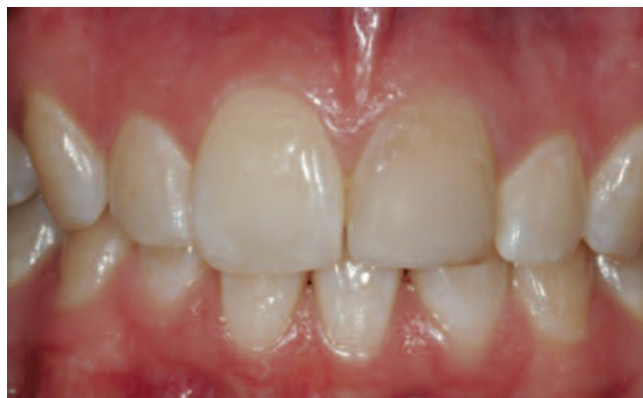

Figure 1: Pre-op view of discoloured composite restoration on tooth # 21

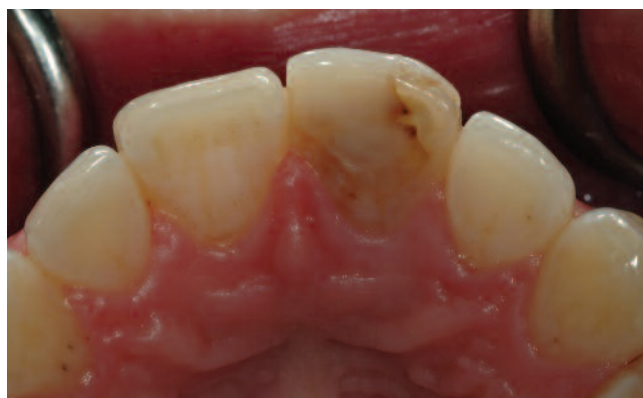

Figure 2: Palatal view of a large defective composite restoration in tooth # 21

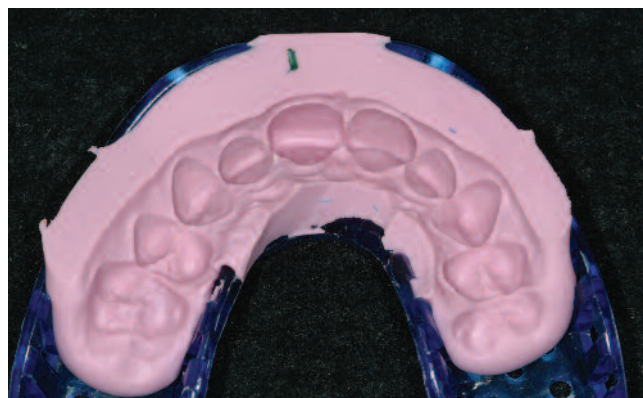


Figure 3: Silicone putty matrix formed on study model and used in intra-oral fabrication of the temporary crown

patient returned two weeks later for the definitive impression.

Shade selection should be done at the beginning of the impression appointment before the teeth have had time to dehydrate and change colour (become brighter). For single tooth colour matching, the dental technician should be present at the appointment to select the correct shades. Prior to making the impression, the level of the healthy gingival margin should be re-evaluated and if necessary, it should be re-

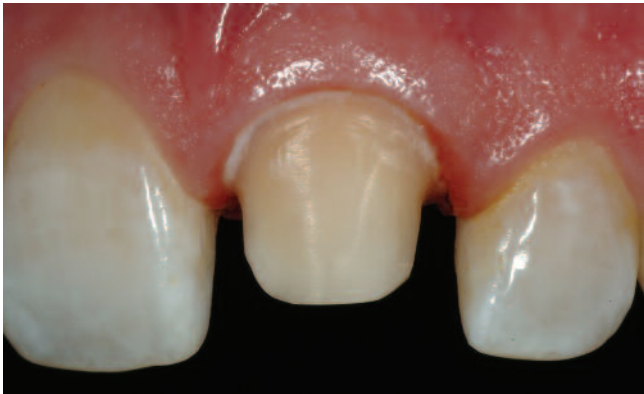

Figure 4: Tooth preparation with equi-gingival margins in enamel. Note smooth preparation with no sharp angles

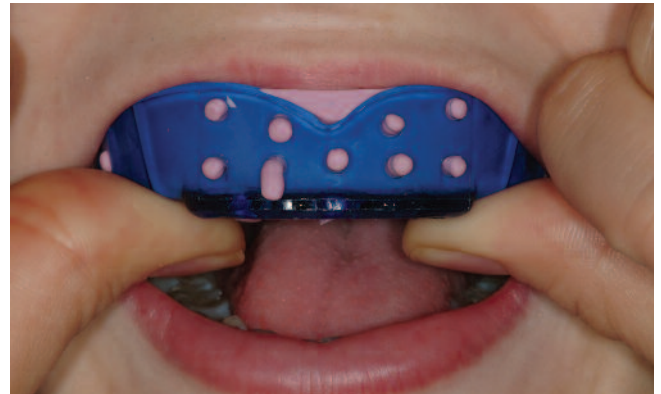


Figure 5: Silicone putty matrix with methylmethacrylate acrylic resin being applied over the tooth

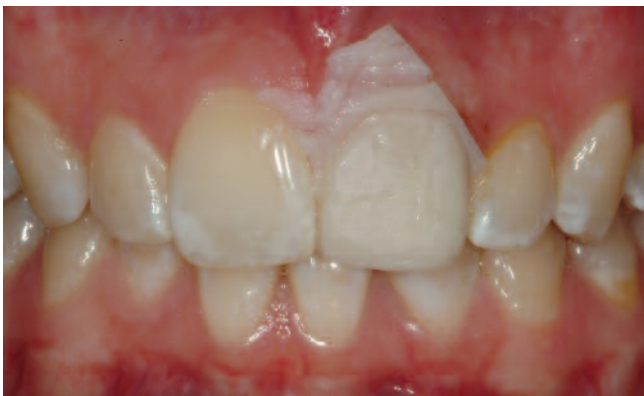

Figure 6: Initial form and colour of acrylic resin temporary crown as matrix is removed

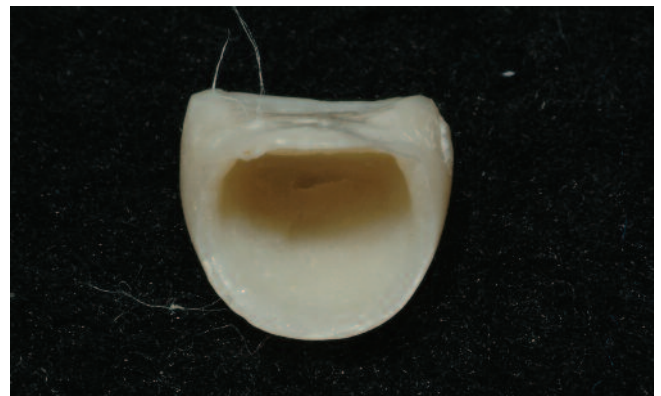

Figure 7: Internal surface of temporary crown

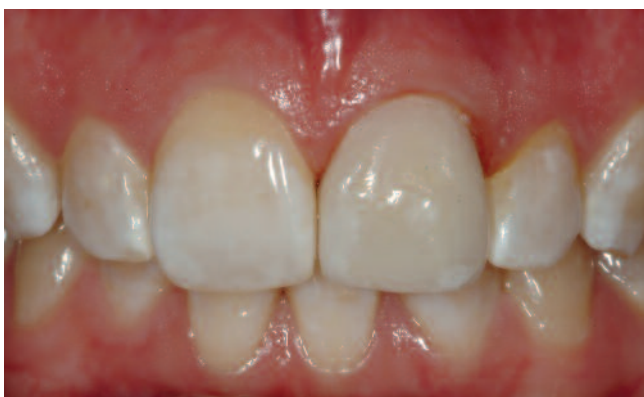

Figure 8: Finished temporary crown. Note accurately trimmed and well fitting margins. A highly polished surface has been created without the use of a surface glaze

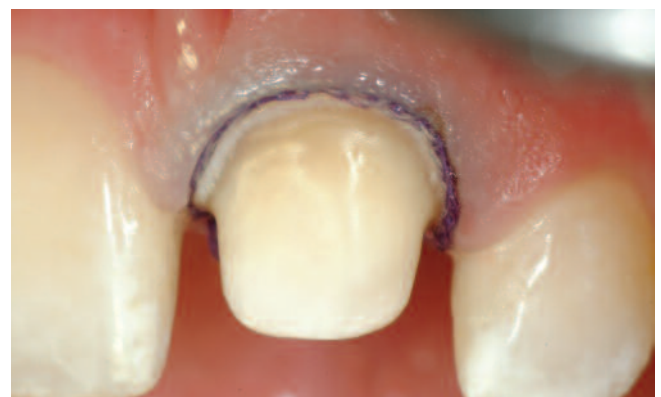

Figure 9: Tooth with single retraction cord in place ready for impression. The cord is removed just prior to the impression

prepared to the desired level.

The impression was made using a polyether impression material (Impregum, 3M ESPE, St. Paul, MN, USA) in a custom impression tray. Despite the fact that the margins were equigingival, a single retraction cord was placed in order to allow impressing of additional tooth structure beyond the margins to aid the technician in creating the correct emergence profile (Figure 9).

Adequate time should be allowed for the technician to

fabricate the crown and neither patient nor dentist should place pressure on the technician to complete the crown. A good temporary crown will remove any time constraints from the technician.

Aesthetic try in

An aesthetic try in of the crown should be made before final staining and glazing is carried out. This allows verification of the crown morphology and colour both of which can still be

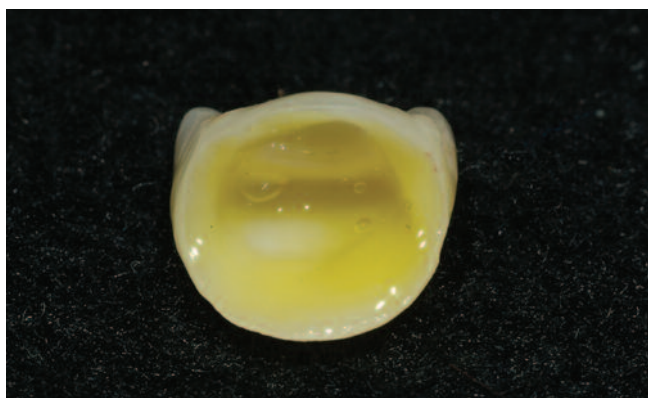

Figure 10: Internal surface of Empress crown being etched with 9% hydrofluoric acid

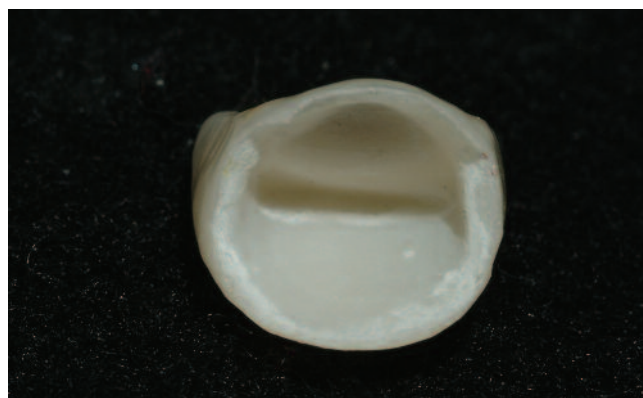

Figure 11: Internal surface of crown after etch. Note white precipitate which needs to be removed

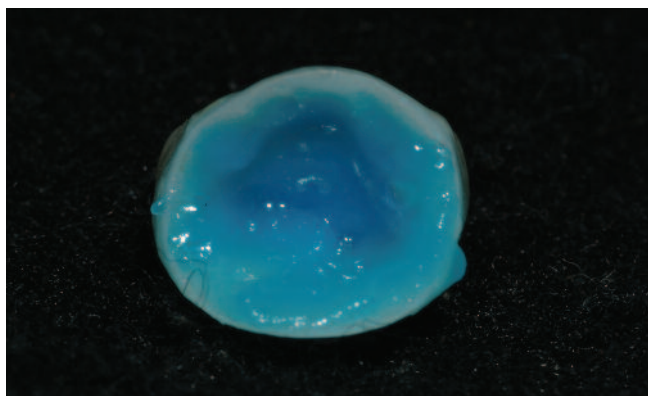


Figure 12: Removal of precipitate with 36% phosphoric acid. This should be agitated with a microbrush



Figure 13: Well etched, clean, internal surface after removal of white precipitate. Compare with Figure 11

modified at this stage. The technician should be present at this try in appointment and depending on the results, the next step will range from simple finishing of the crown to a total remake of the crown. If the crown does need to be remade, a good temporary will alleviate any time constraints as neither patient nor dentist will have any problem with leaving the temporary crown in place until a satisfactory result can be achieved.

Cementation

Once the technician had completed the final crown, it should be returned to the dentist in an unetched state. This allows for optimal preparation of the internal ceramic surface by the dentist after the crown has been tried in and approved for final cementation. The crown should be tried in with a clear medium such as glycerine. Aspects such as contact points and occlusion are assessed and adjusted. Only once the aesthetics, fit and function of the crown has been approved by the patient, dentist and technician can the cementation process begin. The cementation protocol for a resin bonded, glass based ceramic crown is similar to that of a porcelain veneer. Following try in, the internal surface of the crown should be thoroughly rinsed with water and cleaned with alcohol and then treated as described by Magne and Cascione (2006) as follows:

- 90 second etch with HFI (9%) (porcelain etch) (Figure 10)

- Rinse thoroughly with water and check for white precipitate (Figure 11)
- Scrub internal surface with 36% phosphoric acid (tooth etch) (Figure 12) and then rinse thoroughly.
- Ensure that white precipitate has been removed and a frosty porcelain surface exists (Figure 13)
- Apply fresh silane, leave for 60 secs and then dry thoroughly with hot air (hairdryer).
- Apply bonding agent and protect from light.

Preparation of the tooth for resin bonding

- Apply rubber dam. A butterfly shaped rubber dam clamp (Ash 212) is used and can be stabilised on the adjacent teeth with warmed impression compound (Kerr) (Figure 14)
- Etch tooth with 36% phosphoric acid (Figures 15 and 16)
- Apply bonding agent – do not cure

A dual cured resin luting cement was used for bonding the crown in place (Variolink II. Ivoclar Vivadent, Liechtenstein).

Cementation of the final crown under rubber dam ensures a dry field for resin bonding and facilitates direct vision and access for cleaning of excess cement. All cement should be removed before polymerisation and any residual cement remaining after polymerisation should be removed with a sickle scaler or a #12 scalpel blade (Figure 17). No rotary instruments

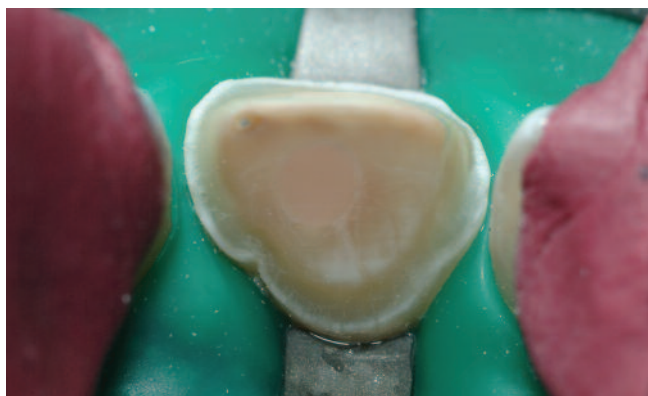

Figure 14: Rubber dam applied to tooth using 212 clamp stabilised with impression compound. Note exposure of all margins and engagement of clamp jaws on tooth and not gingivae

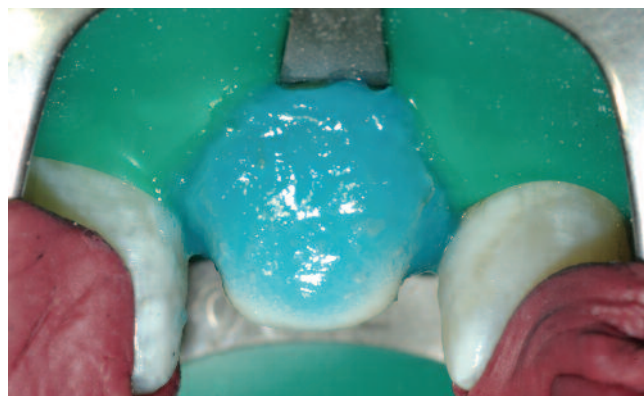

Figure 15: Etching of the entire tooth surface for 30 seconds with 36% phosphoric acid

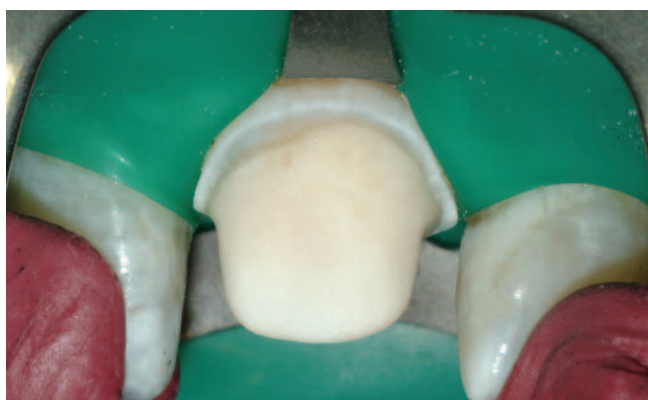

Figure 16: Etched tooth surface

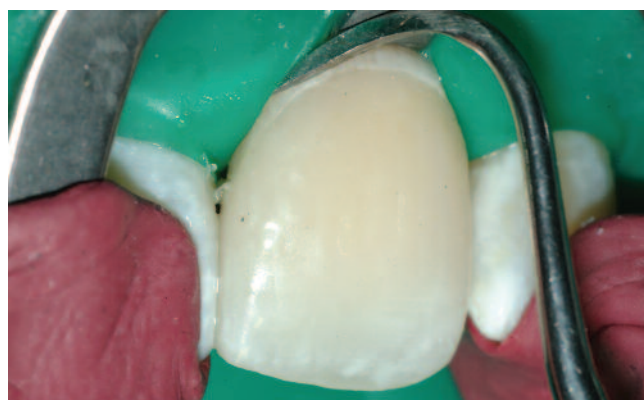

Figure 17: Cleaning of excess cement after polymerisation with sickle scaler. Note the access and good vision made possible by the rubber dam retraction

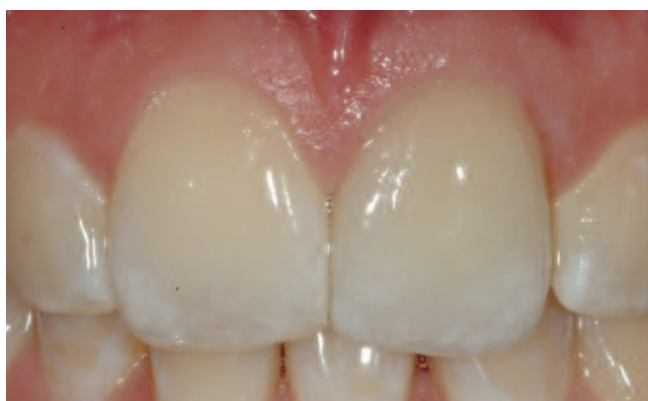

Figure 18: Final restoration 10 days after cementation. Note healthy gingival margin despite use of rubber dam clamp

should be used on the margins of the restoration after cementation. Once all the excess cement has been carefully removed, the rubber dam clamp is removed. Initially the gingivae around the area will appear however this is a temporary phenomenon and when used carefully, rubber dam clamps will not cause any permanent gingival recession. Gingival health should return to the area within 7 – 10 days (Figure 18).

Discussion

A common reason for replacement of anterior crowns is gingival recession and exposure of the crown margins. In certain situations, utilising adhesive technology, it is possible to create invisible margins that are not dependant on concealment by the gingival margins.

Criteria necessary for achieving these imperceptible margins are:

- Use of a translucent and etchable glass based ceramic crown to allow blending with the underlying and adjacent tooth margins.
- Enamel margins for optimal resin bonding
- Access for rubber dam application to ensure optimal resin bonding
- Good underlying tooth colour
- Minimal tooth destruction at the marginal level so that margins do not need more than 1mm reduction.

The presence of all these factors offers the most favourable chance of obtaining a good match between a single anterior crown and the adjacent natural teeth.

However despite these favourable factors, the dentist needs to ensure that sufficient time is allowed for the technician to

produce the single crown. Often this may require multiple try ins and even remaking of the crown. A well fitting and aesthetic temporary crown allows this time to be created and allows the dentist and technician to continue on with treatment until success is achieved.

Acknowledgement

Dennis Mostert of Ceramiart, London, UK for the excellent technical work.

References

- Burke FJ, Fleming GJ, Abbas G, Richter B. Four year performance of dentine-bonded all-ceramic crowns. *Br Dent J.* 2007 Mar 10;202(5):269-73.
- Burke FJ, Qualtrough AJ. Effectiveness of a self-adhesive resin luting system on fracture resistance of teeth restored with dentin-bonded crowns. *Eur J Prosthodont Restor Dent.* 2006 Dec;14(4):185-8.
- Burke FJ. Follow-up evaluation of a series of dentin-bonded ceramic restorations. *J Esthet Dent.* 2000;12(1):16-22.
- Burke FJ. Maximising the fracture resistance of dentine-bonded all-ceramic crowns. *J Dent.* 1999 Mar;27(3):169-73.
- Burke FJ, Qualtrough AJ, Hale RW. Treatment of loss of tooth substance using dentine bonded crowns: report of a case. *Dent Update.* 1998 Jul-Aug;25(6):235-40.
- Burke FJ, Qualtrough AJ, Hale RW. The dentinebonded ceramic crown: an ideal restoration? *Br Dent J.* 1995 Jul 22;179(2):58-63.
- Douglas RD, Przybylska M. Predicting porcelain thickness required for dental shade matches. *J Prosthet Dent.* 1999 Aug;82(2):143-9
- Magne P, Cascione D. Influence of post-etching cleaning and connecting porcelain on the microtensile bond strength of composite resin to feldspathic porcelain. *J Prosthet Dent.* 2006 Nov;96(5):354-61
- Materdomini D, Friedman MJ. The contact lens effect: enhancing porcelain veneer esthetics. *J Esthet Dent.* 1995;7(3):99-103
- Mizrahi B. Temporary Restorations: The Key to Success. *Alpha Omegan*, 2007, 100, 2, p81
- Vichi A, Ferrari M, Davidson CL. Influence of ceramic and cement thickness on the masking of various types of opaque posts. *J Prosthet Dent.* 2000 Apr;83(4):412-7