

PERI-IMPLANT SOFT TISSUE RECESIONS: PREVENTION AND TREATMENT: A REVIEW

ANDRE P SAADOUN & GUY MORIOUSSEF

Introduction

As all perio-implantologists know, a beautiful aesthetic result is difficult to obtain with implants in the anterior areas. Both the alignment of the gingival margin and the presence of papillae are essential elements in resolving aesthetic implant problems in the anterior region. These two soft tissue entities, however, are closely related to the biotype and to the quality and quantity of underlying structural alveolar bone.

The peri-implant gingiva, particularly if it is narrow, with a thin-scalloped biotype, inevitably retracts six months after the abutment connection and restoration, owing to the re-formation of the biologic space (*Small and Tarnow, 2000*).

The process of soft and hard tissue healing must be understood and incorporated into a carefully coordinated sequence of therapy. It is also important to identify complications and clinical mistakes and their implications on the final aesthetic outcome (*Saadoun et al, 1999*).

How, then, should soft tissue recession (bone and gingiva) around an implant be prevented or treated?

Biological rationale

The predictability of the peri-implant aesthetic outcome is ultimately determined by the patient's particular anatomical condition, and also by the clinician's ability to manage the different procedures without trauma to the site or invasive surgery.

In a natural healthy dentition, tooth contour and bone architecture determine the gingival height and form, as there is an interrelation between the two entities and the formation of the biological width. Whereas the biological width is located supracrestally for the teeth, it is almost always subcrestal around the implant.

There are several differences in length, histological composition and vascularity between the biologic width around a tooth and around an implant. In implantology, marginal bone is the key to aesthetic soft tissue contour. After tooth extraction, one must therefore attempt to ensure retention of the buccal bone lamella (*Spear, 1999*).

To obtain ideal implant aesthetics, the papilla height and form should be restored to correspond to that observed with natural teeth.

*Dr Andre P Saadoun, DDS, MS, is in private practice, Paris, France
Diplomate, American Academy of Periodontology*

*Dr Guy Morioussef, DDS, is in private practice, Montpellier, France
Post Graduate in Perio-Implant-Prosthodontics*

When single implants are placed adjacent to natural teeth, a predictable esthetic result can be achieved provided the supporting tissues of the natural dentition are healthy, in which case implants placed adjacent to natural teeth with normal bone levels will have normal papillary peaks, since the natural roots contribute to the stability of the bone and gingival papillae.

When two or more adjacent implants are placed in the anterior maxilla, predictable aesthetics is often difficult to achieve, and the inter-implant papillae typically form at a level apical to that of the interdental papillae of the adjacent dentition (*Elian et al, 2003*).

In the anterior tooth region, retention of, or regeneration of a papillary height of 4-5 mm can be achieved if the inter-implant distance is at least 3 mm, if the inter-implant buccal bone volume is augmented in order to prevent all-too-commonly occurring crater-like bone resorption, and if the thickness of the buccal lamella is at least 2,5 mm for optimal support of the soft tissue.

Prevention of peri-implant recession

Marginal bone loss of 1 mm in the first year following the abutment connection, followed by loss of 0.2 mm per year, were among the criteria defined for implant success (*Albrektsson et al, 1986*). Saving a few tenths of a millimetre of bone around an implant does not increase the longevity of the implant, and should be done only for aesthetic reasons (*Chiche, 2005*). To prevent or to decrease peri-implant bone resorption and consequent gingival recession following implant restorations in the anterior zone, several strategies have been suggested, which are explained in detail in the following points.

Implant design and diameter

A distinct trend of soft tissue recession around all implants has shown to occur between second-stage surgery and the final restoration. Soft-tissue recession around a wide-diameter implant averaged 1.58 mm compared to 0.57 mm around a standard-diameter implant. The wider diameter platform may well provide an enhanced, more anatomically correct emergence profile; but it may be more prudent to use standard-diameter implants in the aesthetic zone to avoid excessive soft tissue recession (*Small, Tarnow, 2001*).

The design of the collar of the implant should stabilize the crestal bone by bringing the roughened surface right up to the

platform, and the thread as close as possible to the platform, with no divergence of the collar walls.

A change in implant design towards a scalloped shape to mirror the bone and soft tissue topography of the natural tooth could help conserve the tissue architecture around the implant by minimizing the bone remodelling induced by the subosseous position of the implant head, thus improving the support of the papilla (Wörhle, 2003).

The thread position of the implant determines the effective level of remodelling after loading, and this is perhaps even more important than the position of the implant abutment microgap. (Rompen et al., 2003). The appearance on the market of implants with a microthread reaching the col seems to follow this recommendation to prevent interdental bone resorption from occurring; however, this must be proven by research.

Implant placement and extraction timing

To make the best choice between different alternatives of implant placement, a precise pre-surgical diagnosis is necessary in order to evaluate the gingivo-osseous parameters, to determine the best moment to extract the tooth and place the implant, and to decide whether implant placement and loading should be immediate, early or delayed (Saadoun and Landsberg, 1997).

The time of implant placement after tooth extraction, whether immediate, delayed or late, is therefore an important part of the treatment plan (Garber et al. 2001), in particular as a means of preventing gingival recession.

Studies of the effects of machined and rough implant collars have shown that the least marginal bone loss with each type occurred when the collar of the implant was placed above the alveolar crest (Alomrami et al, 2005) and 2,5 mm from the buccal gingival margin allowing the normal formation of the biological space (Touati 2003).

Placement of the implant platform 1.5 mm above the bone, helps to minimize bone loss as the biological space around the implants is established on the collar (Leziy, Miller, 2005).

In the case of replacement of two adjacent teeth by implants, it has been recommended (Rungcharassaeng and Kan, 2004) that support of the papillae throughout the surgical and restorative procedures might be improved by progressive extraction of the adjacent teeth and immediate implant placements. The idea is to maintain the bone on either side of the first implant, which would be more likely to act as a stable scaffold for an inter-implant papilla peak, before extracting and replacing the second tooth.

Forced eruption

Orthodontic treatment is the best solution for patients who wish to limit the surgery required for the placement of implants to a single session, and to enhance the hard and soft

tissue profile prior to extraction and implant placement (Salama et al, 1993). During the orthodontic movement, the teeth with their surrounding alveolar bone and gingiva will be displaced coronally, provided any periodontal inflammation has been controlled. Retaining the teeth this way until just before implant placement stabilizes the cortical bone and preserves the convex form of the tissues in the vestibule, thus creating the illusion of natural roots.

Flap design

Immediate implant placement after extraction is usually a flapless surgical procedure, the extraction being done using periostomes to minimise traumatic damage to the hard and soft tissues.

A comparative study on healed sites (Gomez-Roman, 2001) following widely mobilized flaps including interdental papillae, and limited flaps leaving a minimum of 1 mm of interdental papilla, has shown that interproximal and crestal bone loss is greater by 1.2 mm for the wide than for the limited flap.

The use of a tissue punch oriented slightly palataly, could limit the drawback of the proximal recession if the crest thickness is optimal.

Tridimensional implant placement

Functional and aesthetic success of implant treatment in the anterior zone depends not only on the quality of the dental restoration, but also on the eventual contour and stability of the marginal gingiva and the proximal papillae, in harmony with the adjacent teeth (Rompen et al, 2003).

Therefore, the position and orientation of the implant in the tridimensional space are fundamental to the quality of functional, biological and aesthetic results (Saadoun et al, 1998).

Satisfactory morphology of the papilla and of the gingival margin after anterior implant restoration depends ultimately on two factors : implant placement (Esposito et al.1993, Jovanovic, 1999, Grunder et al, 2005) and implant restoration (see paragraph 8).

Tridimensional Criteria for Implant Placement in the "aesthetic zone":

• Mesio-Distal :

1.5-2mm between implant and adjacent tooth
3-4mm between implant and adjacent implant

• Bucco-Lingual :

2-3mm from the cervical height of contour to the buccal surface of the implant platform

• Corono-Apical :

2.5-3mm apical to the bucco gingival margin

If an implant is so placed that it impinges upon the buccal cortical wall, it will definitely induce bone resorption, apical migration of the gingival margin and, consequently a longer

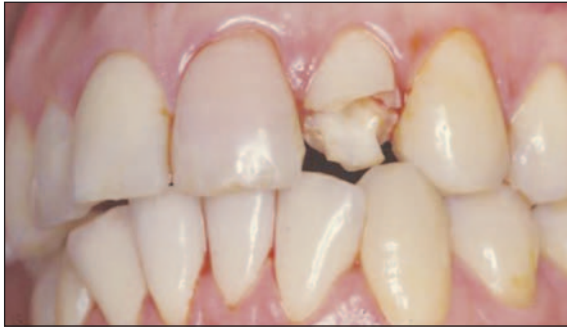

Fig. 1: Fracture of the left maxillary lateral incisor, with a haemorrhage of the adjacent central, following an accident

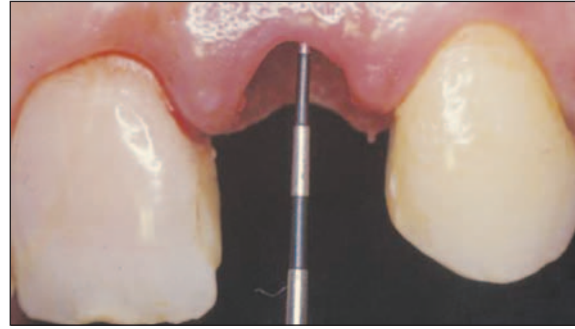


Fig. 2: The implant platform is located apico-coronally less than 3 mm below the buccal gingival margin

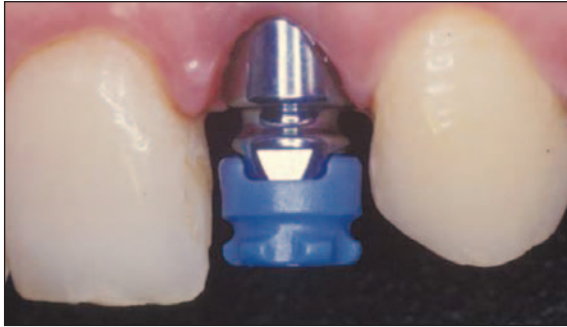

Fig. 3: The impression is taken after implant placement, using the transfer pin with the silicon cap, showing a perfect mesio-distal position of the implant.

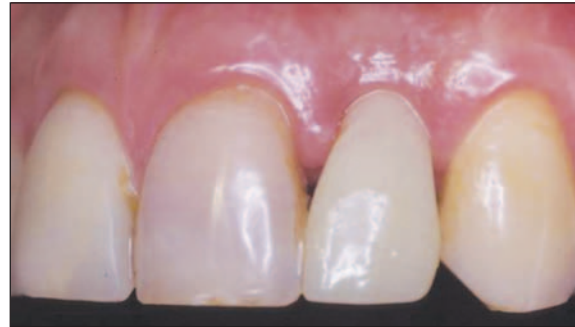

Fig. 4: First temporary crown after immediate implant placement following the extraction showing spaces between adjacent teeth and lack of interproximal papilla.

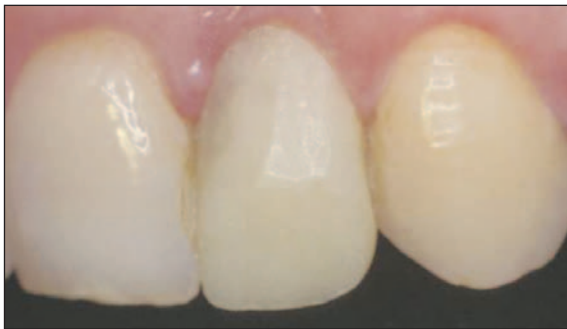

Fig. 5: Chair-side modification of the temporary crown to follow the cervical contour concept (flattening the buccal submergence profile and increasing the convexity of the proximal surface with apicalization of the contact point), in order to recapture the papilla two weeks after.

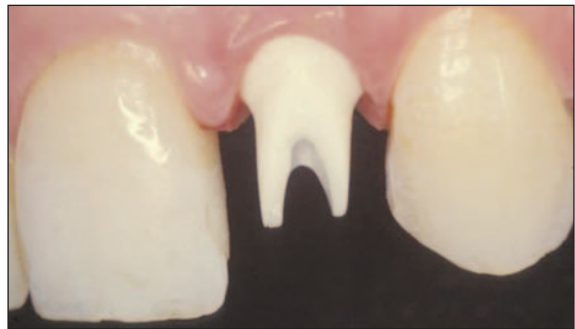

Fig. 7: Placement of the alumina abutment with a flat, buccal submergence profile, and a subgingival preparation of the abutment 0.5mm below the gingival margin and following a normal dental CEJ contour.

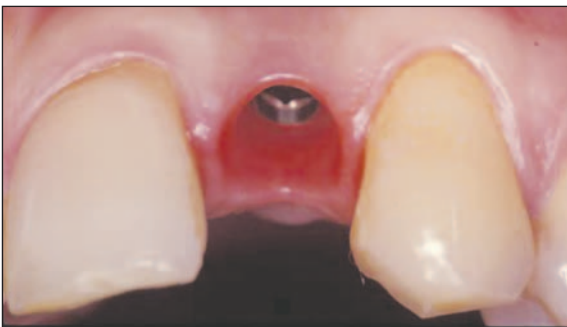

Fig. 6: Soft tissue emergence profile 8 weeks after the removal of the modified temporary crown and of the initial titanium abutment placed at the time of the surgery, showing a perfect submergence and emergence profile and a high level of gingival papilla.

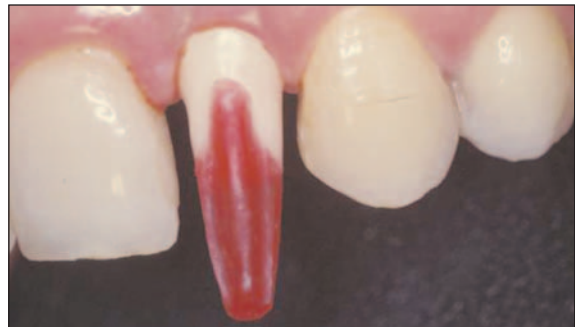

Fig. 8: The Procera shell is placed on the abutment with a Duralay index transfer, to record the new gingival marginal level before making a second impression

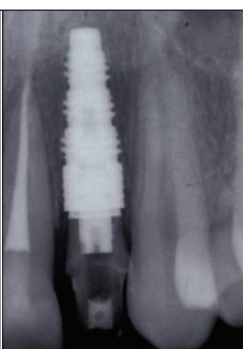
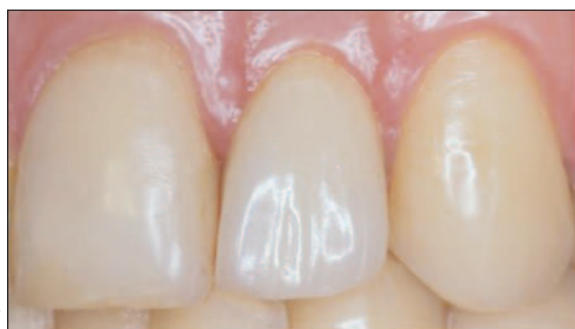

Fig. 9: The control x-ray of the Frialit 2 implant, the alumina abutment, and the Procera restoration

Right: Fig. 10: Procera restoration in perfect harmony with the adjacent gingival margin, showing no recession. The left central incisor has been endodontically treated and bleached internally



aesthetically unsatisfactory crown will be needed (Saadoun et al 1999). Therefore, if immediately post extraction implant placement, with a non-functional temporary crown is indicated, the osteotomy must be performed against the palatal wall to prevent any damage to the remaining (and usually thin) buccal cortical bone (Testori, 2003).

Platelet Rich Fibrin

For a number of years, various forms of platelet concentrates have been used topically during perio-implant surgery.

Platelet growth factors (with all their supposed healing benefits) have taken on a unique form: Platelet Rich Fibrin (PRF). Quite different from the platelet-rich plasma (PRP), prepared and used elsewhere in the world (Marx, 1999), PRF can be considered to be an autologous healing biomaterial: a fibrin clot that concentrates the leucocytes, platelets, and many of the molecules beneficial for immunity and healing into one single membrane (Choukroun et al, 2001).

Within the past 5 years, the use of PRF has developed enormously and has continued to demonstrate its great efficiency and its numerous potential applications in bone grafting and mucogingival procedures (Moriousssef, 2004), including the prevention of peri-implant gingival recession.

Whether PRF functions by a purely mechanical action as a "standard resorbable membrane", or whether it acts in combination with the different factors captured by its fibrin network, thus transforming it into an "active" biological membrane, it has been clinically proven that PRF enables the simple, effective, and predictable management of the gap between alveolar bone and implant. This, in turn, allows the prevention of secondary gingival recession by maintaining the future level of the biologic space.

PRF can be used alone in instances of a minimal gap between bone and implant. In cases of a more substantial gap (case number 2, figures 1-4), or in the absence of one or more cortical walls, in cases of dehiscence, or in extraction sites where immediate implantation is contra-indicated. PRF can be used in conjunction with allogenic bone or with bone substitutes to reduce the number of surgical procedures (case number 3, figures 1-4)

Connective tissue grafts

Gingival biotype plays an important role in determining tissue levels achieved around implants. A thin biotype is generally more susceptible to peri-implant recession, induced by the resorption of a thin labial cortical plate. The use of connective tissue grafts converts a thin gingival biotype into a thick gingiva (Mathews, 2000), which can enhance gingival

marginal stability and simplify tissue management during the restorative treatment phase.

An adequate zone of attached gingiva may also be necessary around scalloped implants to conceal the implant collar and the abutment-restoration interface inter-proximally (Jovanovic et al, 1999; Saadoun et al, 2004).

Abutment and restoration

In order to retain soft and hard tissue around the implant-abutment connection, the transmucosal aspect of the implant abutment should not be oversized and divergent, but rather narrow and concave in order to induce thickening and immobilization of the peri-implant tissues, thus increasing the interface between the implant and the soft tissue, and creating an "O ring connective tissue". This will ensure the long-term stability of the biological width (Rompen et al, 2005).

Optimal aesthetics will be promoted if the final abutment is installed at the time of implant placement, and left in place undisturbed, throughout the final restoration phase, avoiding disturbance of bone and soft tissue architecture. (Rompen et al, 2003). Disconnection and reconnection of the abutment disrupts the biologic zone, so that the junctional epithelium tends to migrate apically beyond the implant-abutment junction until it can adhere again. This often results in marginal bone loss, particularly in cases of thin gingival biotype.

Where a micro-gap is present between implant and abutment, microbial leakage will lead to inflammation and marginal bone loss. Thus, it is important to minimize the bacterial contamination in and around the implant-abutment junction. The seal provided by an abutment of locking-tapered design has been demonstrated to be optimal in this respect, in vitro (Dibart et al, 2005).

Implant abutments of gold or glazed ceramic should be avoided. Only titanium or zirconium abutments are recommended because hemidesmosomes have been shown to attach to them. (Touati and Guez, 2002)

Two weeks after surgery, reshaping temporary crowns by flattening the buccal surface, adding self-cure acrylic on the proximal surface, and apicalisation of proximal contacts at chairside induces: minimum pressure on buccal margin and optimal pressure on adjacent papilla. This Cervical Pressure Concept (Bichacho, Landsberg 1997) is only valid proximally (and not facially), where soft tissue and collagen bundles should be stretched or compressed for papilla stimulation (case number 1, figure 4-6).

The Platform-Switch concept, described by Baumgarten,

CASE NUMBER 2: Courtesy Dr G Morioussef

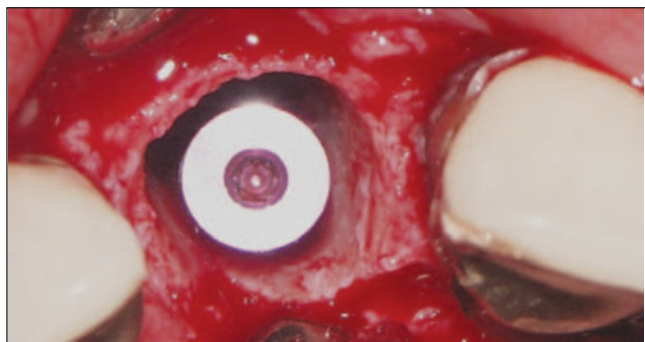


Fig. 1: Immediate implant placement in an extraction site.

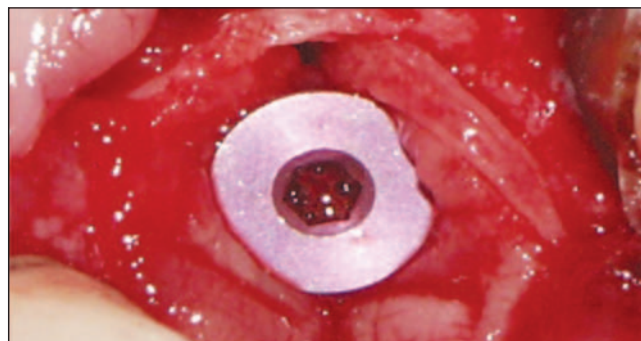


Fig. 2: The wide gap between the implant and the alveolar socket is filled with a folded PRF membrane.

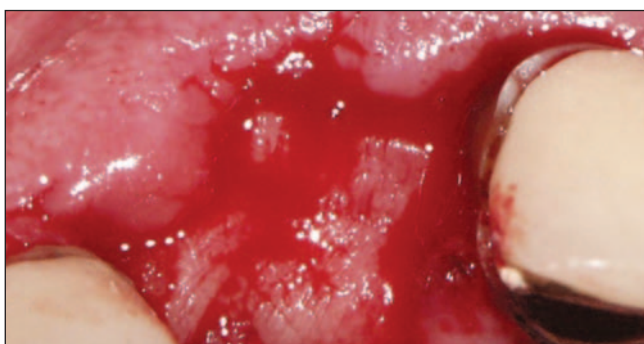


Fig. 3: Two PRF membranes cover the cervical portion of the alveolar socket, before suturing the buccal and palatal flaps.

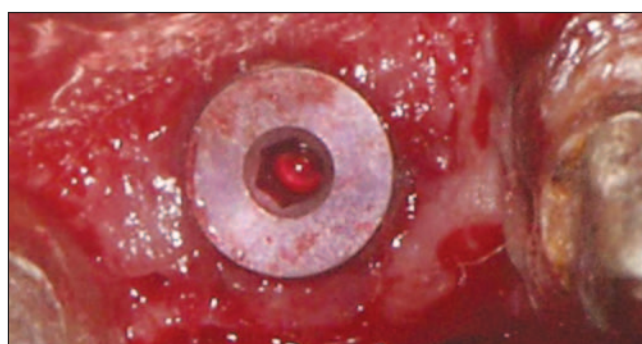

Fig. 4: Healing of the socket after 3 months, showing dense bone around the implant, arriving at the cervical level of the platform.

2005, utilizes an abutment of smaller diameter than that of the implant platform, and a divergent implant collar, to allow the formation of the biological space partially on the uncovered part of the implant platform. The platform incorporates a coronal bevel that mesializes the implant-abutment junction. This strategy, by decreasing the connective tissue attachment inflammatory process, achieves and potentially enhances crestal bone preservation, which decreases the amount of peri-implant cervical bone resorption, and may promote a more predictable soft tissue contour (case number 4, figures 1-4).

Beneath the restoration, the concave abutment should provide maximum space to the soft tissue and clearly avoid a flared geometry. Its submerged profile should be negative to avoid compression of and to allow maximum thickness and stability of the soft tissue, as well as more room for the biologic width (Touati 2004). On the buccal aspect, the emergence profile of both the provisional and the final restorations should be flat or concave (under-contoured), to minimise pressure-induced apical migration of the gingival margin (case number 1, figures 7, 8). As stated above, this again emphasises that the maintenance of papillary form and gingival marginal level depends not only on the tridimensional correctness of implant placement (see paragraph 5), but also on the emergence profile of the crown placed upon the implant:

Design of final crowns to comply with the following "norms" will go a long way towards optimising papillary form (Salama et al., 1999; Elian et al., 2002)

- Distance from interdental bony crest to contact point between natural crown and implant-borne crown: 4.5 mm

- Distance from inter-implant bony crest to contact point between two implant-borne crowns: 3.4 mm
- Distance between bony crest and connection point between an implant-borne crown and a pontic : 5.5 mm

Early placement of single-tooth implants may be preferable to delayed placement in terms of favourable form of interproximal papillae, gingival marginal level, and the achievement of a normal clinical crown height. However, no difference in papilla dimension was seen one and a half years after placement of the implant crown. (Schropp et al, 2005)

The range of natural dental crown-forms has been described as square, elliptical, or triangular. If the parameters in Paragraph 5, above, are respected, then decreasing the distance from the interproximal bony crest or peak to the most apical point of the contact surface between an implant-borne restoration and the adjacent tooth, or between two implants, will result in a more square tooth form, which will disguise the loss of interdental papillary height. This more square tooth form may be particularly noticeable in persons with thin, scalloped gingival morphology, which is generally associated with elliptical or triangular tooth form, (Garber et al, 2001) In these cases some restorative work on the adjacent tooth or teeth may be necessary, particularly when implant restoration is performed on one central incisor (case number 1, figures 9, 10).

Occlusal trauma

The biological response of the bone to mechanical tension around dental implants is similar to that of the articulation of a prosthetic hip implant, with the exception that the zone of

CASE NUMBER 3: Courtesy Dr G Morioussef

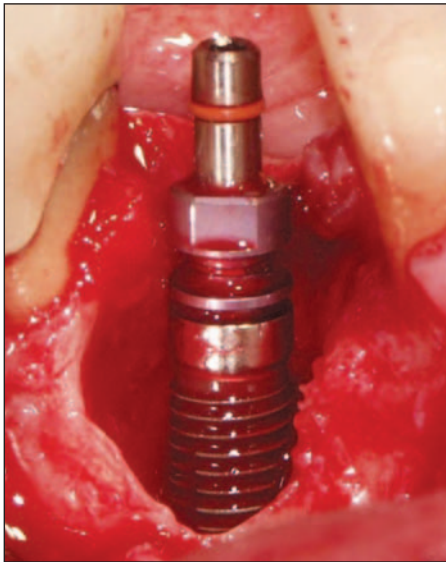


Fig. 1: Immediate implant placement in a wide extraction site, with absence of the buccal cortical plate.

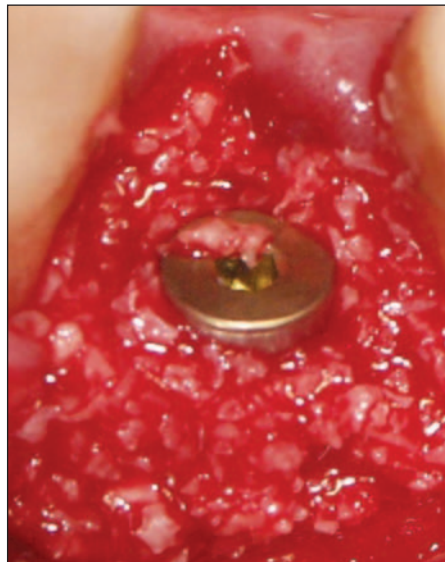

Fig. 2: The space in the defect is filled with allogenic bone material mixed with PRF membrane cut in small pieces.

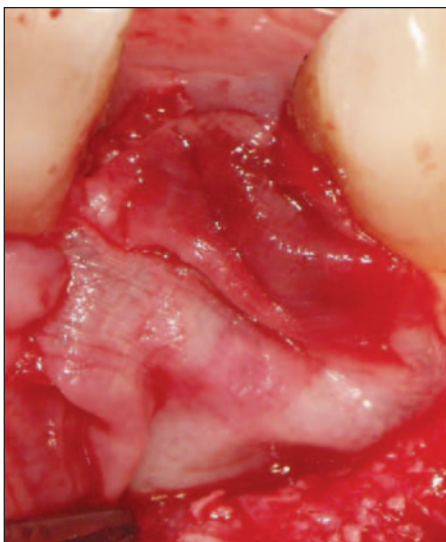


Fig. 3: The surgical site is covered with two overlapping PRF membranes.

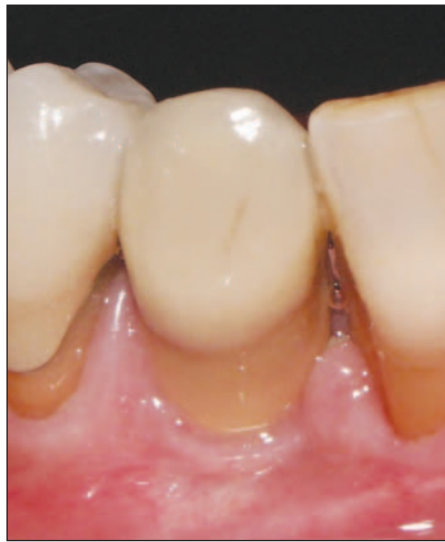

Fig. 4: Final restoration, with a gingival margin at the level of the adjacent teeth.

stress concentration changes. It has been proven that an excessive occlusal load during function can cause the loss of peri-implant bone (Misch et al, 2005). During the first year of function, bone loss around implants in poorly adapted bone follows a similar contour to that of the zone of tension (Kilamura et al, 2004). The control of horizontal, trans-axial forces on an implant during the first months of function is a determining factor in reducing stress in the crestal zone, in enabling bone adaptation, and in minimizing crestal bone loss.

Discussion

Dental implants are now an everyday part of dental clinical practice, and impressive clinical survival and success rates are extensively documented in the literature. By contrast, the scientific documentation of aesthetic successes and of clinical procedures predictably resulting in such aesthetic success in

the field of dental implantology, is more limited.

Innovative implant surfaces, designs, and customized abutments have significantly contributed to 'engineering' the crestal bone and the supracrestal soft tissues thus enhancing the aesthetic outcome of treatment. Similarly, recognizing the form and quantity of the underlying alveolar bone and identifying the surrounding soft tissue biotype, along with meticulous tridimensional implant placement, immeasurably improves aesthetic predictability (Saadoun et al, 2004). Yet despite all this, achieving optimal implant aesthetics still remains a challenge - often an insurmountable challenge - to the restoring dentist. (Leziy and Miller, 2005).

The improved predictability of endosteal implants, as well as a rapidly increasing demand for aesthetics, has made preservation of the alveolar bone height and width critical for ideal implant placement and optimal results. With an intact alveolus, immediate

implant placement is the current treatment of choice, though immediate implantation in the aesthetic zone is still a far from predictably successful procedure, for there remains a substantial risk of loss of existing facial bone, and of soft tissue recession, if tridimensional placement of the implant is less than ideal.

When one or more bony walls of the socket are lost following tooth removal, immediate implant placement is contraindicated. If immediately post-extraction implantation is not possible, then early implantation procedures are recommended because the increase in soft tissue following the healing of the socket will facilitate soft tissue management. This protocol must be weighed against the increased risk of bone loss (Buser 2005), in which case, the lost bone should be restored through a bone graft/membrane procedure.

When an implant is placed in a fresh extraction socket, there are no measures that can be taken to counteract bone

CASE NUMBER 4: Courtesy Dr F Kornmann

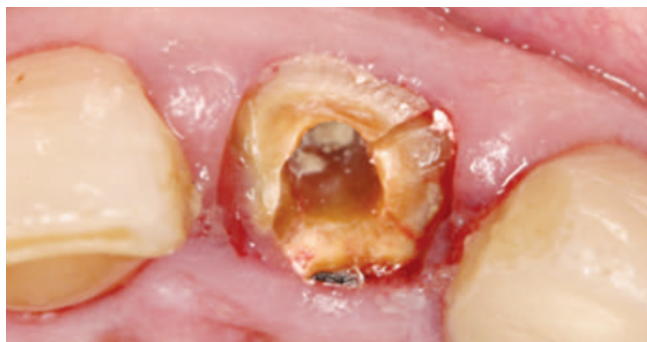


Fig. 1: Buccal-palatal fracture of tooth #9, after removal of the post-core and before extraction

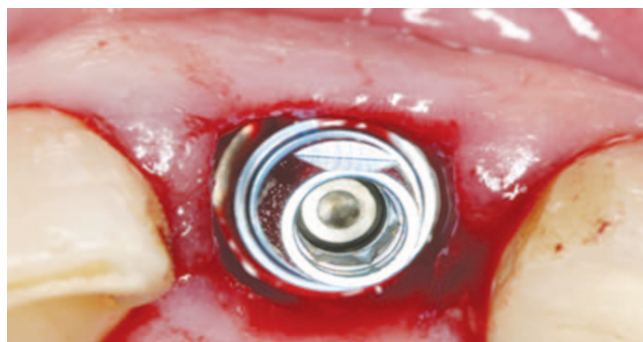


Fig. 2: Flapless immediate implant abutment placement after extraction. The platform switch of 0.5 mm is visible (implant Ø = 5.5 mm; abutment Ø = 4.5 mm).

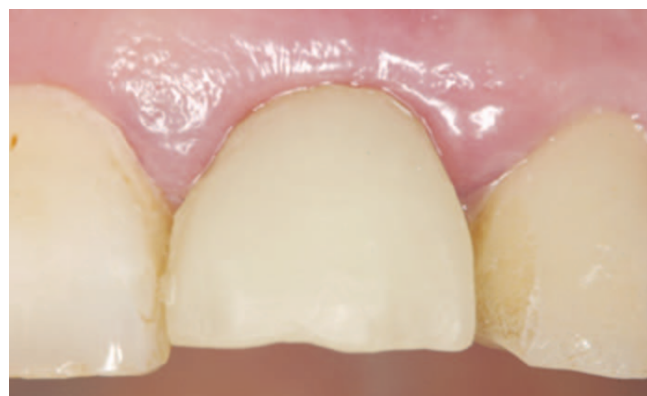

Fig. 3: Temporary crown 1 week after surgery, built on titanium abutment.

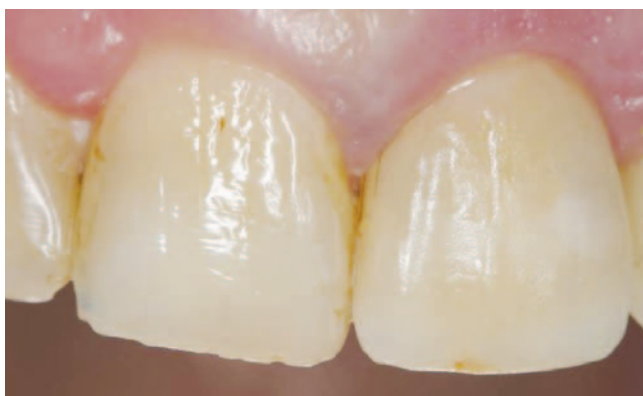

Fig. 4: Final restoration 3 months after insertion. Notice the harmony of the gingival margin level.

resorption. The implant must therefore be so positioned as to anticipate crestal bone resorption. (Araujo *et al*, 2005).

A multi-centric study over a 36-month period has shown that crestal bone loss around an intra-socket implant will range between 1 mm and 2 mm in 83% of the cases and gingival recession likewise between 1 mm and 2 mm in 94% of cases (Wöhrlé, 2000; Wöhrlé 2003).

There is no single technique that offers consistent clinical success in regenerating interdental papillae; however, the problem of loss of papillae can to some extent be pre-empted by maximizing the interimplant distance, minimizing alveolar bone loss, and maintaining acceptable soft tissue height during the implant surgery.

The field of dental implantology has gradually evolved from a macroscopic understanding of implant phenomena to a comprehension of biological principles and microscopic events, so that one is becoming better able to take advantage of, or to influence these factors to advantage, depending on the individual clinical situation. Rough implant surfaces, a deeply located junction in relation to the prosthesis, shallow located undersized prosthetic pillars, spacing between implants, gingival biotypes ... all these are now the subjects of more and more advanced research, that seeks to minimize tissue resorption that was once thought to be inevitable.

All peri-implant mucogingival techniques are derived from periodontal surgery. Peri-implant recession can be prevented by overbuilding the site with added bone on the buccal cortical plate before or during implant placement. Connective

tissue grafts can be utilized in conjunction with implant placement, or during the integration phase, and/or at the time of abutment connection/temporary restoration. A palatal pedicle flap can also be used to improve the papilla and soft tissue contours (Adriaenssens *et al*, 1999; Nemcovsky *et al*, 2000). A buccal pedicle flap combined with a connective graft can also be a useful treatment alternative in a subject with a thick-flat gingival biotype, where there is a substantial width and thickness of gingival tissue on the teeth adjacent to the peri-implant recession.

The clinician should be aware of the fact that marginal bone loss might not always influence or spoil the aesthetic result. This could be attributed, among other causes to the biotype which was not examined in this recently published study (Livin *et al*, 2005).

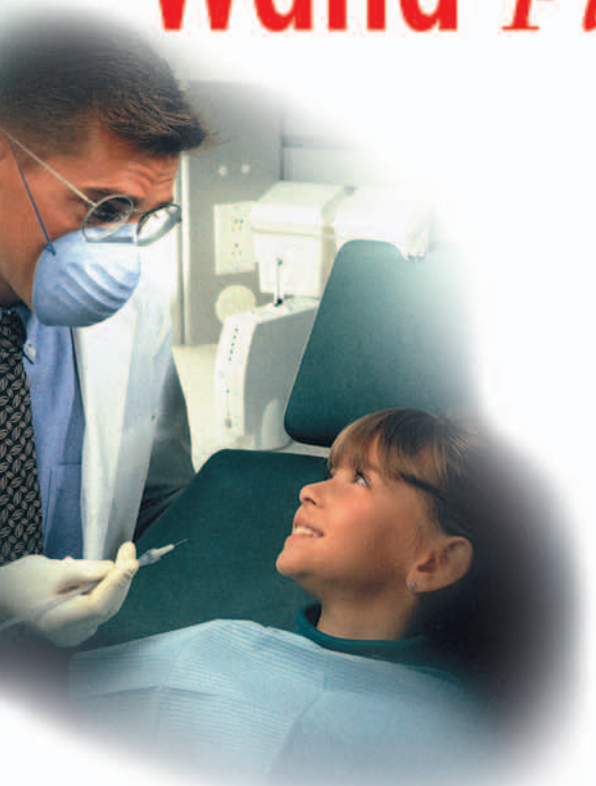Conclusion

The essential prerequisites for an optimally aesthetic implant restoration should always remain a careful, precise, comprehensive, biologically- and prosthetically-based diagnosis, as well as the choice of the most appropriate, most conservative, and least traumatic treatment techniques, aimed at conserving, and where necessary augmenting gingival and bone to achieve a successful outcome.

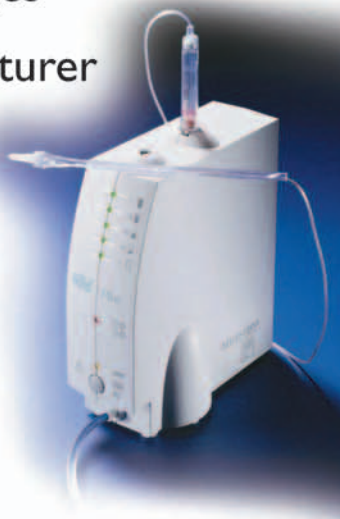Advances in surgical techniques and implant materials have moved implant treatment beyond mere functional integration towards restoratively driven principles, with a heightened awareness that favourable results will largely depend on biologically driven therapy (Touati, 2003).

Painless injections give positive experiences

the Wand[®] Plus



- Two-speed flow control
- Auto-aspirating foot control
- Accepts all 2.2ml glass or plastic cartridges from any manufacturer



HENRY SCHEIN[®] | HALAS
Everything Dental

Call Henry Schein Halas today to experience the magic of The Wand Plus

Tel: 1300 658 822
Fax: 1300 658 810

CLINICAL

The soft-tissue biotype, an adequate alveolar bony process, the optimal tridimensional position of the implant, the submerged abutment shape, and the restoration contour/shade remain fundamental to preventing gingival recession and achieving biological, functional and aesthetic success.

References

1. Adriaenssens P, Hermans M, Ingber A, et al. Palatal sliding strip flap: Soft tissue management to restore maxillary anterior esthetics at stage 2 surgery: A clinical report. *Int J Oral Maxillofac Implants*, 1999;14(1):30-36.
2. Albrektsson T et al. The long-term efficacy of currently used dental implants: A review and proposed criteria of success. *Int J Oral Maxillofac Impl*, 1986; 1:11-25.
3. Alomrami A, Hermann J, Jones A, et al. The effect of a machines collar on coronal hard tissue around titanium implant: A radiographic study in the canine mandible. *Int J Oral Maxillofac Implants*, 2005;20:677-686.
4. Araujo, MG, Sukekava F, Wennstrom JL, Lindhe J. Crestal resorption of an alveola after implant placement: a study on dogs. *J Clin Periodontol*, 2005 June 32(6): 645-652.
5. Baumgarten H. The switch platform concept. Personal communication, International **31** Meeting, Paris, January 2005.
6. Bichacho N, Landsberg CJ. A modified surgical/prosthetic approach for an optimal single implant-supported crown. Part II. The cervical countouring concept. *Pract Periodontics Aesthet Dent*, 1994; 6(4):35-41.
7. Buser D. Good Prognosis with early implantation. *News Geistlich* 2005;1:12-14.
- Chiche F. L'égression orthodontique pré-implantaire: une alternative à la greffe osseuse. *Inf Dent* 2005 ;21 :1285-1239.
8. Choukroun J, Adda D, Schoeffler c, Vervelle A. Une opportunité en paro-implantologie : le PRF. *Implantologie*, 2001;42:55-62.
9. Dibart S, Warbington M, Su MF, Skobe Z. In vitro evaluation of the implant-abutment bacterial seal: the locking taper system. *Int J Oral Maxillofac Implants*, 2005; 20:732-737.
10. Elian N, Jalbout ZN, Cho SC. et al. Realities and limitations in the management of the inter-dental papilla between implants: three case reports. *Pract Proced Aesthet Dent* 2003;15(10);737/744.
11. Esposito M, Ekestubbe A, Grondahl K. Radiological evaluation of marginal bone loss at tooth surfaces facing single Branemark implants. *Clin Oral Impl Res* 1993;4(3):151-157.
12. Frost HM. Bone's mechanostat: a 2003 update. *The Anatomical record part A*, 2003; 275A:1081-1101.
13. Garber DA, Salama M, Salama H: Immediate total tooth replacement in the external root resorption case. *World Dentistry* 1-5, 2001.
14. Garber DA, Salama MA, Salama H. Total tooth replacement. *Compend Contin Educ Dent*. 2001;22(3):210-218.
15. Gomez-Roman G. Influence of flap design on peri-implant interproximal crestal bone loss around single tooth implant. *Int J Oral Maxillofac Implants*, 2001;16(1):61-67.
16. Grunder U, Gracis S, Capelli M. Implantation in the tridimensional space: Aesthetic consequences. *Int J Perio Rest Dent*, 2005; 25(2), 72-83.
17. Jovanovic SA, Paul SJ, Nishimura RE. Anterior implant-supported reconstruction: a surgical challenge. *Pract Periodontics Aesthet Dent*, 1999; 11(5):551-558.
18. Kilamura E, Slegaroui I, Nomura S et al. Biomechanical aspects of marginal bone resorption around osseointegrated implants : consideration based on a three-dimensional finite element analysis. *Clin Oral Implant Res*, 2004; 15:401-412.
19. Leziy, S; Miller, B. Replacement of adjacent missing anterior teeth with scalloped implants: a case report. *Pract. Proc. Aesthet. Dent*. 2005, 17(5):331-338.
20. Livin L, Pathael S, Dolev E, Schwartz-Arad D. Aesthetic versus surgical success of single dental implants: 1- to 9-year follow up. *Pract Proced Aesthet Dent*, 2005;17(8):533-538.
21. Marx RE. *Platelet-rich plasma : a source of multiple autologous*

DVD Instruction Videos

LCS-Volume 1; 3rd edition

Advanced Implant Therapy:
75 minutes approx. running time
by: *Dr. Sascha A. Jovanovic*



LCS-Volume II; 2nd edition

Advanced Implant Therapy:
Ridge Augmentation
110 minutes approx. running time
by: *Dr. Sascha A. Jovanovic*



LCS-Volume III

Advanced Implant Therapy:
Vertical Ridge Augmentation
:60 minutes approx. running time
by: *Prof. Massimo Simion*



LCS-Volume IV

Advanced Implant Therapy:
2 Layer Composite Restorations
:60 minutes approx. running time
by: *Dr. Didier Dietschi*



FLS-Volume I

Ridge and Sinus Grafting in Implant Dentistry
:113 minutes approx. running time
by: *Prof. Massimo Simion and Dr. Sascha A. Jovanovic*



FLS-Volume II

Dental photography for Esthetic Treatment planning
:110 minutes approx. running time
by: *Dr. Brian LeSage*



FLS-Volume III

Esthetic Implant Dentistry:2-disk DVD
:180 minutes approx. running time
by: *Dr. Sascha A. Jovanovic*



FLS-Volume IV

The All Ceramic Crown: Principles of Success
:83 minutes approx. running time
by: *Dr. Ronald Goldstein*



growth factors for bone grafts. In: Lynch SE, Genco RJ, Marx RE, eds. *Tissues and engineering: applications in maxillofacial surgery and periodontics.* Chicago: Quintessence, 1999:71-82.

22. Mathews DP. Soft tissue management around implants in the esthetic zone. *Int J Periodont Rest Dent* 2000;20:141-149.

23. Misch C, Suzuki J, Misch-Mietsch F, Bidez M. A positive correlation between occlusal trauma and peri-implant bone loss: literature support. *Implant Dent*, 2005; 14:108-116.

24. Morioussef G. PRF et chirurgie muco-gingivale. *Implantologie*, 2004;2:69-75.

25. Nemcovsky CE, Moses O, Artzi Z. Interproximal papillae reconstruction in maxillary implants. *J Periodontol*, 2000;71(2):308-314.

26. Nemcovsky CE, Artzi Z. Comparative Study of Buccal Dehiscence Defects in Immediate, Delayed, and Late Maxillary Implant Placement With Collagen Membranes: Clinical Healing Between Placement and Second-Stage Surgery. *J Periodontol* 2002, 73(7):754-761.

27. Rompen E, Touati B, Van Dooren E. Factors influencing marginal tissue remodelling around implants. *Pract Proced Aesthet Dent* 2003;15(10):754-761.

28. Rompen E, Touati B, Van Dooren E. Le pilier Concept. *Alpha Omega News*, 2005; 96(4):39.

29. Rungcharassaeng K, Kan JYK. Aesthetic implant management of multiple adjacent failing anterior teeth. *Pract Proced Aesthet Dent* 2004;16(5):365-369.

30. Saadoun AP. Immediate Implant placement and temporization in extraction and healing sites. *Comp Cont Educ.* 2002;23(4):309-326.

31. Saadoun AP, Landsberg C., *Pract Periodontics. Aesthet Dent* 1997;8: 933-944.

32. Saadoun AP, Le Gall MG. Periodontal implications in implant treatment planning for aesthetic results. *Pract Periodont Aesthet Dent*, 1998;10(5):655-664.

33. Saadoun AP, LeGall MG, Touati B. Selection and ideal tridimensional implant position for soft tissue aesthetics. *Pract Periodontics Aesthet Dent.* 1999;11(9):1063-1072

34. Saadoun AP, Le Gall MG, Touati B. Current trends in implantology: Part 1—Biological response, implant stability, and implant design. *Pract Proced Aesthet Dent* 2004;16(7):529-535.

35. Saadoun AP, Le Gall MG, Touati B. Current trends in implantology. Part II – Treatment planning aesthetic consideration, and tissue regeneration. *Pract Proced Aesthetic considerations and tissue regeneration. Pract Proced Aesthet Dent* 2004;16(10):707-714.

36. Salama H, Salama MA. The role of orthodontic extrusive remodelling in the enhancement of soft and hard tissue profiles prior to implant placement. *Int J Periodontics Restorative Dent*;1993:13(4)-312-333.

37. Salama H et Salama MA, Li TF et al. Treatment planning 2000 : An aesthetically oriented revision of the implant protocol. *J Esthet Dent*, 1999;9(2:55-67).

Schwartz-Arad D, Herzberg R, Levin L. Evaluation of long-term implant success. *J Periodont*, 2005; 76(10):1623-1628.

38. Schrop p L, Isidor F, Kostopoulos L, Wenzel A. Interproximal papilla level following early versus delayed implant placement of single-tooth implants: controlled clinical trial. *Int J Oral Maxillofac Implants*, 2005; 20:753-761.

39. Small PN, Tarnow DP. Gingival recession around implants: a 1-year longitudinal prospective study. *Int J Oral Maxillofac Implants*, 2000. 15(4):527-532.

40. Small PN, Tarnow DP, Cho SC. Gingival recession around wide-diameter versus standard-diameter implants: A 3- to 5-year longitudinal prospective study. *Pract Proced Aesthet Dent* 2001;13(2):143-146.

41. Spear FM. Maintenance of the interdental papilla following anterior tooth removal. *Pract Periodont Aesthet Dent.* 1999;11(1):21-28.

42. Testori T. Ideal implant positioning in maxillary anterior extraction sockets. *Acad News*, 2003;1-13.

43. Touati B, Guez G. Immediate implantation with provisionalization: from literature to clinical implications. *Pract Proced Aesthet Dent.* 2002;14(9):699-707

44. Touati B. Biologically driven implant treatment. *Pract Proced Aesthet Dent*, 2003;15(10):534.

45. Touati B. Biologically driven prosthetic options in implant dentistry. *Pract Proced Aesthet Dent*, 2004;16(7):517-520.

46. Wöhrle PS. Nobel Perfect esthetic scalloped implant: rationale for a new design. *Clin Implant Dent Relat Res.* 2003;5 Suppl 1:64-73.

47. Wöhrle PS. Immediate implant placement and provisionalization: 36-month statistical results. Presented at: 15th Annual Meeting of the Academy of Osseointegration; March 9-11, 2000; New Orleans.