

Endodontic considerations in pediatric dentistry: a clinical perspective

Hani F. Ounsi¹ Dina Debaybo² Ziad Salameh³ Anis Chebaro⁴ Hassan Bassam⁵

Abstract

Despite the best efforts in caries prevention by water and salt fluoridation and systematic controls, caries index remains very high and premature loss of primary teeth is still a current problem. Endodontic procedures such as pulpotomy and root canal treatment aim to preserve the integrity of the dental arch by avoiding early extraction of heavily decayed teeth and subsequently allow for a smoother shift from primary to permanent dentition. Furthermore, retaining primary teeth will also allow for function (i.e., mastication, phonation, and swallowing) and esthetics.

Introduction

The deciduous tooth often presents post-carious pulpal implications that require endodontic treatment. The deciduous tooth goes through different stages during which it witnesses changes of anatomical and physiological nature: the root undergoes resorption and the pulp's reactive potential is diminished or even lost. The tooth has also to be considered within the physiopathological context of the child. The age, general health, and the compliance of the young patient (and sometimes that of the parents) are also factors to be considered before undertaking any treatment procedure.

The aim of pulp therapy in the primary dentition is to retain the primary tooth as a fully functional part of the dentition, allowing at the same time for mastication, phonation, swallowing, and the preservation of the space required for the eruption of the permanent tooth. Furthermore, maintaining esthetics will avoid psychological

problems related to the loss of teeth.

Clinically, the choice of pulp therapy is based on semeiology despite the assessment difficulties and imprecision of pulp tests related to deciduous dentition. The choice between pulpotomy and pulpectomy is generally based on the severity of the symptoms clinically and/or radiographically. When indicated, pulpotomy of the deciduous tooth is relatively an easy procedure with generally good clinical results. Pulpectomy on the other hand is a heavier treatment for the child and is more complicated due to anatomical complexities that are not found in the permanent tooth.

Morphological and physiological properties

According to Finn¹ and Wheeler², the main differences between deciduous and permanent teeth are that deciduous teeth are smaller in all dimensions than permanent teeth, and the mesiodistal/buccolingual crown ratio in temporary teeth is larger than in permanent teeth. Their general aspect is more globulous. Furthermore, the cervical thirds of the buccal and lingual walls are more curved than in permanent teeth and they present a narrowing at the CEJ level, and the buccal and lingual coronal walls converge occlusally, which reduces the width of the occlusal table.

The roots of temporary teeth are longer (as compared to the coronal dimension) and thinner than their permanent counterparts and the pulp chamber is larger with accentuated pulp horns, particularly mesial horns of first deciduous molars. The enamel layer is thinner: 1mm

1 Hani F. Ounsi DCD, DESE, MScB, FICD, Research Department, Lebanese University, Beirut, Lebanon

2 Dina Debaybo DCD, MSc, Diplomate American Board of Pediatric Dentistry, Program Director, Pediatric Dentistry Dental Director, Boston University Institute for Dental Research and Education, Dubai Healthcare City, UAE

3 Ziad Salameh DCD, MScP, PhD, FICD, Research Department, Lebanese University, Beirut, Lebanon

4 Anis Chebaro DDS, Endodontist, Maidan Dental Clinic, Kuwait

5 Hassan Bassam DDS, Pediatric Dentist, Maidan Dental Clinic, Kuwait

Corresponding Author:

Hani F. Ounsi, email: ounsih@gmail.com

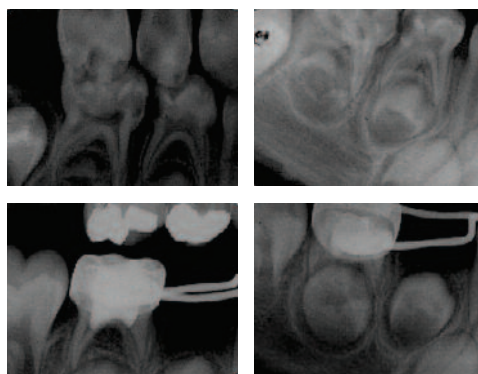


Figure 1: Pre and postoperative bite-wing and periapical radiographs of a pulpotomy procedure, following which a stainless-steel crown and band and loop were placed on tooth #85. Notice the extent of the cameral filling that reaches into the entrance of the root canals.

instead of 1.5 mm for permanent teeth and dentin thickness between the pulp chamber and the enamel layer is less than in permanent teeth.

The pulp of primary teeth possesses the ability to form a dentin-like matrix (tertiary dentin) as part of the repair mechanism of the dentin-pulp complex. In that context, vital pulp therapy procedures (or indirect capping) aim to treat reversible pulpal injury due to caries, restorative procedures, or trauma.³ It is considered nowadays an acceptable procedure at the express condition that the diagnosis is based on good history and proper clinical and radiographic examination, and most important, that the tooth is properly sealed with a leak-resistant restoration.⁴ On the other hand, direct pulp treatment procedures are less predictable as failure is likely to occur even in the case of a pinpoint pulp exposure free from oral contaminants and that occur under rubber dam isolation.⁵ Such teeth should generally be treated using alternate and less alternative procedures such as pulpotomy or pulpectomy.

Pulpotomy

According to the American Academy of Pediatric Dentistry, pulpotomy is the ablation of infected or affected pulp tissues leaving the residual vital pulp tissues intact, thus preserving vitality and function (totally or partially) of the radicular pulp⁶, and the remaining pulp stump is covered with a capping agent. The only difference between pulp capping and vital pulpotomy resides in the quantity of pulp tissue that is removed. In case of vital pulpotomy on permanent teeth, an agent allowing the cauterization of the amputated site is used such as calcium hydroxide. However, the success of this technique as previously stated is rather low and is conditioned by 3 parameters: the tooth must be in stage 1 (roots still in formation), the trauma

relative to the operatory procedure must be minimal, and a high-pH calcium hydroxide must be used. If primary teeth are in stage 2 or later, non-vital pulpotomy should be performed, and the residual stump covered by a pharmaceutical fixative agent such as formocresol. The success of either treatment is measured by the absence of clinical symptoms such as pain or edema, the absence of radiologic symptoms such as internal resorption or intracanal calcifications, the absence of periodontal involvement, and finally the preservation of the integrity of the definitive germ or permanent bud.⁷

Theoretically, following access opening and total cameral roof removal, the tissue in the pulp chamber must be completely excised all the way to the pulp stumps or opening of the “infandibulum” (Figure 1). In fact, the level to which the pulpotomy is performed is adjusted according to the clinical judgment of the operator⁷ since all inflammation has to be removed to allow placement of the medication on sound pulp tissues. Several studies have shown that when pulp exposure is traumatic (fracture) or iatrogenic (following cavity preparation), the inflammation is confined to the superficial layer (1-2mm) without bacterial infiltration, and this even in case of prolonged salivary exposure (168h).⁸⁻¹⁰ When carious lesions are extensive and allowing direct bacterial contact with the pulp, inflammation is present between 1 and 9mm from the surface with abscess and pus formation.^{8,10}

Many agents were used in pulpotomy procedures and formocresol was by far the most popular due to its ease of use and excellent clinical results, although longitudinal studies have reported that the clinical success of formocresol pulpptomies decreased with time and that histologic response of the pulp was variable ranging from chronic inflammation to necrosis.¹¹ From another

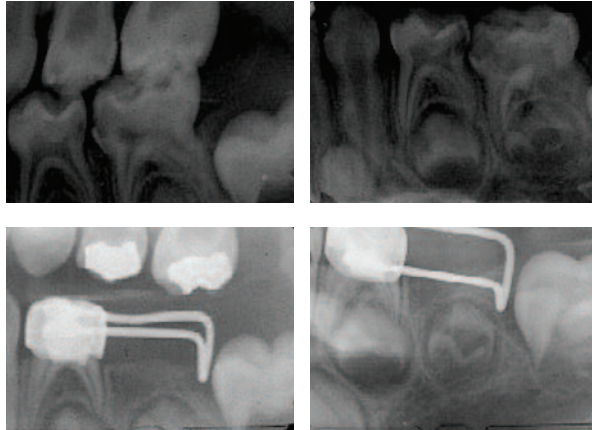


Figure 2: Pre and postoperative bite-wing and periapical radiographs of a pulpotomy procedure, following which a stainless-steel crown and distal shoe were placed on tooth #74. Again, notice the total ablation of the cameral pulp and the extension of the cameral filling to the entrances of the root canals.

standpoint, concerns regarding systemic distribution,¹² potential toxicity,¹³ allergenicity,¹⁴ carcinogenicity,⁷ and mutagenicity¹⁵ of formaldehyde led to seeking alternatives to this product. Among these alternatives glutaraldehyde,¹⁶ electrosurgery,¹⁷ laser,¹⁸ ferric sulfate,¹⁹ collagen,²⁰ freeze-dried bone,²¹ morphogenetic bone proteins,²² and MTA²³ (Mineral Trioxide Aggregate). For the same efficacy, glutaraldehyde is less toxic,²⁴ less allergenic,²⁵ and less teratogenic.²⁶ However, in a 24-months follow-up study regarding pulpomies performed with 2% glutaraldehyde, the authors could not justify replacing formocresol.²⁷ Other authors have examined the 2 products from the toxicity, mutagenicity, and systemic distribution and were not able to conclude to the necessity of replacing formocresol by glutaraldehyde.²⁶ Finally, a Cochrane review²⁸ found that evidence is still lacking to determine which agent is the most appropriate for pulpotomies in primary teeth. Nevertheless, formocresol is banned in some countries mainly for safety concerns.²⁹

Indications

Vital pulpotomy (calcium hydroxide, MTA) is indicated in case of minimal iatrogenic pulp exposure and in case of stage I primary teeth and in permanent teeth. Non-vital pulpotomy is indicated for pulp exposure of primary teeth where inflammation/infection is limited to the coronal portion of the pulp.

Contra-indications

Contra-indications of pulpotomy include unrestorable

teeth, teeth nearing exfoliation, absence of bone between the temporary tooth and the erupting permanent tooth, radicular resorption reaching the cervical third, spontaneous pain, presence of periodontal lesions, absence of bleeding when opening the access cavity, uncontrollable hemorrhage after pulp amputation, presence of purulent or serous drainage, or presence of fistulous tract⁶.

Modus Operandi

After anesthesia and rubber dam isolation, complete excision of carious tissue is performed with a high-speed handpiece. The pulp chamber roof is removed and the pulp content entirely eliminated using a low-speed handpiece under spray or a sharp excavator. Eliminating these tissues has to be complete otherwise hemorrhage would be uncontrollable. The cavity is rinsed with water then dried with cotton pellets. Hemostasis is obtained by compressing the cotton pellets the fixative agent against the pulp stumps in the canal entrances. Hemostasis is normally performed in 4-5 minutes. Failure to achieve it in on time is a sign that inflammation is deeper than suspected. The tooth is not treatable by pulpotomy and the only remaining therapeutic option is pulpectomy.

If formocresol is used to achieve fixation, vapor of formocresol diluted to the fifth is placed in contact with the pulp stumps using a squeezed cotton pellet for 5 minutes. It should be noted that fixation couldn't occur without direct contact between the pulp stumps and the fixative agent. Dilution to the fifth is advised, as it is as effective as full strength while having less toxicity³⁰. When the cotton pellet is removed, tissues should be brownish without signs of bleeding. Zinc-oxide eugenol cements can be used to seal the entrances, covered by a glass-ionomer filling. After setting, either amalgam or composite materials can be used to restore the tooth.

Postoperative follow-up

The failure of a pulpotomy treatment is generally detected radiographically⁷. First signs are generally internal root resorption facing the point of application of fixative agent. It can later be followed by an external resorption. Radiolucent areas develop at the furcation level, at the apex, or laterally on the roots. A fistula may be present and the tooth becomes mobile however, pain is a rare occurrence in failing pulpotomy. Thus, unless the patient is followed regularly, it can go unnoticed until the appearance of the terminal sign which is the loss of the tooth by mobility. Parents and patient alike might attribute this loss to the natural exfoliation phenomenon. From another standpoint, the apparition of a dental abscess that

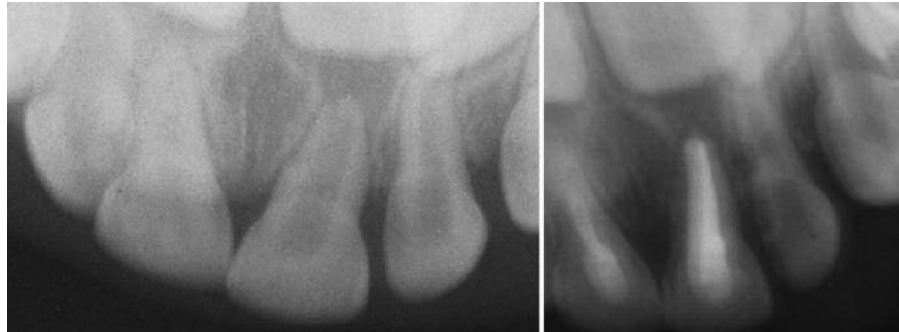

Figure 3: Extrusion of tooth #61 and follow-up root canal therapy treatment in an 18 months old child.

can later evolve into a cystic lesion is possible³¹, hence the necessity of follow-up sessions and control x-rays at 1,3,6 months then 1 year.

Pulpectomy

When the tooth cannot be treated by pulpotomy or in certain failing pulpotomy cases, pulpectomy is the last resort before extraction.

To ensure the success of the root canal treatment on deciduous teeth, the practitioner must be familiar with the mode of formation of their roots as well as the variations that might occur in their root canal system. Root genesis is the same as for permanent teeth. The epithelial dental organ forms Hertwig's epithelial sheath that in turn will initiate root formation by creating a tube prefiguring each root. During this stage, the apical foramen of the tube is delimited by the epithelial diaphragm. When root length is reached, the tube disappears but dentin apposition continues from the root canal side and contributes to the formation of the root canal system and apex closure. Radicular genesis is complete 3-4 years after tooth eruption. The roots of deciduous teeth are more divergent than that of their permanent counterparts which makes space for the bud of the permanent tooth.

The deciduous tooth is unique inasmuch as its roots start to resorb as soon as their edification is completed. At this stage, the shape and volume of the canal correspond approximately to the external shape of the root. The phenomena of radicular resorption and dentine apposition on the surface of the canal modify considerably the aspect and the number of canals. It should be stressed that most variations are in the buccolingual direction and that radiography only show mesiodistal anatomy. Hence the position of the main apical foraminae that is located at the root vertex may often be more coronal. This anatomophysiological characteristic is the cause of radiographic working length errors that can lead to overextension of the shaping instrumentation and overfills that may in turn harm the underlying bud of the permanent tooth. Radicular resorption of the deciduous tooth may create pulpoperiodontal communications far more extended than the apical foramen².

Indications

Pulpectomy is indicated in case of acute pulp inflammation leading to an uncontrollable hemorrhage after pulpotomy, in case of trauma on anterior primary or permanent teeth involving the pulp tissue, and in cases of necrosis and/or periodontal lesions³² (Figures 3-4).

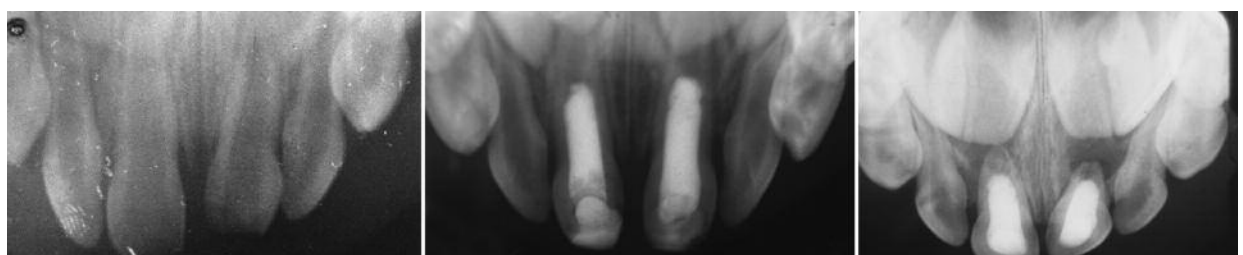

Figure 4: Intrusion of 61 in an 18 months old child. Preoperative, one-year and 4-years follow-up radiographs.

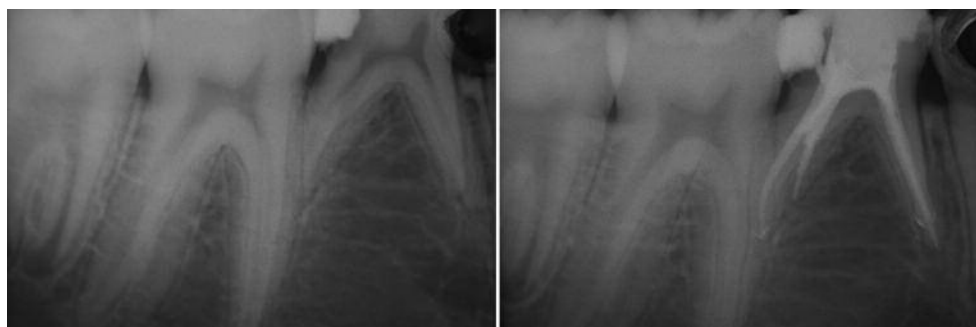

Figure 5: This is the case of agenesis of the lower right second premolar. Lower right second primary molar had conventional root canal therapy performed with gutta-percha obturation.

Contra-indications

They are generally linked to the overall health of the child (special needs, disabled or cardiac patients), or to clinical considerations such as severely broken down teeth, unrestorable teeth, complex root canal morphology, internal or external resorptions, physiological resorption involving more than 2/3 of the root, perforated pulp floor with or without pathological bone resorption³².

Modus Operandi

The pulpectomy technique in itself is rather similar to that performed on the permanent tooth. Following anesthesia and rubber dam placement, the access cavity is performed and the pulpal roof is removed. The bulky shape of temporary teeth helps reducing the enlargement required during access preparation to reach the canal entrances or infundibulum. Nevertheless, all overhanging dentin should be eliminated.

As for their permanent counterparts, Shaping and cleaning are the heart of the endodontic treatment. Estimated root canal length is obtained using a preliminary radiograph and subtracting 1-2mm from the length of the root canal as seen on the radiograph; it is then adjusted by placing a file to the actual length and confirming radiographically. Electronic working length determination is impossible as apex locators are useless on deciduous teeth with regards to their electrical and morphophysiological characteristics³³. It is often preferable to reduce working length by 1-2mm to avoid overinstrumentation and overfilling as these teeth often present with apical resorption phenomena, and preserving the integrity of the apical area is paramount⁶. In general, wide canals (incisors and canines) are shaped to #30 and curved or narrow canals are shaped to #25.

Shaping is done in the conventional manner (step-back) while avoiding ultrasonic shaping instrumentation to

preserve the relatively thin root canal walls. Similarly, Gates-Glidden drills should be avoided because of the increased risk of stripping. Nickel-titanium rotary instruments are ideal for shaping deciduous teeth⁷. Irrigation is more crucial for cleaning since shaping is kept to a minimum and we rely on chemical cleaning to reach areas that were not addressed by mechanical instrumentation³⁴. Using 5.25% sodium hypochlorite combined to 17% aqueous EDTA is capable of cleaning most complexities and irregularities of the root canal system.

Even though a conical shape is preferable, it is not necessary. This is directly related to the fact that the lifespan of such teeth is limited and to the characteristics of the filling material³⁴. Contrary to permanent teeth, filling materials used for root canal sealing of deciduous teeth should be resorbable so they can be eliminated during the physiological root resorption process and not impede the eruption of the permanent tooth. Hence after cleaning and shaping, root canals are rinsed a last time with sodium hypochlorite, dried with paper points, and filled using a zinc oxide-eugenol paste³⁴. Using medicamented paste as iodoform paste is also described although a retrospective study proved that the antibacterial activity of iodoform paste is less than that of ZOE paste while retaining more direct and indirect toxicity³⁵⁻³⁶. The root canal filling paste is placed using a spiral Lentulo-type paste filler and packed in the access cavity using a wet cotton pellet. Using pluggers or syringes (Messing Root Canal Gun, PD, Vevey, Switzerland) is also possible although there are no significant differences between these filling procedures³⁷. Nevertheless, irrespective of the filling material or technique, the only constant is that overfilling should be avoided. The coronal access is then sealed using a glass-ionomer and a preformed metallic stainless steel pedodontic crown is placed to avoid tooth fracture. In case the tooth is to be maintained on the arch, root canal filling

may be performed using gutta percha (Figure 5).

Postoperative considerations

Follow-up is indicated with criteria for clinical success being no mobility, pain, fistula or abscess; and criteria for radiologic success being no pathological resorption and no radiolucencies.

Conclusion

The success of the endodontic treatment on deciduous teeth cannot be conceived without knowledge and understanding of pulp morphology, root genesis and resorptive processes related to deciduous teeth. One must bear in mind that the abovementioned treatments are not absolute. The approach regarding endodontic treatments on deciduous teeth developed from clinical and histological studies. Research breakthroughs in these fields are very likely to yield modifications in these treatments that would possibly improve the prognosis of our treatments. Meanwhile, keeping to rational fundamentals in case selection and operative techniques, pediatric endodontics remains a major benefit to the child's health and wellbeing.

Reprinted with permission from Dental Horizons

Ounsi HF, Debaybo D, Salameh Z, Chebaro A, Bassam H. Endodontic considerations in pediatric dentistry: a clinical perspective. Dent Hor 2009;1:5-10.

References

- 1 Finn SB. Morphology of the primary teeth. In : Finn SB et al. Clinical pedodontics. 3rd ed., WB Saunders Co., Philadelphia, 1967.
- 2 Wheeler RC. A textbook of dental anatomy and physiology. 4th ed., WB Saunders Co., Philadelphia, 1965.
- 3 Baume LJ. The biology of pulp and dentin. In: Myers HM, ed. Monographs in Oral Science. Basel, Switzerland: Karger, 1980:67-182.
- 4 Fuks AB. Current concepts in vital primary pulp therapy. Eur J Paediatr Dent 2002;3:115-20.
- 5 Fuks AB. Pulp therapy for the primary dentition. In: Pediatric Dentistry: infancy through adolescence. St Louis, MO: Elsevier, 2005:118-30.
- 6 Guidelines for pulp therapy for primary and young permanent teeth: American Academy of Pediatric Dentistry, Reference manual. Pediatr Dent 1996; 18: 44.
- 7 Camps JH. Paediatric endodontic treatment. In: Cohen S, Burns RC. Pathways of the pulp. 7th ed., St Louis, MO: Mosby Inc, 1998.
- 8 Cvek M, Cleaton-Jones PE, Austin JC, Andreasen JO. Pulp reactions to exposure after experimental crown fracture or grinding in adult monkeys. J Endodon 1982; 8:

391-397.

- 9 Heide S, Kerekes K. Delayed partial pulpotomie in permanent incisors in monkeys. Int Endod J 1986; 19: 78-79.
- 10 Heide S. Pulp reactions to exposure for 4, 24, and 168 hours. J Dent Res 1980; 59: 1910-1913.
- 11 Rolling I, Thylstrup A. A 3-year follow-up study of pulpotomized primary molars treated with the formocresol technique. Scand J Dent Res 1975;83:47-53.
- 12 Myers Dr et al. Distribution of 14C-formaldehyde after pulpotomy with formocresol. J Am Dent Assoc 1978; 96: 805-.
- 13 Myers Dr et al. Acute toxicity of systemically administered formocresol in dogs. Pediatr Dent 1981; 3: 37-.
- 14 Block RM, Lewis RD, Sheats JB, Fawley J. Cell-mediated immune response to dog pulp tissue altered by formocresol within the root canal. J Endodon 1977; 3: 424-430.
- 15 Friedberg BH, Gatner LP. Embryotoxicity and teratogenicity of formocresol on developing chick embryos. J Endodon 1990; 16: 434-437.
- 16 Tagger M, Tagger E, Sarnat H. Pulpal reaction for glutaraldehyde and paraformaldehyde pulpotomy dressings in monkey primary teeth. Endodon Dent Traumatol 1986; 2: 237-242.
- 17 Mack RB, Dean JA. Electrosurgical pulpotomie: a retrospective human study. ASDC J Dent Child 1993; 60: 107-114.
- 18 Shoji S, Nakamura M, Horiuchi H. Histopathological changes in dental pulps irradiated by CO2 laser: a preliminary report on laser pulpotomy. J Endodon 1985; 11: 379-384.
- 19 Burnett S, Walker J. Comparison of ferric sulfate, formocresol, and a combination of ferric sulfate/formocresol in primary tooth vital pulpotomies: a retrospective radiographic survey. J Dent Child 2002; 69: 44-48.
- 20 Fuks A. Pulp therapy of the primaty and young dentitions. Dent Clin North Am 2000; 44: 571-595.
- 21 Fadawi S, Anderson A. A comparison of the pulpal response to freeze-dried bone, calcium hydroxide, and zinc oxide in primary teeth in 2 cynomologous monkeys. Pediatr Dent 1996; 18: 52-56.
- 22 Ranly D. Pulpotomy therapy in primary teeth: new modalities for old rationales. Pediatr Dent 1994; 16: 403-409.
- 23 Eidelman E, Molan G, Fuks A. MTA versus formocresol in pulpotomized primary molars: a preliminary report. Pediatr Dent 2001; 23: 15-18.
- 24 Hill SD, Berry CW, Seale NS, Kaga M. Comparison of antimicrobial and cytotoxic effects of glutaraldehyde and formocresol. Oral Surg Oral Med Oral Pathol 1991; 71: 89-95.
- 25 Ranley DM, Horn D. Distribution, metabolism, and excretion od 14C-glutaraldehyde. J Endodon 1990; 16:

135-139.

26 Feigal RJ, Messer HH. A critical look at glutaraldehyde. *Pediatr Dent* 1990; 12: 69-71.

27 Fuks AB, Bimstein E, Guelmann M, Klein H. Assessment of a 2% buffered glutaraldehyde solution in pulpotomized primary teeth of school children. *J Dent Child* 1990; 57: 371-375.

28 Nadin G, Goel BR, Yeung CA, Glenn AM. Pulp treatment for extensive decay in primary teeth. *Cochrane Database Syst Rev* 2003;CD0033220.

29 Fuks AB. Vital pulp therapy with new materials for primary teeth: new directions and treatment perspectives. *J Endod* 2008;34:s18-24.

30 Fuks AB, Bimstein EC. Clinical evaluation of diluted formocresol pulpotomies in primary teeth of school children. *Pediatr Dent* 1981; 3: 321-324.

31 Myers DR et al. Histopathology of radiolucent furcation lesions associated with pulpotomy-treated primary molars. *Pediatr Dent* 1988; 10: 291-295.

32 Bandon D, Lopez-Cazaux S, Brun-Croese N, Portier R. Endodontie des dents temporaires "Le cercle dentaire" 2003; n°7: 1-5.

33 Ounsi HF. Précautions d'utilisation des appareils de mesure électronique de troisième génération. *Actualités Cliniques et Scientifiques* 1996; 34: 29-.

34 Dummett CO, Kopel HM. Pediatric endodontics. In: Ingle JI, Bakland LK. *Endodontics* 5th ed., BC Decker Inc., Ontario, 2002.

35 Holan G, Fuks AB. A comparison of pulpectomies using ZOE and KRI paste in primary molars: a retrospective study. *Pediatr Dent* 1993; 15: 403-407.

36 Pilipili M. C., Goret-Nicaise M., Dhem A. Effects of zinc oxide-eugenol, used in primary molars pulpectomies, on erupting mandibular premolars in dog. Dental follicle and bone modifications. (In: *The Biological Mechanisms of Tooth Eruption, Resorption and Replacement by Implants* (Z. Davidovitch, ed.), 111-115, Harvard Society for the advancement of Orthodontics, Birmingham, Alabama, 1998

37 Dandashi MB, Nazif MM, Zullo T, Elliott MA, Schneider LG, Czonstkowsky M. An in vitro comparison of three endodontic techniques for primary incisors. *Pediatr Dent* 1993; 15: 254-256.