

# LASERS IN DENTISTRY - AN INTRODUCTION TO NEW TECHNOLOGY

RAJ WADHWANI

There was a time when the academics in dentistry spurned a new technology that had been advancing for more than a decade. Individuals from the institutions criticised the cost, limited utility and lack of evidence (Dentistry 1991; Cobb 1997). This new technology, is the use of lasers in dentistry. It is for good reason that the teaching institutions could not recommend this technology for general use due to initial problems and the availability of traditional, cheaper approaches to solving common dental problems. However, forward thinking universities have used laser technology as a comparative approach to traditional methods to see if their use can possibly enhance treatment outcomes.

Dental practitioners are being encouraged by manufacturers to invest in laser technology to enhance the commercial success of their practices as patient expectations increase (DeShields 1995; Weiner 2004). While this movement is significant in North America and Europe, scepticism in other regions seems to be a common prelude to embracing technology that the Americans will have tested on their ground for several years. It is the commercial back door that has resulted in many practitioners purchasing lasers, by default rather than intention, realising that there are many desirable therapeutic outcomes that only laser technology can provide.

## Lasers in general practice

The general practitioner has many clinical disciplines that can take advantage of laser technology, so much so that a hard and soft tissue laser can be justified in any general practice (Sulieman 2005). However, the specialist will also find a place in their practice for a particular laser wavelength. For example, a diode laser would be invaluable in the periodontal practice.

This article outlines some basic laser science and overviews, as well as common types of laser available to the clinician. Dental resective procedures usually require infiltration or block anaesthesia. However, many of these procedures can be accomplished with lasers without supplemental anaesthesia when there is careful attention to technique.

Raj Wadhvani, BDS LDSRCS(ENG) DGDPRCS(ENG) MFD SRCS(ENG)  
Private practice Cambridge, UK

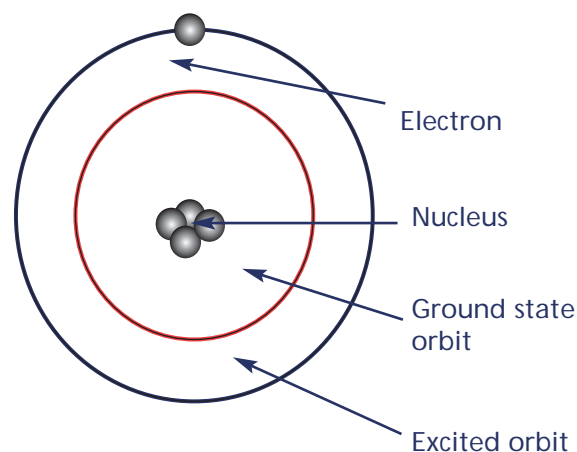


Figure 1: Spontaneous emission diagram.

## Simplified laser physics for dentists

LASER is the acronym for Light Amplification by Stimulated Emission of Radiation.

Spontaneous emission occurs when atoms are excited to a higher energy state, their electrons occupy excited orbits, but spontaneously drop to a ground state orbit with the concomitant release of a packet of energy called a photon (see Figure 1).

Stimulated emission, however, occurs when atoms are energised by heat, light or electric discharge. In a laser (see Figure 2), the pumping source supplies this energy to an optical cavity (resonator), which contains excitable atoms (the lasing medium). As these decay, they release photons of energy. The optical chamber is lined by a totally reflecting mirror on one end and a partially reflecting (partially transmissive) mirror at the other end, resulting in photons 'resonating' from one end to the other, with some escaping through the transmissive mirror. As the 'pumping' from the energy source continues, the number of excited atoms in the medium exceeds the number of ground state atoms. This is called a population inversion. Some excited atoms decay spontaneously to create free photons. These interact with other excited atoms without being absorbed, but also cause decay of the excited atom, which then releases another photon before returning to the ground state. For lasing to

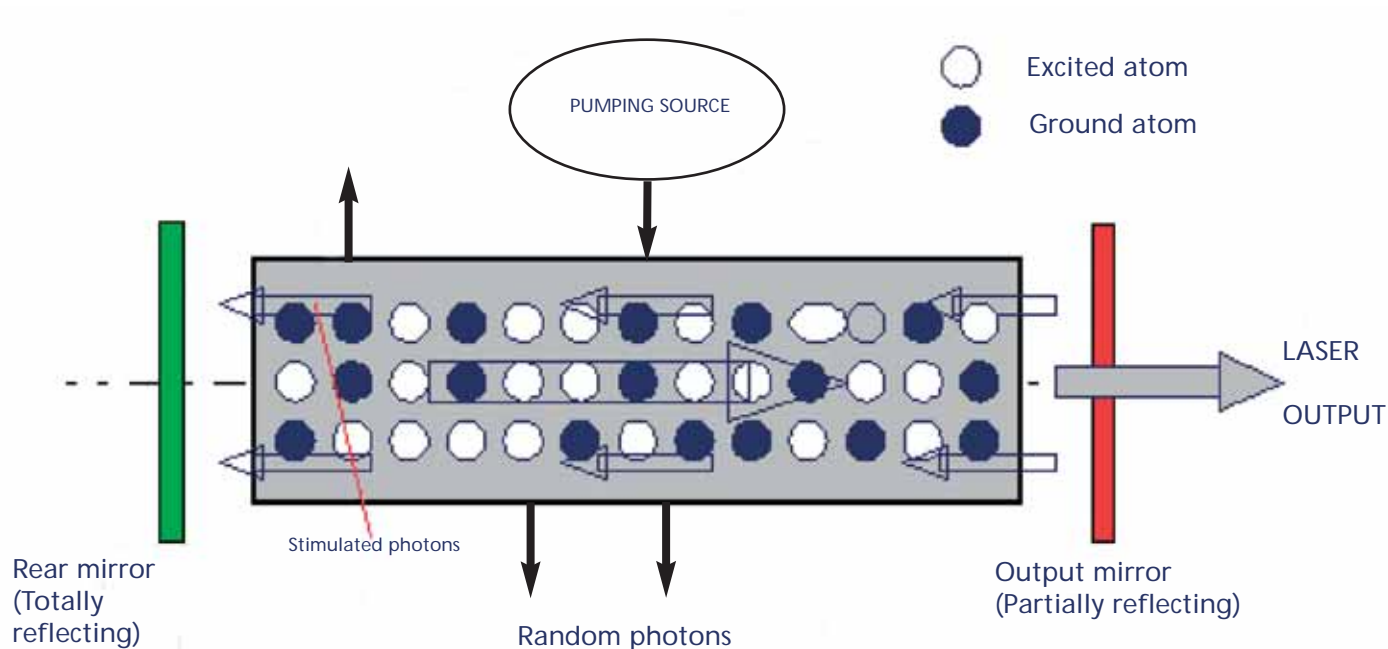


Figure 2: How a laser system works.

occur, the incident photon must carry on with the same wavelength and be in phase with the emitted photon. The two free photons interact with two more excited atoms, generating four photons. This process continues where four becomes eight, eight becomes 16 and so on. The number of photons stimulating excited atoms rises exponentially and results in a photon chain reaction that generates the laser beam. This characteristically is monochromatic (common wavelength), collimated (non-divergent) and in-phase (coherent). This emerges through the partially reflective mirror. The interaction between photons and high energy state atoms results in stimulated emission of photons and the additive effect of these in-phase photons is known as light amplification - hence light amplification by stimulated emission of radiation.

### Laser types

The main types of lasers used in dentistry are the diode laser (810nm–980nm), CO<sub>2</sub> (carbon dioxide, 10600nm) and the YAG family (2100nm – 2940nm) ie ErYAG (erbium yttrium aluminium garnet), ErCrYSGG (erbium chromium yttrium selenium gallium garnet), and HoYAG (holmium yttrium aluminium garnet). These feature predominantly as hard tissue lasers. NdYAG (neodymium, yttrium aluminium garnet) is an effective dental laser wavelength in soft tissue procedures but doesn't feature commonly in many of the units on the British market.

These lasing media produce wavelength specific light, which is selectively absorbed in certain tissues. YAG lasers have an absorption peak in water; therefore the water component of tissues is volatilised before breakdown of structure. Diode and

NdYAG lasers have an absorption peak in pigmented tissue and therefore are good for periodontal tissue lasing and coagulation.

The operator can control the energy applied to the optical resonator, and can vary the beam diameter on the target tissue. The operator can also control pulsing or continuous lasing, pulse duration and pulse relaxation times. These combined will control the target tissue effects.

### Presentation and use

Dental lasers have their technology housed in smart and modern looking containers with parameter setting buttons or LEDs and a delivery arm which may be articulated, be a flexible arm (hollow waveguide) or indeed be an optical fibre, depending on which laser it is.

Typically, the YAG range is recommended for cavity preparation and hard tissue removal, whereas the diode CO<sub>2</sub> and NdYAG lasers are useful for soft tissue procedures.

Hard tissue lasers have handpieces that resemble a turbine to provide the familiar dental feel.

### Pain management

One of the virtues promulgated by the commercial press is the reduced need for anaesthesia. All practitioners wish to enhance their practices by offering their phobic patients pain-free, injection-free and drill-free procedures.

Most soft and hard tissue procedures are achievable with laser technology, from etching to cavity preparation to periodontalplasty to wisdom tooth extraction. Most lasers have controls to change operating parameters, eg pulse

energy, pulse frequency, pulse duration, pulse relaxation (see Figures 3 and 4).

Dentists have been highly trained to cut tissue in a speed-efficient manner. It is against this backdrop of training that laser novices commenced their journey with lasers by dialling in parameters that result in expeditious removal of tooth tissue. Such dentists found to their disappointment that lasers do not offer the anaesthesia-free solution they sought and in fact char the tissues, which subsequently demonstrates poor healing responses. After the 'make haste' set back is overcome, the novice will find ways of cutting tissue at a reasonable pace, without the need for injections. Lasers must be set at the lowest setting possible to achieve the planned therapeutic outcome. It is poor clinical practice to keep energy settings high to speed up tissue ablation.

When using an ErYAG laser at 8Hz frequency with pulse energy 250mJ while restoring class V cavities, Matsumoto (Matsumoto, Nakamura et al, 1996) has shown that 80% of individuals can be treated without anaesthesia. Keller (Keller, Hibst et al, 1998) studied patients' responses to conservative treatment. Patients who required fillings were subjected to laser management and traditional mechanical management of cavities that were matched for both procedures to avoid giving laser procedures any advantage. Over 80% of patients reported less discomfort with the laser procedure, and expressed a preference for laser management of caries in future.

### Pain perception and analgesia

Inquiring dental minds will wonder how lasers achieve analgesia of tissues. Rather than achieving analgesia lasers cleverly modify pain perception. The International Association for the Study of Pain (IASP, [www.iasp-pain.org](http://www.iasp-pain.org)) defines pain as, 'an unpleasant, subjective sensory and emotional experience associated with actual or potential tissue damage, or described in terms of such damage.' It is important to realise that the emotional response can cause upregulated pain perception, and therefore the clinician needs to manage the patient's psyche as well as the target tissue.

The following theories of pain perception are relevant to the use of lasers:

- Melzack and Wall Gate Control theory (Melzack and Wall, 1965)
- Descending opioid-related pain inhibitory system as proposed by Basbaum and Fields (Basbaum and Fields, 1984).

There are two components to pain perception: physical and emotional. All tissues have pain receptors called nociceptors that respond to thermal, chemical and mechanical stimuli through A-delta, C and A-beta fibres. The A-delta receptors

contain small, myelinated fibres that rapidly transmit acute, sharp pain signals from the peripheral nerves to the spinal cord. C receptors have larger, unmyelinated fibres that transmit pain at a slower rate and are commonly associated with a long-lasting, burning pain sensation. The A-beta receptors respond to non-painful touch, such as a gentle rub or pressure (see figure 7).

When tissues are treated by means of a drill, laser or scalpel, these activities stimulate A-delta and C-fibre nociceptive input via sensory receptors and peripheral nerves. These peripheral nerves eventually synapse in the substantia gelatinosa of the dorsal horn of the spinal cord (see Figure 6). This region of the spinal cord contains inhibitory influence to the ascending pathways to sense pain. When larger fibres synapse with the inhibitory neurone, the inhibitory response is increased, ie the gate is 'closed' to pain perception. When smaller fibres synapse with the inhibitory neurone, the inhibitory influence is reduced, which 'opens' the gate to pain perception. These activities are called the gate control theory of pain perception and occur in the substantia gelatinosa of the dorsal horn (see Figure 6).

### Ablation versus stimulation

One could speculate on mechanisms to ablate tissue without stimulating sensation. There is a critical threshold that is required to stimulate sensory receptors before an action potential can be generated. At low frequency pulses, eg up to 100Hz at low energies, tissue ablation may occur at a sub-critical threshold. When the threshold is increased, lasers may preferentially stimulate those larger diameter fibres that close the gate to pain. Summation of sub-critical stimulation may result in upregulation of receptor threshold and raise the critical threshold.

In response to tissue damage, several substances are released into the extracellular fluid namely bradykinin, cholecystokinin, serotonin, histamine, potassium ions, norepinephrine, prostaglandins, leukotrienes, and substance P. The latter three substances are known to sensitise the A-delta



Figure 3: An example of a desktop diode laser.



Figure 4: Instrument panel for settings on a ErCrYSGG hard tissue laser.

## CLINICAL



Figure 5a and 5b: Examples of hard tissue lasers available.

and C nociceptors. Laser light may exert a direct effect on the tissues to reduce the production of prostaglandins, leukotrienes and substance P. Many clinicians report a reduction in post-operative inflammation on laser-irradiated sites, which corroborates my supposition.

The substances mentioned above attach to endogenous receptors in the brain, spinal cord and peripheral tissues and activate the descending inhibitory system as proposed by Basbaum and Fields. Stress, fear and excitement also activate the descending inhibitory system. This system produces pain-relieving substances, namely the opioids endorphin and enkephalin. It is conceivable that laser irradiation can also directly stimulate the endogenous receptors that are responsible for activating the descending inhibitory system and encourage release of endorphins much like how TENS (transcutaneous electrical nerve stimulation) units work.

### Emotion management

Clinicians will report their failed analgesia cases, and this is where the emotional response to pain overrides. Pain perception can be exacerbated by memory, therefore it is important for the clinician to 'condition' the patient using a sympathetic approach. This may involve describing laser

sensation in euphemistic terms like, 'you will feel some light pecking' rather than emotive and untrue expressions like, 'you will feel no pain'. Stimuli are filtered through the limbic-hypothalamic system and the frontal cortex influences rational interpretation and response to pain. Individuals with strong memory of painful experiences at the dentist will translate this as physical pain through irrational interpretation of what is actually a minimal pain-evoking activity. The clinician must therefore acquire emotion management skills as he embarks into the world of dental lasers.

Previously, this article focused on mechanisms whereby lasers can reduce and sometimes eliminate the need for infiltrational anaesthesia. The most common use of local anaesthesia in the dental practice is during conservative dentistry. Hard tissue lasers are in their element when used for such procedures. The astute clinician will question the superiority of using a laser over and above the dental turbine:

- Are there any practical advantages to using a laser over a dental turbine?
- Does laser use confer any therapeutic benefit, eg caries protective effect on the irradiated site, elimination of hypersensitivity, better prognosis for pulp exposures when laser used and so on?
- Is the bond strength of composite resin superior to a laser irradiated site?

The lasers used for cutting enamel are usually doped with HoYAG (holmium yttrium aluminium garnet, 2,100nm), ErYAG (erbium yttrium aluminium garnet, 2980nm) or ErCrYSGG (erbium chromium yttrium selenium gallium garnet, 2790nm) crystal, ErYAG being the most popular and heavily researched. CO<sub>2</sub> and NdYAG lasers have also been used for various surface treatments of hard tissues but are rarely used in resective

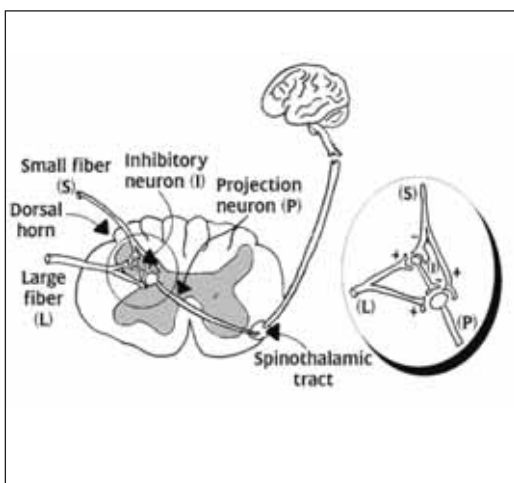


Figure 6: Emotional response created by filtration within limbic-hypothalamic system and memory in frontal cortex.

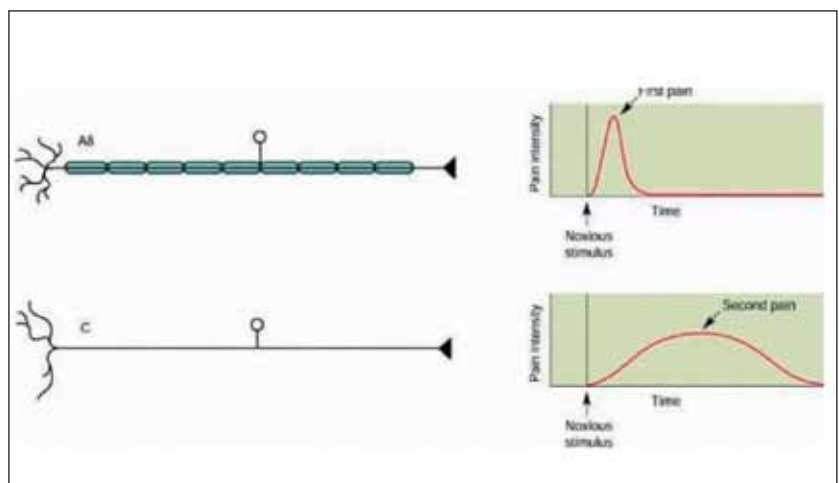


Figure 7: Pain perception in A-delta and C-fibres.

## CLINICAL

procedures of the hard tissues due to poor control. These wavelengths have a specificity for water, therefore laser irradiated enamel and dentine crumbles away as the water component is vaporised. All living tissue including bacterial cells are also vaporised after laser ablation, rendering the sites disinfected after lasing. The antibacterial properties of lasers are well-documented.

### Handpieces

Many lasers have handpieces that appear similar to turbines and deliver water for cooling. The delivered water ablates on

the surface of enamel and dentine and these 'micro-explosions' break down a small amount of tooth structure. Caries contains a greater volume of water and is therefore preferentially ablated.

Laser handpieces are non-tactile and need to be held a small distance from the tooth (1-2mm). This is necessary to focus the laser and eliminates vibration, although there is a low pecking noise during lasing.

When using the laser on gingival tissue, the water spray should be reduced to a minimum to achieve a resective effect. Gingival tissue already contains a large amount of water. If the

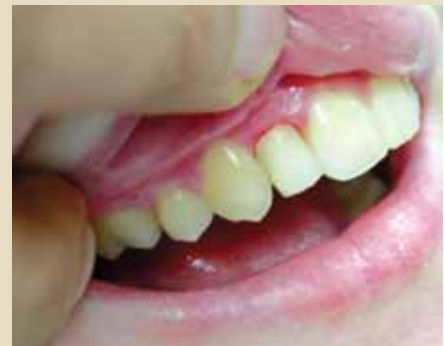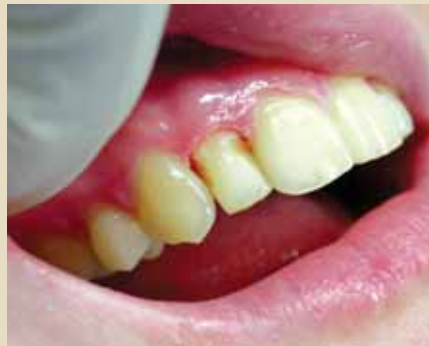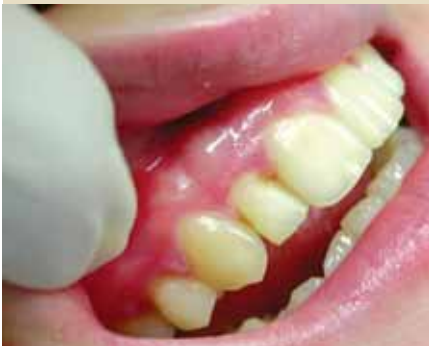### CASE STUDY ONE

Case study one demonstrates hyperplasia of marginal gingivae into a class III cavity. An ErCrYSGG laser was used with water spray to finely resect the marginal gingiva to create a clean, blood-free contour that was restorable with composite resin.

Laser parameters: • 10% waterspray • 2.5 watts • 20 Hz frequency

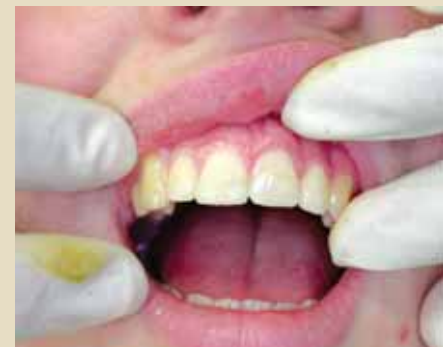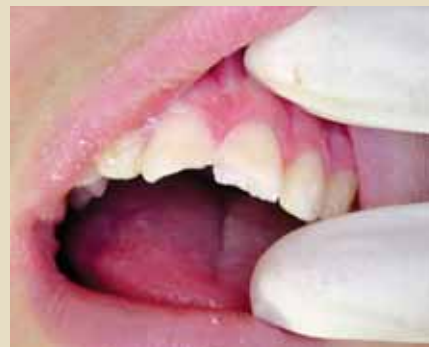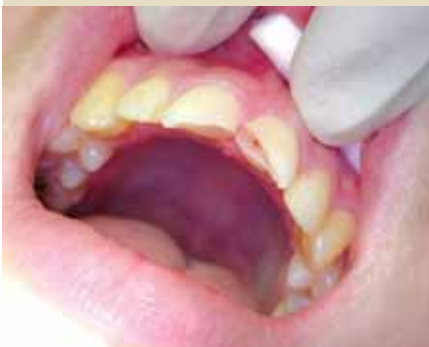The ErCrYSGG laser wavelength is absorbed preferentially by water. Water spray is delivered to the site of irradiation. A greater flow results in less surface ablation as the surface water absorbs the laser energy.

A slower water spray results in deeper target tissue ablation due to absorption of laser energy by water in target tissue. As a result, a precise resection can be carried out at the target site.



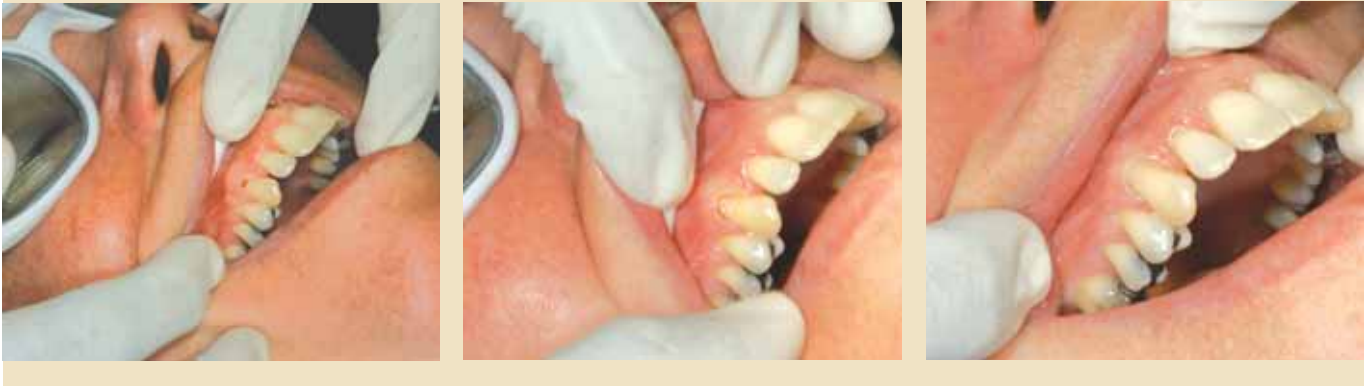### CASE STUDY TWO

Case study two (illustrated by the images below) demonstrate a case of dental trauma of a child who presented within a few hours of the accident. The case was managed without supplemental anaesthesia. The bleeding exposure was sterilised with an rCrYSGG laser with water spray and then coagulated without water spray. A direct pulp cap of setting calcium hydroxide was placed. The surrounding enamel and dentine was etched with a laser before restoration with composite resin. The child was already traumatised by the accident and would not have welcomed a conventional approach with infiltrational anaesthesia, rubber dam, acid etch and so on. The laser facilitated a very simple coronal repair and seal that would have been much more traumatic with conventional approaches.



CASE STUDY THREE

Case study three demonstrates the use of an ErCrYSGG laser for conservation. The patient presents with caries on the buccal aspect of UR3, which extends subgingivally. The marginal gingivae was trimmed back with the laser using a low wattage setting. This revealed the full extent of the cavity. With a slightly higher wattage setting, the caries was ablated, and the composite resin was used for restoration.



laser's water spray is kept on, the irradiance is absorbed by too great a volume of water and the resection will take too long. This is useful where gingival overgrowth has occurred around cavities. The three case studies illustrate some simple conservative procedures carried out with the use of an ErCrYSGG laser without supplemental anaesthesia.

**The benefits of laser use**

There are several reported benefits to using a laser in restorative dentistry:

1. Disinfects as it cuts
2. Can resect inflamed pulp in a pulpotomy procedure prior to direct pulp capping
3. Removes smear layer as it cuts, potentially increasing bond strengths to composite resin
4. Very conservative procedure for microdentistry applications unlike the gross tissue destruction of a bur in a turbine
5. Can cut gingivae, enamel and etch, all with one instrument
6. Can etch old composite, reducing the need for hydrofluoric acid and other surface treatments
7. Use of lasers in conjunction with fluoride treatments increase the anticariogenic effects.

Due to the antibacterial properties of laser light, a vital exposure of the pulp can be managed more effectively than is possible with a turbine. A cornuectomy/partial pulpotomy can be carried out with the laser to amputate the inflamed superficial pulp. The laser can then be defocused by withdrawing from the surgical site by 2-3mm. The irradiance is then spread over a larger surface area. The prolonged but lower irradiance per mm<sup>2</sup> results in coagulation of pulp tissue. This can then be covered with a setting calcium hydroxide paste to facilitate dentine bridge formation.

There is some evidence that laser irradiated sites are more acid resistant (Fox, Yu et al, 1992). Experiments on bovine dentine show laser irradiated sites to be more acid resistant but more difficult to bond to.

**Sensitivity**

Some would hypothesise that lasers are effective tools in treating cervical hypersensitivity by melting and re-crystallising the irradiated tooth surface. Some data on ErYAG studies show superior desensitisation over the longer term than dentine bonding agents (Schwarz, Arweiler et al, 2002).

When removing old composite restorations, it is usually necessary to remove the entire restoration as studies show poor bonding of new to old composite, unless there has been surface treatment by means of surface roughening, silane coupling and placement of unfilled resin (Brosh, Pilo et al, 1997). When using a hard tissue laser, the entire old filling need not be removed as the laser will etch residual composite and facilitate re-bonding by roughening of the old composite surface. However, the longer term efficacy of this needs to be confirmed.

**Bond strengths**

The issue of improved bond strengths to laser irradiated enamel and dentine remains unresolved. Many studies report both superior and inferior outcomes for the total etch technique using 37% orthophosphoric acid.

**To enamel**

Composite resin bonding to enamel is generally very successful and laser technology can only match bond strengths at best. However, microleakage is inferior. Generally speaking, bond

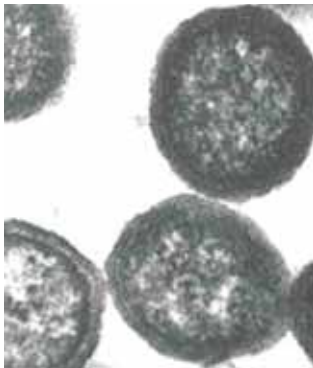


Figure 8: Free bacterial cells.

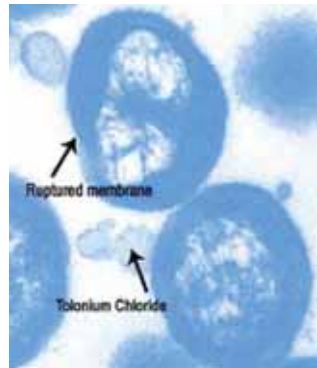


Figure 9: Bacterial cells photosensitised and ablated.

strengths of composite resin to enamel is superior with acid etching compared with laser etching (Trajtenberg, Pereira et al, 2004).

Dual etching with lasers and acid generally does not provide superior bond strengths. The author does not recommend lasers as being a superior form of etching on enamel surfaces, unless these are heavily fluoridated and acid demineralisation does not occur during normal acid etching procedures. This phenomenon is obvious as the typical frosted appearance after acid etching is not seen.

**To dentine**

Composite resin bonding to dentine is more controversial:

- Use of a pulsed NdYAG source may reduce microleakage of composite resin in class V cavities (Obeidi, Ghasemi et al, 2005)
- Bonding of glass ionomer cements to dentine are improved when dentine is irradiated with NdYAG at 3 watts (Kobayashi, Fujishima et al, 2003)
- Flowable composite resin can increase adhesion to ErYAG treated dentine (Donadio-Moura, Gouw-Soares et al, 2005)
- Adhesion facilitated by self etch primers on root dentine may be severely compromised by ErYAG irradiation due to upsetting dentine-resin hybridisation (Van Meerbeek, De Munck et al, 2003; Ramos, Chinelatti et al, 2004).

The laser does prove useful when treating children - for example, when the clinician wishes to avoid infiltration and would like to bond composite resin without a separate acid etch step. The literature reports extensively that use of lasers in conjunction with surface fluoride treatments increases fluoride surface precipitates on enamel and root surfaces, and this enhances the anticariogenic effects of fluoride (Anderson, Ellis et al, 2000; Harazaki, Hayakawa et al, 2001).

**Endodontics**

Lasers provide the clinician with an excellent tool in endodontics. Conventional endodontics uses chemico-mechanical methods to reduce the microbial load of root

canals. Lasers are being considered to disinfect root canals photo-thermally.

One of the goals of endodontic treatment is to eliminate microbial contamination of the root canal system and effect a hermetic seal to prevent re-innoculation by any micro-organisms. The endodontic microflora is polymicrobial and the established lesion has a preponderance of gram negative anaerobes. These bacteria will be very susceptible to chemico-mechanical debridement, oxygenating agents like hydrogen peroxide and sodium hypochlorite.

The failed endodontic lesion may be associated with a different microbiota, one microbiological study indicating the preponderance of gram positive organisms and facultative anaerobes such as *Enterococcus faecalis* predominantly with streptococci, peptostreptococci and *Actinomyces* (Pinheiro, Gomes et al, 2003).

*Enterococcus faecalis* is often cited as one of the main culprits in failed treatment cases (Distel, Hatton et al, 2002). It has been suggested that this microbe forms intracanal biofilms (Distel, Hatton et al, 2002) and by this method becomes resistant to many intracanal dressings. The use of calcium hydroxide, 2% chlorhexidine and monochlorophenol have variable effects (Lima, Fava et al, 2001) but dressings often work better in combination (Podbielski, Spahr et al, 2003). Vitapex (Diadent (US) [www.diadent.com](http://www.diadent.com)) and Metapex (Meta Dental Corp (US), are proprietary endodontic medications that contain calcium hydroxide and iodoform paste and have been recommended to disinfect root canals with persistent infection.

Lasers may be more effective than medications to break up these biofilms by denaturing proteins and volatilising the aqueous component. Dentinal tubules in root dentine are also able to hold bacteria and this may be a cause of treatment failure in some cases. Guknecht (Gutknecht, Franzen et al, 2004) has shown through animal experiments that a 980nm diode laser at 2.8 watts was able to kill 89% of *Enterococcus faecalis* microorganisms to a depth of 500 microns in bovine dentine when irradiated for 32 seconds. In a study to look at the efficacy of ErYAG lasers to disinfect root canals compared with 1% sodium hypochlorite, the laser was found to be at least as effective as hypochlorite when lasing occurred at the apex (lasing parameters approximately 8 joules delivered over 11 seconds). The laser was not as effective 3mm short of the apex (Perin, Franca et al, 2004). The study did not site the disinfection time required for the hypochlorite rinse, however the laser only took 11 seconds to disinfect to a comparable level.

A technique developed more recently known as photo-activated disinfection (PAD) uses tolonium chloride solution to

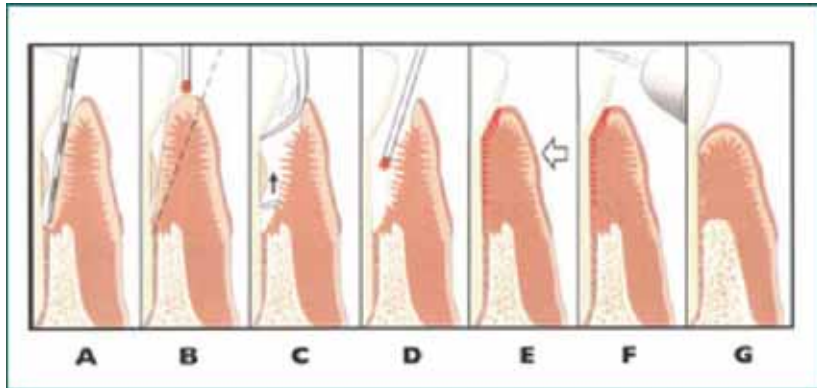


Figure 10: Stages for disinfection and curettage of periodontal pockets with a laser.

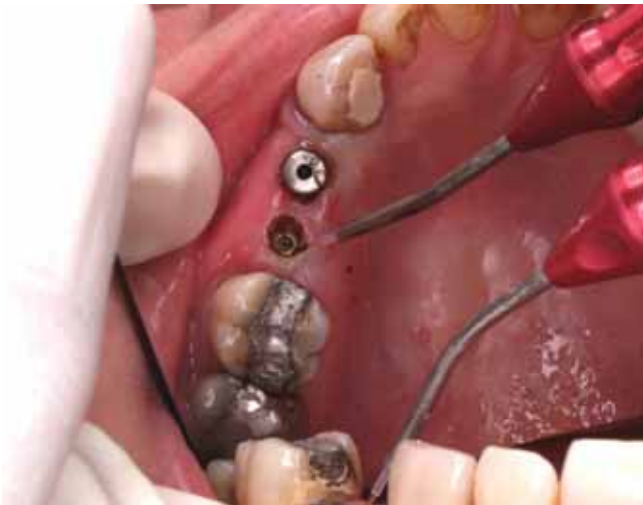

Figure 11: Use of the diode laser in implant recovery procedures.

photosensitise bacterial cells such as *E faecalis*. These cells then selectively absorb laser light at 635nm and are ablated (Lee, Bird et al, 2004) (see Figures 8 and 9). Such a technique has the potential to resolve persistent infections where conventional approaches have failed.

Diode laser light is applied usually with a 200-micron fibre, which is the same width as a 20K file. To irradiate to within a few millimetres of the apex, the cladding of the optical fibre for the length of the working file may need to be removed in order to insert the optical fibre to depth. The fibre needs to be continually moved for approximately 30 seconds to prevent carbonisation around the site of irradiation.

Death of gram negative bacteria leads to the release of endotoxin (lipopolysaccharide, LPS) from their cell walls which can egress through the apical foramen and is known to perpetuate the inflammatory process at the periapex, causing bone dissolution. For this reason the laser cannot completely replace good irrigation as the latter will be required to wash away LPS. Residual pulpal tissue will carbonise in the root canal with continued laser irradiation. Sodium hypochlorite is an

effective organic dissolvent and is needed to wash away irradiated pulpal content, which now may be carbonised.

ErCrYSGG and ErYAG laser technology has been used to carry out endodontic therapy from access, to disinfection to root canal preparation without supplemental anaesthesia. The lasing tips are long quartz-sapphire tips and have a limit to their flexibility. It is therefore not appropriate to prepare curved root canals with laser technology.

A further benefit to these lasers when they are preparing the root canal space is that they remove the smear layer. Endodontists attempt to remove this layer by final cleansing of the root canals with EDTA rinse for one to two minutes. The smear layer may provide an organic substrate for bacteria to grow on and reduce penetration of sealer and thermoplastic obturation methods into dentinal tubules.

Some published literature suggests that although laser technology results in much cleaner endodontic preparations with reduced smear layer compared to traditional methods, they cannot produce evenly tapering endodontic preparations and these can become ledged, zipped, overinstrumented and perforated even in straight canals (Ali, Hossain et al, 2005). It is the author's view that lasers have not yet reached the state of the art for endodontic preparation and until careful techniques and laser parameters have been clearly described for preparation, lasers should be used for disinfection, cleansing and smear layer removal in endodontics rather than root canal preparation.

### Periodontics

The disinfective properties of laser light make diode and NdYAG lasers invaluable in periodontics. As part of the surgical phase of periodontal therapy, an inverse bevel gingivectomy is often carried out to provide access to the root surface for debridement and to remove the pathologic sulcular epithelium. The epithelial ablation and space creation can be carried out more conservatively by application of a diode laser

to the periodontal sulcus, as illustrated by the schematic in Figure 10.

Adjunctive use of a diode laser with scaling and root planning procedures (SRP) is known to result in greater bacterial elimination than with SRP procedures alone, with preferential reduction of *Actinobacillus actinomycetemcomitans* in one particular study (Moritz, Gutknecht et al, 1997). This success implies that periodontal therapy can become less invasive, reducing the need for flap techniques.

### **Implantology**

For implant recovery procedures, traditionally a scalpel is used to create an 'H' shaped incision over the implant head prior to placing a healing collar. The periodontium is then left to heal for several weeks prior to impression procedures due to the possibility of gingival remodelling. A diode laser can be used at second stage surgery instead of a scalpel. The laser cuts precisely and effects haemostasis and seems to minimise pain and swelling. Many laser dentists report that gingival contours seem to be stable after implant recovery procedures (Figure 11), as long as gentle parameters were used to the extent that impression procedures can be carried out immediately (Passes, Furman et al, 1995).

### **Conclusion**

This article has presented a very cursory examination of dental lasers. As their uptake increases in practices in the future, clinicians will be reporting on their many virtues and the author believes they will achieve their rightful place alongside the turbine in many dental practices.

### **References**

- Ali MN, Hossain M et al (2005) Efficacy of root canal preparation by Er,Cr:YSGG laser irradiation with crown-down technique in vitro. *Photomed Laser Surg* 23(2): 196-201
- Anderson JR, Ellis RW, Blankenau RJ, Beiraghi SM, Westerman GH. Caries resistance in enamel by laser irradiation and topical fluoride treatment. *J Clin Laser Med Surg*. 2000 Feb;18(1):33-6.
- Basbaum AI, Fields HL (1984) Endogenous pain control systems: brainstem spinal pathways and endorphin circuitry. *Annu Rev Neurosci*; 7: 309-38

Brosh T, Pilo R, Bichacho N, Blutstein R. Effect of combinations of surface treatments and bonding agents on the bond strength of repaired composites. *J Prosthet Dent*. 1997 Feb;77(2):122-6.

Cobb CM (1997) Lasers in periodontics: use and abuse. *Compend Contin Educ Dent* 18(9): 847-52, 854-5, 858-9, quiz 860

*Dentistry* (1991) Periodontists raise concerns about inappropriate dental laser use. *Dentistry* 11(3):19

DeShields K (1995) Dentistry for the 21st century: laser technology. *Nda J* 46(2): 12-4

Distel JW, Hatton JF et al (2002) Biofilm formation in medicated root canals. *J Endod* 28(10): 689-93

Donadio-Moura J, Gouw-Soares S, de Freitas PM, Navarro RS, Powell LG, Eduardo Cde P. Tensile bond strength of a flowable composite resin to ER:YAG-laser-treated dentin. *Lasers Surg Med*. 2005 Jun;36(5):351-5.

Fox JL, Yu D, Otsuka M, Higuchi WI, Wong J, Powell GL. Abstract Initial dissolution rate studies on dental enamel after CO2 laser irradiation. *J Dent Res*. 1992 Jul;71(7):1389-98.

Gutknecht N, Franzen R et al (2004) Bactericidal effect of a 980-nm diode laser in the root canal wall dentin of bovine teeth. *J Clin Laser Med Surg* 22(1): 9-13

Harazaki M, Hayakawa K, Fukui T, Isshiki Y, Powell LG. The Nd:YAG laser is useful in prevention of dental caries during orthodontic treatment. *Bull Tokyo Dent Coll*. 2001 May;42(2):79-86.

Keller U R, Hibst et al (1998) Erbium:YAG laser application in caries therapy. Evaluation of patient perception and acceptance. *J Dent*; 26(8): 649-56

Kobayashi CA, Fujishima A, Miyazaki T, Kimura Y, Matsumoto K, Osada T, Fukunaga H, Kawawa T. Effect of Nd:YAG laser irradiation on shear bond strength of glass-ionomer luting cement to dentin surface. *Int J Prosthodont*. 2003 Sep-Oct;16(5):493-8.

Lee MT, Bird PS et al (2004) Photo-activated disinfection of the root canal: a new role for lasers in endodontics. *Aust Endod J* 30(3): 93-8

Lima KC, Fava LR et al (2001) Susceptibilities of *Enterococcus faecalis* biofilms to some antimicrobial medications. *J Endod* 27(10): 616-9

Matsumoto K, Nakamura Y, et al (1996) Clinical dental

application of Er:YAG laser for Class V cavity preparation. *J Clin Laser Med Surg*; 14(3):123-7

Melzack R and Wall D (1965) Pain mechanisms: a new theory. *Science*; 150(699): 971-9

Moritz A, Gutknecht N et al (1997) Bacterial reduction in periodontal pockets through irradiation with a diode laser: a pilot study. *J Clin Laser Med Surg* 15(1): 33-7

Obeidi A, Ghasemi A, Azima A, Ansari G. Effects of pulsed Nd:YAG laser on microleakage of composite restorations in class V cavities. *Photomed Laser Surg*. 2005 Feb;23(1):56-9.

Passes H, Furman M et al (1995). A case study of lasers in cosmetic dentistry. *Curr Opin Cosmet Dent*: 92-9 Perin FM, Franca SC et al (2004) Evaluation of the antimicrobial effect of Er:YAG laser irradiation versus 1% sodium hypochlorite irrigation for root canal disinfection. *Aust Endod J* 30(1): 20-2

Pinheiro ET, Gomes BP et al (2003) Evaluation of root canal microorganisms isolated from teeth with endodontic failure and their antimicrobial susceptibility. *Oral Microbiol Immunol* 18(2): 100-3

Podbielski A, Spahr A et al (2003) Additive antimicrobial activity of calcium hydroxide and chlorhexidine on common endodontic bacterial pathogens. *J Endod* 29(5): 340-5

Ramos RP, Chinelatti MA, Chimello DT, Borsatto MC, Pecora JD, Palma-Dibb RG. Bonding of self-etching and total-etch systems to Er:YAG laser-irradiated dentin. Tensile bond strength and scanning electron microscopy. *Braz Dent J*. 2004;15 Spec No:SI9-20.

Schwarz F, Arweiler N, Georg T, Reich E. Desensitizing effects of an Er:YAG laser on hypersensitive dentine. *J Clin Periodontol*. 2002 Mar;29(3):211-5.

Sulieman M (2005) An overview of the use of lasers in general dental practice: 1. Laser physics and tissue interactions. *Dent Update* 32(4): 228-30, 233-4, 236a

Trajtenberg CP, Pereira PN, Powers JM. Resin bond strength and micromorphology of human teeth prepared with an Erbium:YAG laser. *Am J Dent*. 2004 Oct;17(5):331-6

Van Meerbeek B, De Munck J, Mattar D, Van Landuyt K, Lambrechts P. Microtensile bond strengths of an etch&rinse and self-etch adhesive to enamel and dentin as a function of surface treatment. *Oper Dent*. 2003 Sep-Oct;28(5):647-60

Weiner, G P (2004) Laser dentistry practice management. *Dent Clin North Am* 48(4): 1105-26, ix