

# CBCT within endodontics: an introduction

Navid Saberi<sup>1</sup>

Since their discovery in 1895 and first application in dentistry in the same year, X-rays have been an invaluable aid in the practise of dentistry (Cruse, Bellizzi, 1980). Clinicians still depend greatly on dental radiography for obtaining diagnostic information, including the field of endodontics and in relation to the diagnosis of periradicular disease (PRD).

One major shortcoming of classic dental radiography, however, is a two-dimensional reproduction of a three-dimensional entity (Patel et al, 2009a). In medicine, this problem was overcome in 1972 by the invention of computed tomography (CT) (Beckmann, 2006). However, due to high radiation exposure, the use of CT imaging in dentistry could not be justified (Patel et al, 2009a). This dilemma has been addressed by the introduction of three-dimensional cone beam computed tomography (CBCT). Since the late 1990s, CBCT has been given serious

consideration within maxillofacial diagnostic radiology (Patel, 2009; Farman et al, 1997).

## CBCT versus conventional CT

Cone beam computed tomography (CBCT), which is also referred to as cone beam volumetric imaging (CBVI) and cone beam volumetric tomography (CBVT), is an extraoral radiographic method of producing three-dimensional digital radiographic information (Patel et al, 2009a; Patel, 2009; Miles, 2008; McNamara, Kapila, 2006; Horner, Drage, Brettle, 2008; Patel et al, 2007).

In conventional CT scanning machines, the X-ray source and detector rotate 360° around the patient at around the rate of 60 times per minute, with a thin fan-shaped beam of X-rays directed through the patient. The thickness of each image slice is determined by the distance the patient is moved through the inside of the CT scanning machine during this synchronised rotation. This creates multiple sectional images that are then processed by a computer to create a three-dimensional image of the patient's region of interest (Beckmann, 2006, Miles, 2008; Horner, Drage, Brettle, 2008; Patel et al, 2007).

In cone beam CT scanning devices, unlike conventional CT, a narrow cone-shaped beam, as opposed to a fan-shaped beam, rotates between 180 to 360 degrees

<sup>1</sup> Navid Saberi BDS(Manch) MFDSRCS(Ed) MSc(Distinction)(Glas)

Navid Saberi maintains a practice limited to endodontics in Brighton and London. He is also honorary secretary of Scottish Endodontic Study Group. He can be contacted at [info@root999.co.uk](mailto:info@root999.co.uk) or [info@elmslea.com](mailto:info@elmslea.com). For more information about the study club, please visit [www.sesg.org.uk](http://www.sesg.org.uk).

**Table 1: CBCT versus conventional CT – advantages and disadvantages**

	CBCT	Conventional CT
<b>Advantages</b>	<ul style="list-style-type: none"> <li>• Provides accurate cross-sectional information</li> <li>• Short scanning time</li> <li>• No superimposed tomographic blurring</li> <li>• Multiplanar views and 3D reconstruction possible</li> <li>• Uniform magnification</li> <li>• Not technically demanding to perform</li> <li>• Lower dose than conventional CT</li> <li>• PC based software</li> </ul>	<ul style="list-style-type: none"> <li>• Provides accurate cross-sectional information</li> <li>• Short scanning time</li> <li>• No superimposed tomographic blurring</li> <li>• Multiplanar views and 3D reconstruction possible</li> <li>• Uniform magnification</li> <li>• Bone density measurements possible</li> <li>• Soft tissue assessment possible</li> </ul>
<b>Disadvantages</b>	<ul style="list-style-type: none"> <li>• Imaging of entire jaw rather than site of interest in the majority of scanners</li> <li>• Relatively expensive</li> <li>• Amalgam and metallic restorations can cause artefacts</li> <li>• Limited bone density information provided</li> <li>• Not suitable for soft tissue assessment</li> </ul>	<ul style="list-style-type: none"> <li>• Imaging of entire jaw rather than the site of interest</li> <li>• High dose</li> <li>• Amalgam and metallic restorations can cause artefacts</li> <li>• Limited availability</li> <li>• Very expensive</li> </ul>

(depending on the model) around the patient's region of interest, capturing a volume of the patient, as opposed to a slice in conventional CT scanners.

Cone beam CT also allows the desired image to be produced in a single rotation without the need for moving the scanner or the patient (Figure 1) (Patel et al, 2009a; Patel, 2009; Miles, 2008; Horner, Drage, Brettle, 2008; Patel et al, 2007; Patel, Kanagasingam, Mannocci, 2010; Cotti, 2010; Scarfe, Farman, 2008). The X-ray field can be collimated to include the region of interest only. This quick cone beam production and volumetric image capturing is capable of reducing the exposure by more than 50 times in some cases (Patel, 2009; Miles, 2008; McNamara, Kapila, 2006; Horner, Drage, Brettle, 2008; Patel et al, 2007; Patel, Kanagasingam, Mannocci, 2010; Cotti, 2010; Scarfe, Farman, 2008).

CBCT is capable of producing high contrast images with good resolution in a short period of time. However, soft

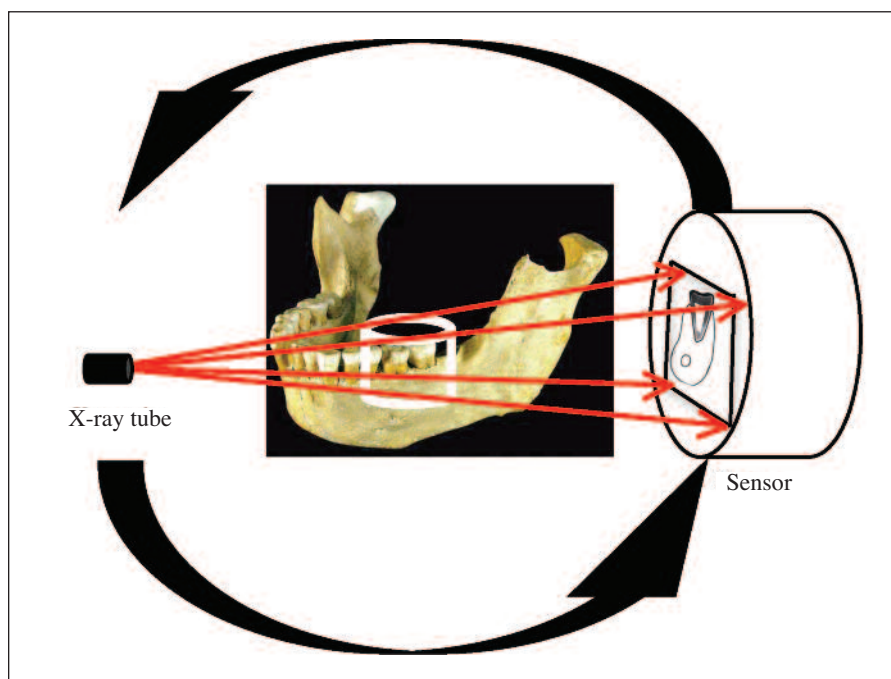
tissue contrast is relatively poor in these devices (Horner, Drage, Brettle, 2008; Patel, Kanagasingam, Mannocci, 2010; Scarfe, Farman, 2008).

As explained earlier, the effective dose of CBCT is much less than that for conventional CT, although the dose is dependent on the volume of tissue irradiated, and also the other imaging parameters that are selected (Horner, Drage, Brettle, 2008; Patel et al, 2007; Scarfe, Farman, 2008). CBCT scanners are also significantly cheaper than conventional CT scanners. A full list of advantages and disadvantages of CBCT and conventional CT can be found in Table 1.

#### **Pixel versus voxel**

A pixel is a two-dimensional picture element that is a square that measures between 20 and 60 micrometres in size (Miles, 2008; McNamara, Kapila, 2006).

A voxel, on the other hand, is a three-dimensional volume



**Figure 1:** Diagram showing the basic concept of CBCT. CBCT scanner uses a cone beam source to acquire the entire area of interest.

element and is a cube, which may or may not be isometric (Patel, 2009; Miles, 2008; McNamara, Kapila, 2006). This is the building block of the volume of the image that has been captured by cone beam CT and then processed and digitised by computer software (Figure 2).

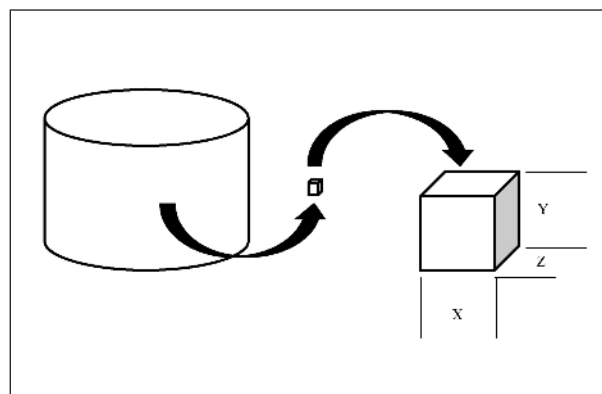
The computer software also allows viewing of the image volumes and further image management, manipulation and interactions (Patel, 2009; Miles, 2008; McNamara, Kapila, 2006; Patel et al, 2007; Patel, Kanagasigam, Mannocci, 2010).

**Sensors**

The type of sensor determines important image volume characteristics such as the size, shape, and spatial resolution of the reconstructed volume (Patel, 2009; Miles, 2008; McNamara, Kapila, 2006; Patel et al, 2007; Patel, Kanagasigam, Mannocci, 2010; Scarfe, Farman, 2008).

The sensor options include an image intensifier that is coupled to either a charged coupled device (CCD) or complementary metal oxide semiconductor (CMOS), a CCD chip or a thin film transistor (TFT) flat panel type of image receptor (Miles, 2008; McNamara, Kapila, 2006; Scarfe, Farman, 2008).

One of the most important sensor characteristics, which determines the diagnostic superiority of the CBCT machine,



**Figure 2:** The concept of a voxel. The volume of image in CBCT is composed of voxels, which can be as small as 0.08mm

is the signal to noise or signal to glare ratio. This ratio varies between sensors. CCD and flat panel sensors have higher (better) signal to noise ratio than image intensifier systems. This leads to improved diagnostic accuracy when faced with scatter, which is produced by metallic elements and prostheses within the maxillofacial skeleton and teeth.

The smaller and more compact size of CCD and flat panel sensors also reduces the overall weight and size of the CBCT unit and make them more ergonomic. However, the

compact CCD sensors produce smaller reconstructed image volumes and therefore a smaller anatomic field of view when compared to flat panel and image intensifier sensors. Thereby, they are not suitable for full arch and full maxillofacial skeletal image reconstruction (Patel, 2009; McNamara, Kapila, 2006; Patel et al, 2007; Scarfe, Farman, 2008).

Overall, the image intensifier is an older technology and produces a lower quality of image. The flat panel detectors and CCD sensors are the newest image receptors. These offer less image distortion, wider contrast scale and glare elimination when compared with the image intensifier receptors (McNamara, Kapila, 2006; Patel et al, 2007; Scarfe, Farman, 2008).

### Quality of reconstructed data

The quality of reconstructed image formats and data is related primarily to the voxel size, signal to noise ratio, and contrast or dynamic range.

Most units these days produce a dynamic range up to 65536 shades of grey (16 bits). The voxel size ranges from 0.08 to 0.6mm. Voxel size is inversely proportional to improved anatomic feature detection. In image intensifier sensors, the reduction of voxel size can only be achieved by reducing the field of view. However, due to low (poor) signal to noise ratio in these units, the quality of the reconstructed image cannot be as high quality as CCD and flat panel units. Conversely, flat panel sensors can create a small voxel size for any given field of view (Miles, 2008; McNamara, Kapila, 2006; Patel et al, 2007; Scarfe, Farman, 2008).

The image data in image intensifier CBCT units can be up to 1.5 gigabytes per scan when using a large field of view. Whereas the size of the image data in flat panel CBCT units can be up to 400 megabytes and in CCD CBCT scanners can reach 100 megabytes. Thus, storage, back-up, and transfer of data in CCD and flat panel CBCT scanners are also easier than in image intensifier CBCT scanners. However, all units require high local and/or regional data transfer network speed and capacity (McNamara, Kapila, 2006; Scarfe, Farman, 2008).

### Clinical applications of cone beam CT scanning

Advances in CBCT imaging means these scanners can reconstruct three-dimensional images that can be used for maxillofacial surgical treatment planning, assessing impacted teeth prior to surgical extractions, temporomandibular joint analysis, orthodontics, airway assessment, periodontics, bone level evaluation, implantology, endodontic assessment, diagnosis and treatment planning.

### Clinical applications of cone beam CT scanning within endodontics

Cone beam computed tomography (CBCT) has been established to be superior to conventional intraoral and extraoral radiography in diagnostic accuracy. CBCT is capable of producing high contrast images with good resolution in a short period of time.

In endodontics, this particularly relates to early diagnosis of periradicular disease with greater accuracy of lesion size, extent, nature and position (Stavropoulos, Wenzel, 2007; Paula-Silva et al, 2009a; Patel et al, 2009b; Estrela et al, 2008). Furthermore, three-dimensional volume of information captured by CBCT can also aid clinicians in the diagnosis of root fractures, root resorption, perforations, obturation voids and defects and root canal morphology (Naito, Hosokawa, Yokota, 1998; Tyndall, Rathore, 2008; Misch, Yi, Sarment, 2006; Patel, Horner, 2009; Cotton et al, 2007; Pinsky et al, 2006; Hassan et al, 2009; Huybrechts et al, 2009).

Most CBCT studies have either been performed *ex vivo* on cadavers or on animals. Conclusions drawn from these studies should be carefully analysed as laboratory tests methodologies may not reflect the clinical situation. Furthermore, methods used by authors in CBCT studies should also be critically evaluated in terms of CBCT scanner settings. This is particularly important when two or more machines are being compared as different settings will inherently change the quality of reconstructed three-dimensional images. Unfortunately, this important information is not always provided by the authors. Nevertheless, almost all CBCT studies have shown overwhelming superiority of these imaging machines over conventional radiography (Table 2).

Another benefit of CBCT is its use in evaluation of periradicular healing and endodontic outcome assessment. Paula-Silva et al (2009b) clearly demonstrated that traditional intraoral radiographic evaluation of periradicular healing is an unsuitable and unreliable method for this purpose. In contrast, CBCT provides acceptable diagnostic information in relation to periradicular repair. However, histological analysis of the root periapex remains the gold standard.

In another study, Christiansen et al (2009) confirmed that, on average, periapical bone defects measured on periapical radiographs are approximately 10% smaller than on CBCT images. This is a very important finding and may influence decision making and guidelines regarding conventional radiographic outcome assessment.

Current ESE guidelines (2006) state that root canal treatment has an uncertain or an unfavourable outcome if:

**Table 2: Recent CBCT studies have shown overwhelming superiority of these imaging machines over conventional radiography**

Author / publication	Design	CBCT	Sample	Objective	Results/conclusion
Lofthang-Hansen et al (2007) <i>Oral Surgery, Oral Medicine, Oral Pathology, Oral Radiology and Endodontology</i>	Retrospective	3D Accuitomo	46 teeth in 36 patients	CBCT vs. PA for PRD diagnosis	70% more information and 20% more accuracy on CBCT
Estrela et al (2008) <i>Journal of Endodontics</i>	Retrospective	Veraviewepocs	888 images (1508 teeth)	Accuracy of CBCT, panoramic and PA for PRD	Higher detection of PRD in CBCT cases
Simon et al (2006) <i>Journal of Endodontics</i>	Cross sectional	Newtom 3G	17 large PRD cases	Granuloma vs. cyst differentiation	CBCT reliable in diagnosing cysts and granuloma
Patel et al (2009) <i>International Endodontic Journal</i>	Ex vivo trial	Veraviewepocs	Six roots	Accuracy of CBCT in detecting PRD	CBCT sensitivity was 75.2% higher than PA
Sogur et al (2009) <i>Dentomaxillofacial Radiology</i>	Ex vivo trial	Accuitomo	12 mandibles	CBCT vs. digital vs. PA in detecting PRD	CBCT had higher sensitivity and specificity
Özen et al (2009) <i>Oral Surgery, Oral Medicine, Oral Pathology, Oral Radiology and Endodontology</i>	Ex vivo trial	i-Cat / Iluma	27 roots	CBCT vs. digital vs. PA in detecting PRD	CBCT performed better than digital and conventional PAs
Kamburo lu et al (2010) <i>Dentomaxillofacial Radiology</i>	Ex vivo trial	Newtom 3G	18 teeth	CBCT accuracy in detecting PRD	Highly accurate results in CBCT cases
Stavropoulos et al (2007) <i>Clinical Oral Investigation</i>	Animal ex vivo trial	Newtom 3G	10 pig mandibles	CBCT vs. digital vs. PA accuracy	CBCT was more than 20% more accurate
Paula-Silva et al (2009a) <i>Journal of Endodontics</i>	Animal trial	Newtom	96 roots in dogs	Outcome of RCT by PA and CBCT	CBCT was more accurate (by 44%)
Paula-Silva et al (2009b) <i>Journal of Endodontics</i>	Animal trial	Newtom	83 roots in dogs	Accuracy of Pa and CBCT in detecting PRD	CBCT was more accurate (by 13%)
Bernardes et al (2009) <i>Oral Surgery, Oral Medicine, Oral Pathology, Oral Radiology and Endodontology</i>	Cross sectional	Accuitomo 3DX	20 patients	CBCT vs. PA for the diagnosis of root #	CBCT was more accurate in detecting vertical root #
Hassan et al (2009) <i>Journal of Endodontics</i>	Ex vivo trial	i-Cat	80 teeth	Detection of artificial root #	CBCT 20% more accurate than PA
Wenzel et al (2009) <i>Oral Surgery, Oral Medicine, Oral Pathology, Oral Radiology and Endodontology</i>	Ex vivo trial	i-Cat	69 teeth	Detection of transverse root #	CBCT with 0.125 voxel resolution was more accurate than 0.25 voxel or PSP system
Hassan et al (2010) <i>Journal of Endodontics</i>	Ex vivo trial	Five scanners	80 teeth	Detection of root # by different CBCT scanners	i-Cat was the most accurate
Kamburo lu et al (2010) <i>Oral Surgery, Oral Medicine, Oral Pathology, Oral Radiology and Endodontology</i>	Ex vivo trial	Newtom 3G/ Iluma	60 teeth	Accuracy of CBCT (different voxels) and PA in detecting root #	Higher detection of PRD in CBCT cases
Özer (2010) <i>Journal of Endodontics</i>	Ex vivo trial	i-Cat	80 teeth	Detection of root # with different thickness by CBCT and PA	CBCT was determined to be more accurate than PA
Patel and Dawood (2007) <i>International Endodontic Journal</i>	Case report	i-Cat	Two teeth	Diagnosis of external cervical resorption	Sound diagnosis can be made using CBCT
Dudic et al (2009) <i>American Journal of Orthodontics and Dentofacial Orthopaedics</i>	Cross sectional	3D Accuitomo	275 teeth	CBCT vs. OPG in detecting apical root resorption	CBCT was established to be superior to OPG
Estrela et al (2009) <i>Journal of Endodontics</i>	Cross sectional	i-Cat	40 patients (48 scans)	CBCT vs. PA in detecting root resorption	CBCT was 30% more accurate than PA
Liedke et al (2009) <i>Journal of Endodontics</i>	Ex vivo trial	i-Cat	60 teeth	Evaluation of different voxel sizes of CBCT in detecting resorption	CBCT was determined to perform well specially with 0.3mm voxel size
Durack et al (2011) <i>International Endodontic Journal</i>	Ex vivo trial	3D Accuitomo 80	10 teeth	Diagnostic accuracy of CBCT and PA for the detection of external resorption	CBCT performed much better than PA
La et al (2010) <i>Journal of Endodontics</i>	Case report	Implagraphy	One tooth	The use of CBCT in canal identification	Mid mesial canal in a mandibular first molar was identified using CBCT
Moura et al (2009) <i>Journal of Endodontics</i>	Cross sectional	3D Accuitomo	503 obturations	Influence of obturation length on PRD	CBCT performed better than PA in the detection of PRD and checking obturation length
Mathere et al (2008) <i>Journal of Endodontics</i>	Ex vivo trial	i-Cat	72 images	CBCT vs. CCD vs. PSP in diagnosing root canals	CBCT performed significantly better than intraoral radiography
Michetti et al (2010) <i>Journal of Endodontics</i>	Ex vivo trial	Kodak 9000 3D	Nine teeth	Accuracy of CBCT in root canal image reconstruction	CBCT images were similar to real histologic section
Neelakantan et al (2010) <i>Journal of Endodontics</i>	Ex vivo trial	3D Accuitomo	95 teeth	Accuracy of CBCT in identifying root canals	CBCT was accurate and similar to staining and clearing technique
Huybrechts et al (2009) <i>International Endodontic Journal</i>	Ex vivo trial	Accuitomo	Two teeth	CBCT vs. digital vs. PA in void detection	Digital radiographs performed better than CBCT and PA in detecting small voids
D'Addazio et al (2011) <i>International Endodontic Journal</i>	Ex vivo trial	i-Cat	16 teeth in three mandibles	CBCT vs. PA in diagnosing simulated endodontic complications	Overall CBCT was determined to be superior to PA
Sanfelice et al (2010) <i>Journal of Endodontics</i>	Ex vivo trial	i-Cat	32 extracted lower first molars	Canal enlargement monitoring using CBCT	Significant differences could be identified pre vs. post instrumentation using CBCT

- Radiographs reveal that a lesion has remained the same size or has only diminished in size
- A radiologically visible lesion has appeared subsequent to treatment or a pre-existing lesion has increased in size.

However, the guideline fails to clarify what constitutes an acceptable radiographic assessment. Now that better diagnostic equipment has become available with CBCT, potentially more cases could be classified as unsuccessful in

the future. This is particularly important in endodontic diagnostic radiology and the use of CBCT imaging in outcome assessment of endodontic treatment.

In comparison, success and failure assessment criteria for a different treatment modality to endodontic treatment, namely dental implant placement, are generally less strict. The differences between these criteria render the two treatment modalities incomparable. Furthermore, success measures for dental implant longevity and survival have misleadingly led to the common belief that dental implant placement is more successful than endodontic therapy. This belief could negatively influence patient decision making regarding the appropriate treatment. Therefore, radiographic outcome assessment in endodontics should be interpreted with caution (Friedman, Abitbol, Lawrence, 2003) to assist patients and clinicians to make an informed decision in relation to endodontic or dental implant treatment planning.

Wu et al (2009) argued that a reduced periapical radiolucency on radiographs does not guarantee that the healing process has begun or is continuing. The authors reported that a high percentage of cases that were confirmed healthy from periapical radiography presented with apical periodontitis in CBCT images.

It was recommended that the outcomes of root canal treatment should be re-evaluated in long-term longitudinal studies using CBCT and stricter than normal evaluation criteria. Furthermore, the authors recommended replacement of periapical radiography with CBCT in dental clinics because of the misleading results obtained from periapical radiography.

This argument and debate raises a very crucial question – what constitutes endodontic success?

### **Defining endodontic success**

The aim of root canal treatment has been to treat periradicular disease. Therefore, the success of root canal treatment will only be achieved by complete resolution of the apical lesion (Ørstavik, Pitt Ford, 2008). However, how should success be assessed?

The gold standard assessment is by means of histological analysis of the root periapex (Simon et al, 2006; Paula-Silva et al, 2009c). However, performing histological analysis of the apex of every asymptomatic root canal treated tooth is unjustifiable, unrealistic and difficult to perform. Furthermore, it may cause considerable morbidity and therefore unethical to carry out.

As explained earlier, success assessment can also be achieved by radiographic monitoring of the lesion. But we now know that conventional radiography is not a reliable method for this assessment. CBCT is shown to be a more

accurate diagnostic tool. However, even CBCT is not 100% accurate in the diagnosis of periapical lesions (D'Addazio et al, 2011). Unfortunately, those authorities that recommend routine assessment of endodontically treated teeth with CBCT fail to mention this fact.

So, what is important for clinicians? Consideration should be given to patient-centred outcomes, including patient satisfaction and improved quality of life after root canal treatment as opposed to a paternalistic look at intervention and treatment outcome. If we think CBCT is better than periapical radiography and routine overexposing of patients to radiation is justifiable, why not perform apical surgery in order to obtain a biopsy of every single PRD lesion to establish resolution? After all, histological examination is the proven gold standard and even CBCT cannot match its accuracy. Where do we stop?

Dugas et al (2002) conducted an interesting study looking at the quality of life and satisfaction outcomes of endodontic treatment. The authors interviewed individuals with known root canal treated teeth, asking them to complete a questionnaire. This questionnaire was an endodontically-adapted quality of life instrument consisting of 17 questions. Of the cohort, 97.1% reported satisfaction with decision to have endodontic treatment. Surprisingly, 96.4% individuals were found to have PRD associated with the root canal treated teeth. The use of quality of life instruments and dental satisfaction scales in order to contemporise endodontic assessment was recommended. The authors concluded that further development of endodontic-specific quality of life and satisfaction instruments that measure the impact of endodontic disease and treatment on patients' wellbeing should take place. This new way of treatment evaluation will help put patient-based outcomes at the centre of endodontic treatment assessment.

This definition of success could also be revised. Clinical endodontic outcomes should be more patient focused and concentrate more on the elimination of the clinical signs and symptoms of periradicular disease. Indeed, even periradicular disease may not always be the primary factor in determining the outcome of root canal treatment. Moreover, the term success should perhaps be replaced by the term survival or functionality. This is especially important when direct comparison between endodontics and dental implant survival rates is being made. Furthermore, this will reduce patients being confused and misled over often reported higher survival rates of implants.

### **Conclusion**

CBCT has been established to be superior to conventional intraoral and panoramic radiography in its accuracy and

sensitivity in detecting endodontic related pathology.

The use of CBCT significantly enhances the clinician's ability to diagnose PRD and other endodontic complications, particularly when compared with conventional intraoral radiography. Therefore, more endodontic disease may be detected in the future. However, strict selection criteria for CBCT use must be followed and routine CBCT examination of patients should be avoided. This will reduce unnecessary patient exposure to radiation, especially when the question for which radiographic exposure is required can often be answered by lower dose conventional intraoral radiography.

In addition, routine post root canal treatment radiographic follow-up by means of CBCT in patients without clinical signs or symptoms of endodontic disease is not recommended.

*Reprinted with permission by  
ENDODONTIC PRACTICE February 2013*

## References

- Beckmann EC (2006) CT scanning the early days. *British Journal of Radiology* 79: 5-8
- Christiansen R, Kirkevang LL, Gotfredsen E, Wenzel A (2009) Periapical radiography and cone beam computed tomography for assessment of the periapical bone defect 1 week and 12 months after root-end resection. *Dentomaxillofacial Radiology* 38: 531-536
- Cotti E (2010) Advanced techniques for detecting lesions in bone. *The Dental Clinics of North America* 54: 215-235
- Cotton TP, Geisler TM, Holden DT, Schwartz SA, Schindler WG (2007) Endodontic applications of cone-beam volumetric tomography. *Journal of Endodontics* 33: 1121-1132
- Cruse W P, Bellizzi R (1980) A historic review of endodontics, 1689-1963, part 2. *Journal of Endodontics* 6: 532-535
- D'Addazio PSS, Campos CN, Özcan M, Teixeira HGC, Passoni RM, Carvalho ACP (2011) A comparative study between cone-beam computed tomography and periapical radiographs in the diagnosis of simulated endodontic complications. *International Endodontic Journal* 44: 218-224
- Dugas NN, Lawrence HP, Teplitsky P, Friedman S (2002) Quality of life and satisfaction outcomes of endodontic treatment. *Journal of Endodontics* 28: 819-827
- Estrela C, Bueno MR, Leles CR, Azevedo B, Azevedo JR (2008) Accuracy of cone beam computed tomography and panoramic and periapical radiography for detection of apical periodontitis. *Journal of Endodontics* 34: 273-279
- European Society of Endodontology (2006) Quality guidelines for endodontic treatment: consensus report of the European Society of Endodontology. *International Endodontic Journal* 39: 921-930
- Farman AG, Ruprecht A, Gibbs SJ, Scarfe WC (1997) *Advances in maxillofacial imaging*. 1st ed. Amsterdam: Elsevier
- Friedman S, Abitbol S, Lawrence HP (2003) Treatment outcome in endodontics: the Toronto study: phase 1: initial treatment. *Journal of Endodontics* 29: 787-793
- Hassan B, Metska ME, Ozok AR, van der Stelt P, Wesselink PR (2009) Detection of vertical fractures in endodontically treated teeth by a cone beam computed tomography scan. *Journal of Endodontics* 35: 719-722
- Horner K, Drage N, Brettell D (2008) *21st century imaging*. 1st ed. London: Quintessence Publishing Co Inc
- Huybrechts B, Bud M, Bergmans L, Lambrechts P, Jacobs R (2009) Void detection in root fillings using intraoral analogue, intraoral digital and cone beam CT images. *International Endodontic Journal* 42: 675-685
- McNamara JA, Kapila SD (2006) *Digital radiography and three-dimensional imaging*. 1st ed. Ann Arbor: The University of Michigan
- Miles DA (2008) *Colour atlas of cone beam volumetric imaging for dental applications*. 1st ed. Chicago: Quintessence Publishing Co Inc
- Misch KA, Yi ES, Sarment DP (2006) Accuracy of cone beam computed tomography for periodontal defect measurements. *Journal of Periodontology* 77: 1261-1266
- Naito T, Hosokawa R, Yokota M (1998) Three-dimensional alveolar bone morphology analysis using computed tomography. *Journal of Periodontology* 69: 584-589
- Ørstavik D, Pitt Ford T (2008) *Essential endodontology*. 2nd ed. Oxford: Blackwell Munksgaard
- Patel S (2009) New dimensions in endodontic imaging: part 2. Cone beam computed tomography. *International Endodontic Journal* 42: 463-475
- Patel S, Dawood A, Pitt Ford T, Whaites E (2007) The potential applications of cone beam computed tomography in the management of endodontic problems. *International Endodontic Journal* 40: 818-830
- Patel S, Dawood A, Whaites E, Pitt Ford T (2009a) New dimensions in endodontic imaging: part 1. Conventional and alternative radiographic systems. *International Endodontic Journal* 42: 447-462
- Patel S, Dawood A, Mannocci F, Wilson R, Pitt Ford T (2009b) Detection of periapical bone defects in human jaws using cone beam computed tomography and intraoral radiography. *International Endodontic Journal* 42: 507-515
- Patel S, Horner K (2009) The use of cone beam computed tomography in endodontics. *International Endodontic Journal* 42: 755-756
- Patel S, Kanagasigam S, Mannocci F (2010) Cone beam computed tomography (CBCT) in endodontics. *Dental Update* 37: 373-379
- Paula-Silva FWG, Hassan B, Silva LAB, Leonardo MR, Wu M-K (2009a) Outcome of root canal treatment in dogs determined by periapical radiography and cone-beam computed tomography scans. *Journal of Endodontics* 35: 723-726
- Paula-Silva FWG, Júnior MS, Leonardo MR, Consolaro A, Silva LAB (2009b) Cone-beam computerized tomographic, radiographic, and histologic evaluation of periapical repair in dogs' post-endodontic treatment. *Oral Surgery, Oral Medicine, Oral Pathology, Oral Radiology, and Endodontology* 108: 796-805
- Paula-Silva FWG, Wu MK, Leonardo MR, Silva LAB, Wesselink PR (2009c) Accuracy of periapical radiography and cone-beam computed tomography scans in diagnosing apical periodontitis using histopathological findings as a gold standard. *Journal of Endodontics* 35: 1009-1012
- Pinsky HM, Dyda S, Pinsky RW, Misch KA, Sarment DP (2006) Accuracy of three-dimensional measurements using cone-beam CT. *Dentomaxillofacial Radiology* 35: 410-416
- Scarfe WC, Farman AG (2008) What is cone-beam CT and how does it work? *The Dental Clinics of North America* 52: 707-730
- Simon JHS, Enciso R, Malfaz JM, Roges R, Bailey-Perry M, Patel A (2006) Differential diagnosis of large periapical lesions using cone-beam computed tomography measurements and biopsy. *Journal of Endodontics* 32: 833-837
- Stavropoulos A, Wenzel A (2007) Accuracy of cone beam dental CT, intraoral digital and conventional film radiography for the detection of periapical lesions. An ex vivo study in pig jaws. *Clinical Oral Investigation* 11: 101-106
- Tyndall DA, Rathore S (2008) Cone-beam CT diagnostic applications: caries, periodontal bone assessment, and endodontic applications. *The Dental Clinics of North America* 52: 825-841
- Wu MK, Shemesh H, Wesselink PR (2009) Limitations of previously published systematic reviews evaluating the outcome of endodontic treatment. *International Endodontic Journal* 42: 656-666