

Aesthetic two stage crown lengthening for altered passive eruption: A 25-year case report and review

André W van Zyl¹ and Inus Snyman²

Introduction

Mucogingival abnormalities may involve lack of gingiva, excess gingiva, recession, shallow vestibule, abnormal colour and aberrant frenula (AAP Consensus 1999).^{1,2} Periodontal plastic surgery was a term introduced by Preston Miller in the early nineties to describe mucogingival or periodontal procedures dealing with aesthetics.³ It is of the utmost importance to understand that none of the conditions or procedures described in this article can be correctly diagnosed or treated until such time as all infection and inflammation have been resolved. There should be no gingivitis or periodontitis present.

Periodontists are often requested to correct an excessive gingival display or correct excessive exposure of teeth due to recession. Periodontal aesthetic surgery around natural teeth therefore involves either the removal of excess tissue in gummy smiles or the repair of lost tissue such as in recession. The former involves the procedure of crown lengthening or gingivectomy and the latter the treatment of marginal gingival recession by grafting. Crown lengthening is carried out either for aesthetic or functional purposes. Indications for crown lengthening include subgingival caries, crown or root fractures, altered passive eruption, short teeth, excessive gingival display, uneven gingival contours, cervical root resorption and short clinical abutment.⁴ This article will cover excessive gingival display (Altered Passive Eruption, APE) and the procedure of two stage crown lengthening only.

Crown lengthening (CL) may be achieved by either gingivectomy (removal of excess gingiva) or by removal of bone (osteotomy) and gingiva. It is essential to determine whether bone needs to be removed for lengthening. In the past this was done by doing bone sounding under local anaesthesia, which is a fairly invasive procedure. CBCT is now an alternative and not only can bone be assessed by this, but the soft tissue too, provided a soft tissue CBCT approach is used.⁵

CL is aimed at exposing more of the clinical crown of the tooth. There are various reasons why this may be desirable but for the purpose of this article we will focus on two of the main aesthetic reasons caused by APE:

1. A gummy smile where the teeth are not fully exposed and partly covered by gingiva (Figure 1)
2. An asymmetric gingival contour which is not aesthetic (Figure 2)

¹ André W van Zyl: BChD, MChD. Private Practice Periodontist, Hermanus & Honorary Professor, Department of Oral Medicine and Periodontics, Faculty of Health Sciences, University of Witwatersrand. ORCID Number: 0000-0002-7985-4054

² Inus Snyman: BChD, PDD (Implantology), PGDipDent (Oral Surgery), PGDipDent (Implantology). Department of Periodontics and Oral Medicine, School of Dentistry, Faculty of Health Sciences, University of Pretoria. ORCID Number: 0000-0002-8480-5361

Corresponding author:

André W van Zyl
Private Practice Periodontist,
Hermanus & Honorary Professor,
Department of Oral Medicine
and Periodontics, University of
Witwatersrand, South Africa.
Tel: +27(28) 3121510
E-mail: info@andrevanzyl.co.za

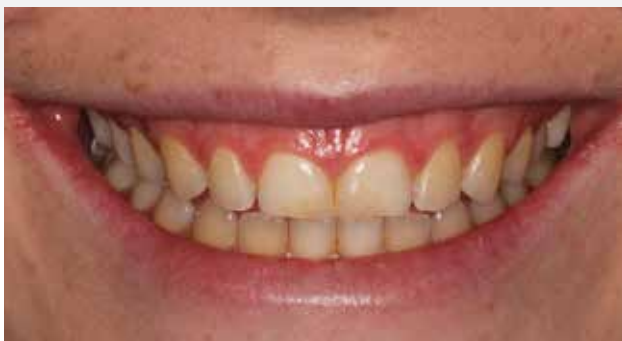

Figure 1: Gummy smile due to Altered Passive Eruption.

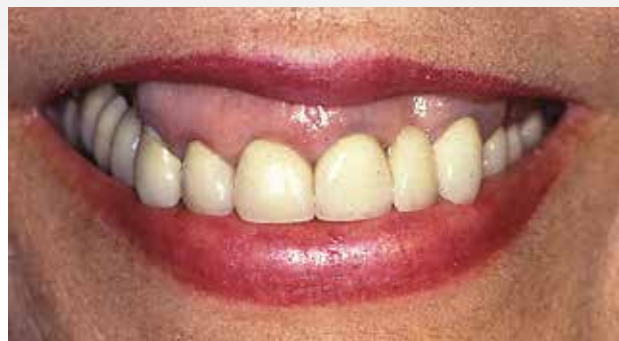

Figure 2: Asymmetric gingival contour.

It is important to be able to diagnose the underlying problem correctly before embarking on the procedure.

Altered Passive Eruption (APE)

It is important to note that excessive gingival display is not always due to APE, but may also be due to vertical maxillary excess, sometimes in combination with a high lip line (Figure 3).^{6,7}

In a South African study it was found that Delayed Passive Eruption had a prevalence of 12%.⁸ Excessive gingival display is most often diagnosed as APE, but it may also be seen in drug induced enlargement and in plaque induced swelling.⁶ Passive eruption is the process that occurs after the tooth erupts into the oral cavity (the active eruption phase) and is the process where the gingiva slowly migrates apically to expose the anatomical crown.⁶ APE occurs when the gingiva does not reach its correct position and covers part of the clinical crown, giving a gummy appearance.⁶ It is not clear exactly when the physiological movement of passive eruption ends and thus, at what age a diagnosis of APE can be made.⁶ Coslett et al. reported that by the age of 18 -20 years, the majority of individuals have a mature dentogingival relationship.⁹

Multiple factors have been proposed as possible causes for APE. These include occlusal interference by soft tissue during the eruption phase, the presence of thick fibrotic gingiva, genetics, the presence of thick bone, orthodontic trauma and endocrine conditions.¹⁰

APE can be classified into two types, based on the position of the mucogingival junction in relation to the cemento-enamel junction.⁹ Type 1 APE is characterised by the mucogingival junction being apical to the alveolar bone crest, usually with a wide band of attached gingiva.⁶ This band of attached gingiva is usually wider than the generally

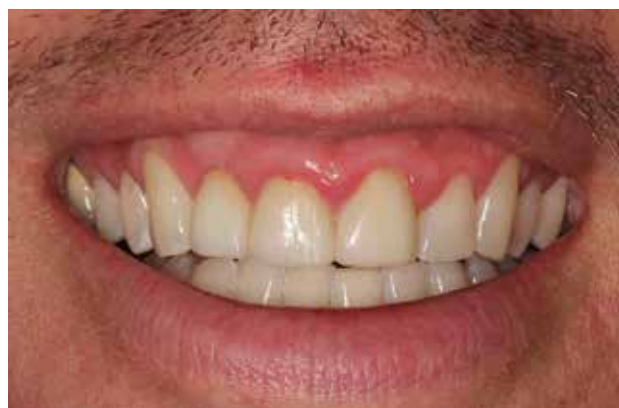

Figure 3: A gummy smile due to vertical maxillary excess where teeth are almost fully exposed.

accepted mean width of 3,0 - 4,2 mm in the maxilla and 2,5 - 2,6 mm in the mandible.⁶ In contrast, Type 2 APE is defined by the presence of a band of attached gingiva which falls within the normal mean width.⁶ In type 2 APE, the mucogingival junction is located at the level of the cemento-enamel junction, with the whole band of attached gingiva located on the anatomic crown.⁶ Both type 1 and type 2 APE, can further be subclassified into subgroup A or subgroup B.⁶ In subgroup A, the alveolar bone crest is located at the normal position, 1 – 3 mm apical to the cemento-enamel junction.⁶ Subgroup B refers to those cases where the alveolar bone crest is located at or coronal to the level of the cemento-enamel junction.⁶ Correct classification and diagnosis of each case is of critical importance before treatment commences. APE type 1 subgroup A may be treated with gingivectomy alone, whereas the authors recommend a two-stage crown lengthening approach for all other classifications.⁶ Whether the second stage surgery (gingivectomy) in a two-stage crown lengthening approach

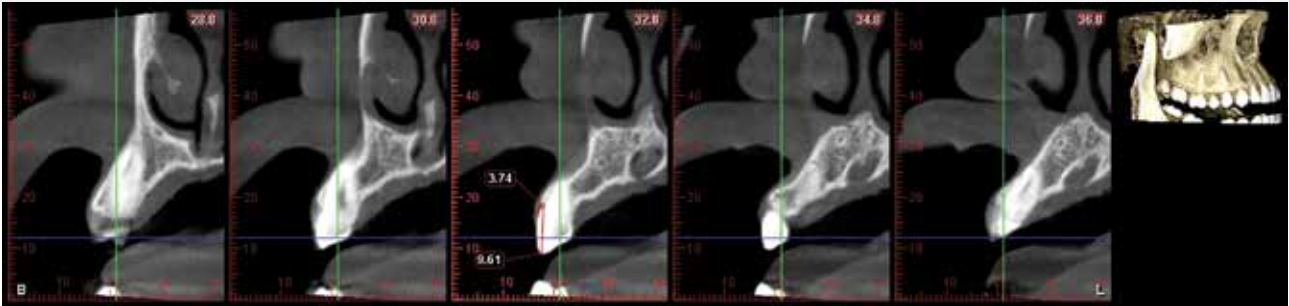


Figure 4: Soft tissue retraction allows for measurement of supra-crestal gingival dimensions.

is required, will be determined by the outcome after healing following the first stage surgery. It is the author's experience that a second stage gingivectomy is often not required due to adequate recession after ostectomy. All patients are given the choice of the second stage and very few opt to have a second stage. Should the planning however involve crowning of the anterior maxillary teeth, it is for the restorative clinician to decide whether optimal lengthening has been reached.

Supracrestal attached tissues (biologic width) and dento-gingival complex

The term biologic width was recently replaced with the term supracrestal attached tissues.^{2,11} The physiological function of the supracrestal attached tissues is that of a protective barrier for the periodontal ligament and supporting alveolar bone.¹² The supracrestal attached tissues include the junctional epithelium and connective tissue attachment, the average dimensions which were measured to be 0,97 mm and 1,07 mm respectively, yielding an average dimension of 2.04 mm for the supracrestal attached tissues.¹³ A more recent systematic review found similar mean values of the supracrestal attached tissues, reported as 2.15 mm - 2.30 mm.¹² It is however extremely difficult, if not impossible, to clinically measure the dimension of the supracrestal attached tissues accurately. For this reason, we should rather rely on the dimension of the dento-gingival complex, which can be measured clinically or by soft tissue CBCT (Figure 4). The dento-gingival complex includes the sulcus depth, in addition to the junctional epithelium and connective tissue attachment. A study examining the supraosseous gingiva dimension (dento-gingival complex), found the mean dimension of the maxillary facial dento-gingival complex to range between $3,71 \pm 0,51$ mm and $4,03 \pm 0,41$ mm.¹⁴

Disagreement still exists among authors with regards to the amount of ostectomy needed during crown lengthening

procedures.⁶ The suggested distance between bone crest and cemento-enamel junction range between 1 - 3 mm and the suggested distance from bone crest to planned gingival margin is ≥ 3 mm.^{7,15-23} Therefore, it is reasonable to perform presurgical measurement of the dento-gingival complex in each patient, to determine the extent of bone removal during a crown lengthening procedure.

It has been shown that significant alterations can occur in the marginal periodontal tissue level from the day of surgery up to 12-months following healing.²⁴ The greatest changes occur during the first 3 months after surgery.²⁵ The coronal shift of the soft tissue margin during healing, also referred to as soft tissue rebound, is more pronounced in thick periodontal phenotypes, compared to thin phenotypes.²⁴ For this reason, planning the extent of ostectomy should also take into consideration the patient's periodontal phenotype.⁴ The term periodontal biotype was recently replaced with the term periodontal phenotype.² Periodontal phenotype describes both the gingival phenotype (gingival thickness and keratinized tissue width) and the thickness of the buccal bone plate.¹¹ Biotype refers to a group of organs which have the same genotype, whereas phenotype refers to the appearance of an organ based on a multifactorial combination of genetic traits and environmental factors.¹¹ The phenotype, unlike genotype, can change over time or can be modified by means of clinical intervention.¹¹

To further complicate treatment planning, the mere action of elevating a full thickness flap during crown lengthening, may cause marginal bone loss. Two clinical studies reported a mean crestal bone loss of 0,6 mm and 0,47 mm respectively, after full thickness flap elevation.^{26,27} If the surgeon did not plan for this additional bone loss, treatment may lead to unsatisfactory results such as exposed root surfaces or crown margins. It is thus clear that meticulous treatment planning should be performed before treatment commences.

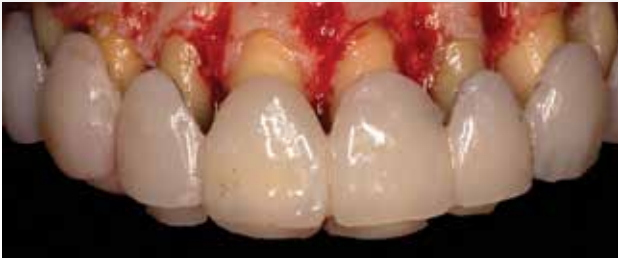

Figure 5: Surgical stent used to assess ostectomy levels.

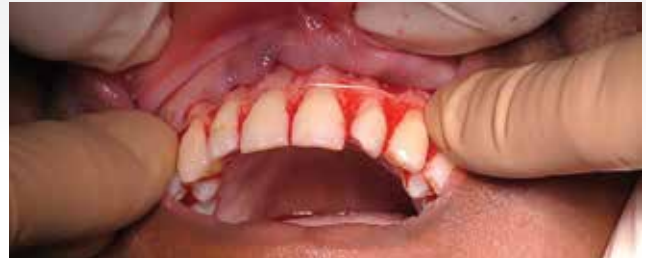

Figure 6: Floss can be cold sterilized and used intra-operative to assess symmetry in bone levels.

Two Stage Crown lengthening

The technique of performing a CL in two stages, with ostectomy and osteoplasty done in stage 1 and a gingivectomy, if indicated, in stage 2, is a predictable procedure with a low trauma impact to the patient. The alveolar bone is removed and shaped in the first procedure without any soft tissue removal and after a few months of healing, a second procedure of gingivectomy may be needed if there has not been sufficient gingival recession.

The classic procedure of crown lengthening is a single procedure, involving a simultaneous soft tissue contouring (excision) and bone removal (ostectomy). David Garber introduced the two stage crown lengthening in the early 1990's, describing a procedure where the bone contouring is done in the first procedure and the gingival contouring in a subsequent procedure after a suitable period of healing.²⁸ Removing gingiva (and bone) in one procedure in a perfect aesthetic symmetry is difficult and will harm the patient by

reducing vital attached gingiva needed for long-term stability. In the authors' experience, very few if any patients have enough gingiva to undergo excision during a crown lengthening. It may also prove difficult to achieve a thin feather edge to the marginal gingiva, which gives the most ideal aesthetics, when excising gingival tissue in a one stage procedure.

Bone contouring by itself, is a more controlled slow process, where different diamond burs are used to sculpt the bone and finish it in a thin feather edge which in turn will induce a thin marginal gingival edge. Achieving perfect symmetry with this process is also easier due to the slow controlled removal of tissue whilst allowing measurements using either a periodontal probe, a surgical stent (Figure 5) and floss to do a quick check intra-operatively (Figure 6).

Before any periodontal aesthetic surgery for excessive gingival display can be planned, a simple decision-making tree can be utilized to determine the diagnosis and following from that the correct procedure can be selected (Figure 7):

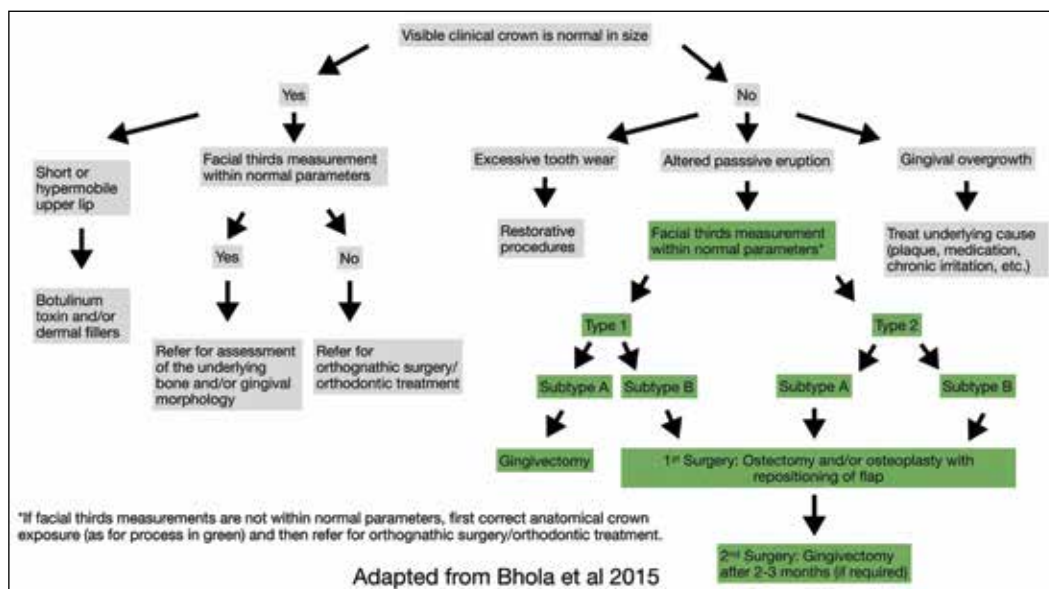


Figure 7: Decision tree for diagnosing excessive gingival display and selecting appropriate treatment.

Tooth measurements

The visible crowns of the anterior six maxillary teeth are important in the smile. Before any crown lengthening can be contemplated, the tooth sizes should be measured and documented in the file. Central incisor teeth are approximately the same size as the canines and in the range of 10-13mm, whereas lateral incisors are slightly smaller and in the range of 9-11mm.²⁹

Case report: Two stage crown lengthening - a 25-year follow-up

A 34-year-old patient presented with a gummy smile (Figure 8) which was classified as altered passive eruption type 1B. The patient needed a full rehabilitation of the occlusion due to a deep bite, attrition on the palatal aspects of teeth 13-23 and loss of posterior occlusal stability. The patient had excellent plaque control, no periodontal disease and a non-vital 11 due to trauma a few years prior to consultation.

Radiographic examination revealed no alveolar bone loss and clinical probing depths varied from 1-3 mm.

The anterior maxillary teeth had over-erupted due to the attrition and lack of occlusal stability.

It was decided to perform a two-stage crown lengthening as it required extensive lengthening and the patient's aesthetic expectations were high. After a wax-up, a surgical crown lengthening guide was manufactured to fit over the teeth (Figure 9) to give an indication of what would be required to restore the smile surgically as well as prosthetically. The stent was fitted in the patient's mouth and a black pencil was used to block-out the incisal edges to simulate the final incisal edges and size of the teeth (Figure 10). This allowed a clear estimation of how much lengthening would be required. Photographs were taken and it was decided to do an ostectomy first, followed by a second stage of gingivectomy after 3-4 months.

Following administration of local anaesthesia, the ostectomy and osteoplasty was performed after elevating a full thickness buccal flap with no palatal flap elevation (Figure 11). The surgical guide served as a reference for the planned crown margins, to ensure adequate amount of ostectomy and to prevent future violation of the space to be occupied by the supra-crestal attached tissues. Deep interdental split thickness flap design allowed full access to the interdental bone for contouring. No interdental crestal reduction was done, mainly because it was not indicated

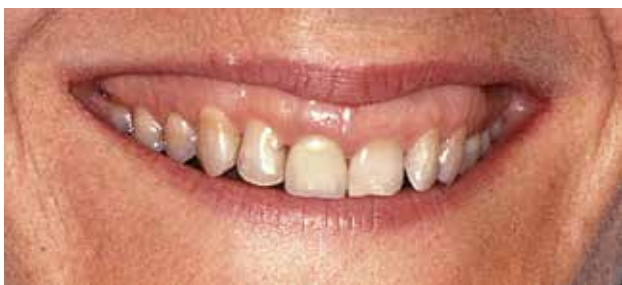

Figure 8: Altered passive eruption with a component of vertical maxillary excess, showing incomplete exposure of clinical crowns.

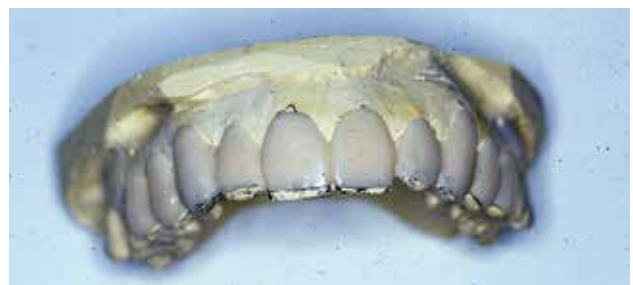

Figure 9: Surgical stent to indicate the new planned clinical crowns.

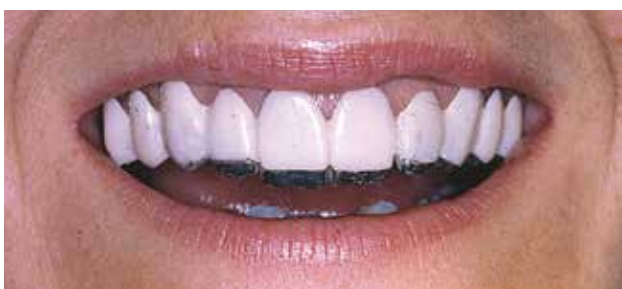

Figure 10: Surgical stent placed intra-orally with incisal edges blocked out using a black pencil.

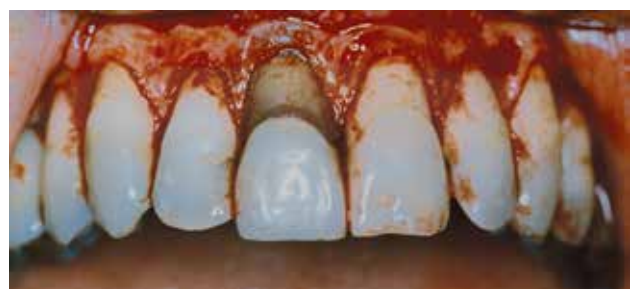

Figure 11: Full flap reflection with partial thickness interdentally, allowing access to buccal and interdental bone for ostectomy and osteoplasty.

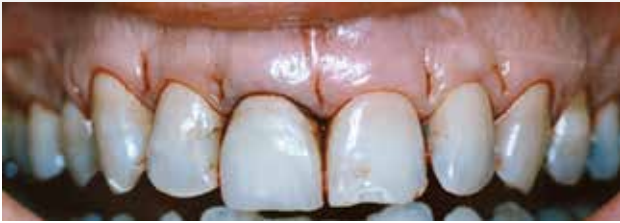

Figure 12: Closure of flap with vertical everting mattress sutures to allow for maximum soft tissue fill in embrasure spaces.

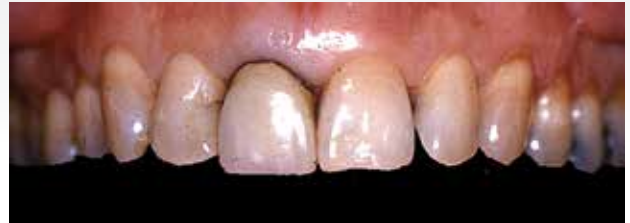

Figure 13: Healing after 3 months showing 2-3mm of recession in a symmetrical pattern, following the bone contour.

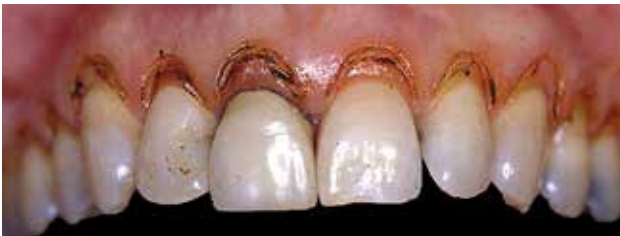

Figure 14: Second stage gingivectomy after 4 months.

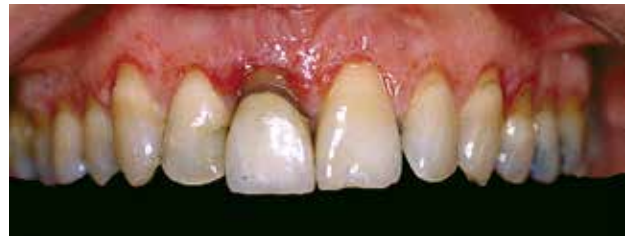

Figure 15: Two weeks after second stage surgery, showing the extent of lengthening.

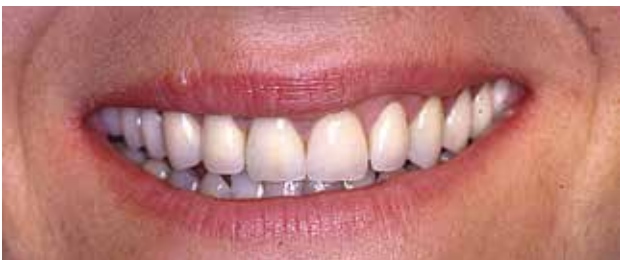

Figure 16: Six months after placing final crowns.

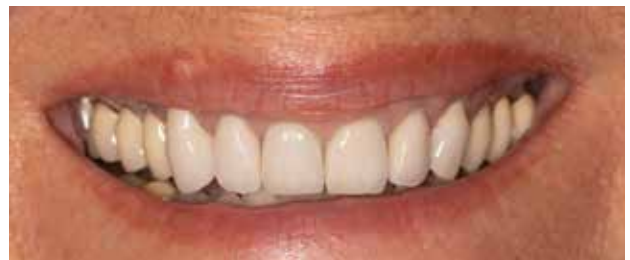

Figure 17: 25 Years after surgery, showing stable gingival margins.

in this case, but also to prevent inadequate papillae fill in the gingival embrasure spaces after healing (Figure 11). Vertical everting mattress 6/0 braided sutures were used to close the flap with maximum embrasure filling with soft tissue (Figure 12). Although monofilament sutures such as nylon have less bacterial contamination potential, softer braided sutures are much more comfortable to the patient. Healing was uneventful and some lengthening was obtained with the recession that took place after osteotomy (Figure 13).

After 4 months, gingivectomy was done with scalpel, cauterization and thinning of the tissue by course diamond drills (Figure 14). This was possible due to the presence of a wide band of attached keratinized mucosa (altered passive eruption type 1). Two weeks later, healing shows extensive lengthening (Figure 15)

VITA In-Ceram® (VITA Zahnfabrik, Germany) all-porcelain crowns were placed after a further 4 months of healing and tissue maturation, with a good aesthetic outcome (Figure 16).

The patient was followed up at regular intervals and after 15 years the anterior 6 crowns (13-23) were replaced due to marginal fractures of the In-Ceram® crowns on the palatal aspects.

The periodontal tissues are stable at 25 years (Figure 17). This case demonstrates a stable long-term result of performing extensive aesthetic crown lengthening utilizing a two-stage surgical protocol with a predictable step-by-step treatment. This allowed full control and minimal loss of attached gingiva, due to at least 2-3 mm of lengthening obtained from the process of recession.

Acknowledgements

The authors would like to thank Dr. Callie Hamman, Prosthodontist, private practice, Durbanville, Cape Town for the prosthodontic concept, stent and crowns of the Case Report. as well as Dental Technician: Ian Robertson, Bellville, Cape Town

References

1. Prato GPP. Mucogingival deformities. *Ann. Periodontol.* 1999; 4(1):98-100.
2. Caton JG, Armitage G, Berglundh T, Chapple IL, Jepsen S, Kornman KS, et al. A new classification scheme for periodontal and peri-implant diseases and conditions—introduction and key changes from the 1999 classification. *J. Periodontol.* 2018; 89:S1-S8.
3. Miller JP. Concept of periodontal plastic surgery. *Practical periodontics and aesthetic dentistry: PPAD.* 1993; 5(5):15-20, 2; quiz 2.
4. Marzadori M, Stefanini M, Sangiorgi M, Mounssif I, Monaco C, Zucchelli G. Crown lengthening and restorative procedures in the esthetic zone. *Periodontol.* 2000. 2018; 77(1):84-92.
5. Januario AL, Barriviera M, Duarte WR. Soft tissue cone-beam computed tomography: A novel method for the measurement of gingival tissue and the dimensions of the dentogingival unit. *Journal of esthetic and restorative dentistry.* 2008; 20(6):366-73.
6. Mele M, Felice P, Sharma P, Mazzotti C, Bellone P, Zucchelli G. Esthetic treatment of altered passive eruption. *Periodontol.* 2000. 2018; 77(1):65-83.
7. Robbins JW. Differential diagnosis and treatment of excess gingival display. *Practical periodontics and aesthetic dentistry: PPAD.* 1999; 11(2):265-72; quiz 73.
8. Volchansky A, Cleaton-Jones P. Delayed passive eruption. A predisposing factor to vincent's infection. *J. Dent. Assoc. S. Afr.* 1974; 29:291-4.
9. Vanarsdall R, Coslet J, Weisgold A. Diagnosis and classification of delayed passive eruption of the dentogingival junction in the adult. *The Alpha Omegan.* 1977.
10. Alpiste-Illueca F. Altered passive eruption (ape): A little-known clinical situation. *Med. Oral Patol. Oral Cir. Bucal.* 2011; 16(1):e100-4.
11. Jepsen S, Caton JG, Albandar JM, Bissada NF, Bouchard P, Cortellini P, et al. Periodontal manifestations of systemic diseases and developmental and acquired conditions: Consensus report of workgroup 3 of the 2017 world workshop on the classification of periodontal and peri-implant diseases and conditions. *J. Clin. Periodontol.* 2018; 45:S219-S29.
12. Schmidt JC, Sahrman P, Weiger R, Schmidlin PR, Walter C. Biologic width dimensions—a systematic review. *J. Clin. Periodontol.* 2013; 40(5):493-504.
13. Gargiulo AW, Wentz FM, Orban B. Dimensions and relations of the dentogingival junction in humans. *The Journal of Periodontology.* 1961; 32(3):261-7.
14. Perez JR, Smukler H, Nunn ME. Clinical dimensions of the supraosseous gingivae in healthy periodontium. *J. Periodontol.* 2008; 79(12):2267-72.
15. Cairo F, Graziani F, Franchi L, Defraia E, Pini Prato GP. Periodontal plastic surgery to improve aesthetics in patients with altered passive eruption/gummy smile: A case series study. *International journal of dentistry.* 2012; 2012.
16. Camargo PM, Melnick PR, Camargo L. Clinical crown lengthening in the esthetic zone. *Journal of the California Dental Association.* 2007; 35(7):487-98.
17. Rossi R, Benedetti R, Isabel Santos-Morales R. Treatment of altered passive eruption: Periodontal plastic surgery of the dentogingival junction. *European Journal of Esthetic Dentistry.* 2008; 3(3).
18. Dolt AH, Robbins JW. Altered passive eruption: An etiology of short clinical crowns. *QUINTESSENCE INTERNATIONAL-ENGLISH EDITION.* 1997; 28:363-74.
19. Batista Jr EL, Moreira CC, Batista FC, de Oliveira RR, Pereira KK. Altered passive eruption diagnosis and treatment: A cone beam computed tomography-based reappraisal of the condition. *J. Clin. Periodontol.* 2012; 39(11):1089-96.
20. Ribeiro FV, Hirata DY, Reis AF, Santos VR, Miranda TS, Faveri M, et al. Open-flap versus flapless esthetic crown lengthening: 12-month clinical outcomes of a randomized controlled clinical trial. *J. Periodontol.* 2014; 85(4):536-44.
21. Levine R, McGuire M. The diagnosis and treatment of the gummy smile. *Compendium of continuing education in dentistry (Jamesburg, NJ: 1995).* 1997; 18(8):757-62, 64; quiz 66.
22. Claman L, Alfaro MA, Mercado A. An interdisciplinary approach for improved esthetic results in the anterior maxilla. *The Journal of prosthetic dentistry.* 2003; 89(1):1-5.
23. Abou-Arraq RV, Souccar NM, editors. *Periodontal treatment of excessive gingival display.* Semin. Orthod.; 2013: Elsevier.
24. Pontoriero R, Carnevale G. Surgical crown lengthening: A 12-month clinical wound healing study. *J. Periodontol.* 2001; 72(7):841-8.
25. Pilalas I, Tsalikis L, Tatakis DN. Pre-restorative crown lengthening surgery outcomes: A systematic review. *J. Clin. Periodontol.* 2016; 43(12):1094-108.
26. Donnerfeld OW, Marks RM, Glickman I. The apically repositioned flap—a clinical study. *The Journal of Periodontology.* 1964; 35(5):381-7.
27. Tavtigan R. The height of the facial radicular alveolar crest following apically positioned flap operations. *J. Periodontol.* 1970; 41(7):412-8.
28. Garber DA, Salama MA. The aesthetic smile: Diagnosis and treatment. *Periodontol.* 2000. 1996; 11(1):18-28.
29. Magne P, Gallucci GO, Belser UC. Anatomic crown width/length ratios of unworn and worn maxillary teeth in white subjects. *The Journal of prosthetic dentistry.* 2003; 89(5):453-61.