

## How to use this document - Quick-access buttons



Click on the navigation arrows at the bottom of each page to navigate to **Previous or Next page**  
Use the **Home button** at the end of each article to return to the Contents page



**Adverts:** Click on products or contact details to open the advertiser's website in your web browser



# Dentistry

INTERNATIONAL DENTISTRY - AFRICAN EDITION

VOL. 10 NO. 3

IN THIS ISSUE

**André W van Zyl and Inus Snyman**  
**Aesthetic two stage crown lengthening for altered passive eruption: A 25-year case report and review**

**Mrudula Patel, Jainisha Desai and Peter C Owen**  
**The efficacy of disinfectants in the decontamination of dental unit water lines: an in vitro laboratory study**

**Andrea Klink, Fabian Hüttig and Martin Groten**  
**All-ceramic single-tooth restorations for treating damaged dental enamel: Long-term results in patients with and without amelogenesis imperfecta**

**João Mauricio Ferraz da Silva and Danilo de Souza Andrade**  
**Aesthetic anterior tooth restorations with nano-ceramic hybrid CAD/CAM blocks**

**Josef Kunkela**  
**Highly esthetic results with a new milling machine**

**Attilio Sommella**  
**Advanced concepts. Guided reduction for crowns and bridges**



Wright  
MILLNERS

## Premium Essential Composite

# Forma™

ZIRCONIA NANO-HYBRID COMPOSITE



STRONG, VERSATILE, AND EASY TO SCULPT!

OneStepColor



Zirconia nano-hybrid resin



Natural fluorescence



Simple handling and polishability

ULTRADENT

JINME DENTAL HANDPIECE CO.LTD.

jinme

1:5 Electric Red Ring Handpiece



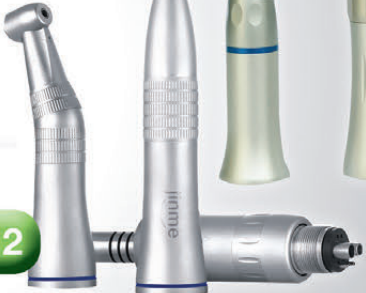J5



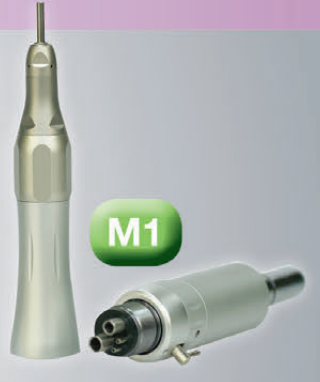J6



M2




M1



Zero Retraction



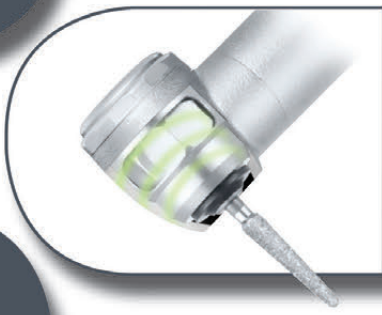Less Noise



Powerful & Durable LED



Quick Stop System



Built in Pressure Regulator



SCAN HERE FOR MORE INFO





**IAD**  
inter-africa dental<sup>pty(ltd)</sup>

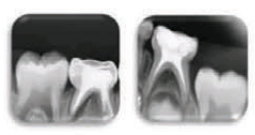

**012 342 8551**

"Passionate about Dentistry!"

**PEDIATRIC ROTARY FILES**

**PRO AF  
BABY  
GOLD  
FILE**




Free Autoclavable Box

**e-MTA™**  
Mineral Trioxide Aggregate



- Bio-Active
- Washout Resistant
- Quick Setting
- Smart Packaging
- Gel Based Technology

**Kids-e-Crown™**  
"The Smart Crown"



**High quality zirconia**

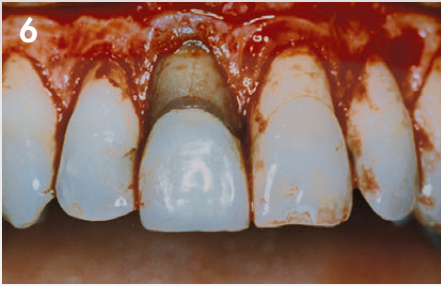- High Strength  
Load bearing 1200 MPa
- Chemical Resistant  
Chemically Stable
- Wear Resistant  
High Resistance to wear and tear
- Bio Compatible  
Highly Bio-Compatible



**e-SDF™**  
38% Silver Diamine Fluoride

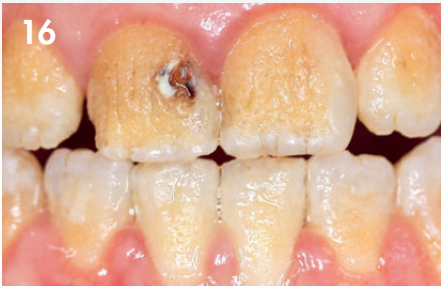

**Kids-e-Dental™**

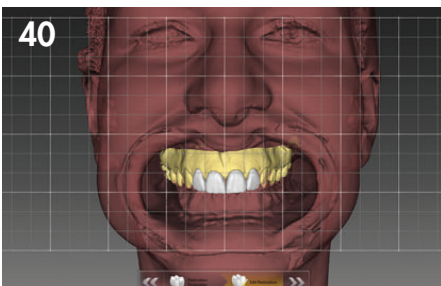
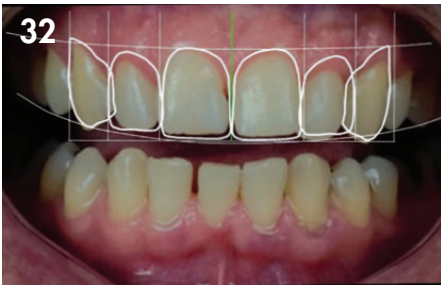
# Contents

June/July 2020  
Volume 10 No.3



- ▷ **06** Clinical  
Aesthetic two stage crown lengthening for altered passive eruption:  
A 25-year case report and review  
*André W van Zyl and Inus Snyman*
- ▷ **16** Clinical  
The efficacy of disinfectants in the decontamination of dental unit water  
lines: an in vitro laboratory study  
*Mrudula Patel, Jainisha Desai and Peter C Owen*
- ▷ **24** Clinical  
All-ceramic single-tooth restorations for treating damaged dental enamel:  
Long-term results in patients with and without amelogenesis imperfecta  
*Andrea Klink, Fabian Hüttig and Martin Groten*
- ▷ **32** Clinical  
Aesthetic anterior tooth restorations with nano-ceramic hybrid CAD/  
CAM blocks  
*João Mauricio Ferraz da Silva and Danilo de Souza Andrade*
- ▷ **40** Clinical  
Highly esthetic results with a new milling machine  
*Josef Kunkela*
- ▷ **44** Clinical  
Advanced concepts. Guided reduction for crowns and bridges  
*Attilio Sommella*
- ▷ **48** CPD Questionnaire 1    ▷ **49** CPD Questionnaire 2
- ▷ **50** Products and News    ▷ **50** Classifieds



Premium Essential Composite

## FORMA™

ZIRCONIA NANO-HYBRID COMPOSITE

STRONG, VERSATILE AND EASY TO SCULPT!

Wright MILLERS

**DR. RAFAEL BEOLCHI**

FORMA composite demonstrates a working consistency that facilitates both the sculpting of anatomical details in posterior teeth and control over the thickness of the layers of resin in anterior teeth, essential for esthetic restorations.

**Diastema Closure**  
*Fernando Rigolin and Dr. Rafael Beolchi*

1. Patient's smile, exhibiting multiple gaps between central and lateral incisors
2. Close-up view of gaps in the upper arch
3. Restoration with only one body color (A1B)
4. FORMA composite shows an excellent balance between opacity and translucency

OneStepColor

**YOUR PREMIUM ESSENTIAL COMPOSITE**  
**BEST QUALITY AT THE BEST PRICE**  
**COVID RELIEF**

**FORMA™**

**ZIRCONIA NANO-HYBRID COMPOSITE**



Zirconia nano-hybrid resin



Natural fluorescence



Simple handling and polishability



STRONG, VERSATILE AND EASY TO SCULPT!



Ergonomic handle protects the thread of the syringe, reducing the risk of contamination.

[Click Here To View Full Brochure](#)

**OneStepColor**



**Buy 1x FORMA Syringe Kit**

Forma Kit Contains:

5x 4g FORMA Syringes  
(1x A1B, 2x A2B, 1x A3B, 1x A3,5B)

**For: R1699.00**

**Get 1x FREE**

Ultra Etch Kit  
4x 1.2ml Syringes



Valued at  
R685.00

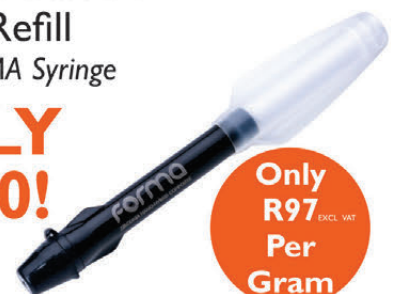**TOTAL SAVINGS:**  
**R1185**  
per deal

**Buy 1x FORMA**

**Syringe Refill**

1x 4g FORMA Syringe

**ONLY R440!**



**Only R97**  
EXCL. VAT  
**Per Gram**

# Dentistry

INTERNATIONAL DENTISTRY - AFRICAN EDITION

Vol. 10 No. 3, June/July 2020  
ISSN 2226-1567

## PUBLISHING EDITOR

Ursula Jenkins

## EDITOR

Prof Simone Grandini

## ASSOCIATE EDITORS

Prof Cecilia Goracci  
Prof Andre W van Zyl

## EDITOR-IN-CHIEF EMERITUS

Prof Dr Marco Ferrari

## EDITORIAL REVIEW BOARD

Prof Paul V Abbott  
Dr Marius Bredell  
Prof Kurt-W Bütow  
Prof Ji-hua Chen  
Prof Ricardo Marins de Carvalho  
Prof Carel L Davidson  
Prof Massimo De Sanctis  
Dr Carlo Ercoli  
Prof Roberto Giorgetti  
Dr Patrick J Henry  
Prof Dr Reinhard Hickel  
Dr Sascha A Jovanovic  
Dr Gerard Kugel  
Prof Ian Meyers  
Prof Maria Fidela de Lima Navarro  
Prof Hien Ngo  
Dr Hani Ounsi  
Prof Antonella Polimeni  
Prof Eric Reynolds  
Prof Andre P Saadoun  
Prof Errol Stein  
Prof Lawrence Stephen  
Prof Zrinka Tarle  
Prof Franklin R Tay  
Prof Manuel Toledano  
Dr Bernard Touati  
Prof Laurence Walsh  
Prof Fernando Zarone

## DESIGN & LAYOUT

C Designz

## PRINTED BY

Novus Print

International Dentistry African Edition is published by Modern Dentistry Media CC, PO Box 76021 Wendywood 2144 South Africa Tel: +27 11 702-3195 e-mail: dentsa@iafrica.com www.moderdentistrymedia.com

## © COPYRIGHT. All rights reserved.

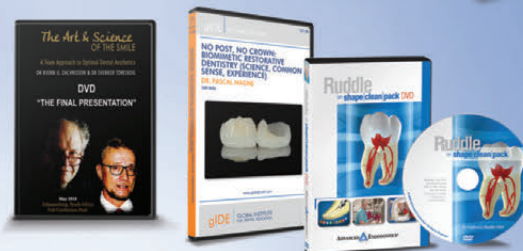No editorial matter published in International Dentistry African Edition may be reproduced in any form or language without the written permission of the publishers. While every effort is made to ensure accurate reproduction, the authors, publishers and their employees or agents shall not be held responsible or in any way liable for errors, omissions or inaccuracies in the publication whether arising from negligence or otherwise or for any consequence arising therefrom.

Published in association with



## JOURNALS

## BOOKS



## DVDS

**MDM**  
modern dentistry media

moderdentistrymedia.com



QUINTESSENCE PUBLISHING



DENTAL TRIBUNE  
The World's Dental Newspaper - South African Edition

WORLD'S  
**NO.1**  
DENTURE CARE  
BRAND\*



DENTURE CARE

# EAT, SPEAK AND SMILE WITH CONFIDENCE



\*Value Retail Sales data for GSK-branded denture care products, 12 months ending February 2019. GlaxoSmithKline Consumer Healthcare South Africa (Pty) LTD. 57 Sloane Street, Bryanston, 2021 Refer to carton for full prescribing information.

Trademarks are owned or licensed to the GSK group of companies.

For any product safety issues contact GSK Consumer on +27 11 745 6001.

CHZAF/CHPOLD/0004/19



# Aesthetic two stage crown lengthening for altered passive eruption: A 25-year case report and review

André W van Zyl<sup>1</sup> and Inus Snyman<sup>2</sup>

## Introduction

Mucogingival abnormalities may involve lack of gingiva, excess gingiva, recession, shallow vestibule, abnormal colour and aberrant frenula (AAP Consensus 1999).<sup>1,2</sup> Periodontal plastic surgery was a term introduced by Preston Miller in the early nineties to describe mucogingival or periodontal procedures dealing with aesthetics.<sup>3</sup> It is of the utmost importance to understand that none of the conditions or procedures described in this article can be correctly diagnosed or treated until such time as all infection and inflammation have been resolved. There should be no gingivitis or periodontitis present.

Periodontists are often requested to correct an excessive gingival display or correct excessive exposure of teeth due to recession. Periodontal aesthetic surgery around natural teeth therefore involves either the removal of excess tissue in gummy smiles or the repair of lost tissue such as in recession. The former involves the procedure of crown lengthening or gingivectomy and the latter the treatment of marginal gingival recession by grafting. Crown lengthening is carried out either for aesthetic or functional purposes. Indications for crown lengthening include subgingival caries, crown or root fractures, altered passive eruption, short teeth, excessive gingival display, uneven gingival contours, cervical root resorption and short clinical abutment.<sup>4</sup> This article will cover excessive gingival display (Altered Passive Eruption, APE) and the procedure of two stage crown lengthening only.

Crown lengthening (CL) may be achieved by either gingivectomy (removal of excess gingiva) or by removal of bone (osteotomy) and gingiva. It is essential to determine whether bone needs to be removed for lengthening. In the past this was done by doing bone sounding under local anaesthesia, which is a fairly invasive procedure. CBCT is now an alternative and not only can bone be assessed by this, but the soft tissue too, provided a soft tissue CBCT approach is used.<sup>5</sup>

CL is aimed at exposing more of the clinical crown of the tooth. There are various reasons why this may be desirable but for the purpose of this article we will focus on two of the main aesthetic reasons caused by APE:

1. A gummy smile where the teeth are not fully exposed and partly covered by gingiva (Figure 1)
2. An asymmetric gingival contour which is not aesthetic (Figure 2)

<sup>1</sup> André W van Zyl: BChD, MChD. Private Practice Periodontist, Hermanus & Honorary Professor, Department of Oral Medicine and Periodontics, Faculty of Health Sciences, University of Witwatersrand. ORCID Number: 0000-0002-7985-4054

<sup>2</sup> Inus Snyman: BChD, PDD (Implantology), PGDipDent (Oral Surgery), PGDipDent (Implantology). Department of Periodontics and Oral Medicine, School of Dentistry, Faculty of Health Sciences, University of Pretoria. ORCID Number: 0000-0002-8480-5361

### Corresponding author:

André W van Zyl  
Private Practice Periodontist,  
Hermanus & Honorary Professor,  
Department of Oral Medicine  
and Periodontics, University of  
Witwatersrand, South Africa.  
Tel: +27(28) 3121510  
E-mail: info@andrevanzyl.co.za

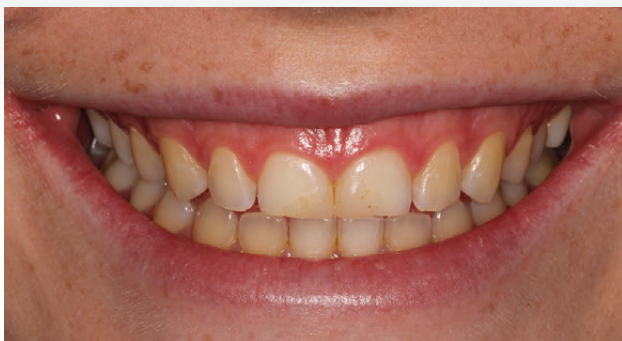

Figure 1: Gummy smile due to Altered Passive Eruption.

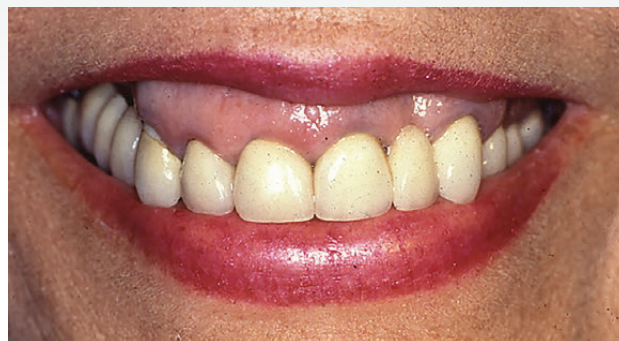

Figure 2: Asymmetric gingival contour.

It is important to be able to diagnose the underlying problem correctly before embarking on the procedure.

### Altered Passive Eruption (APE)

It is important to note that excessive gingival display is not always due to APE, but may also be due to vertical maxillary excess, sometimes in combination with a high lip line (Figure 3).<sup>6,7</sup>

In a South African study it was found that Delayed Passive Eruption had a prevalence of 12%.<sup>8</sup> Excessive gingival display is most often diagnosed as APE, but it may also be seen in drug induced enlargement and in plaque induced swelling.<sup>6</sup> Passive eruption is the process that occurs after the tooth erupts into the oral cavity (the active eruption phase) and is the process where the gingiva slowly migrates apically to expose the anatomical crown.<sup>6</sup> APE occurs when the gingiva does not reach its correct position and covers part of the clinical crown, giving a gummy appearance.<sup>6</sup> It is not clear exactly when the physiological movement of passive eruption ends and thus, at what age a diagnosis of APE can be made.<sup>6</sup> Coslett et al. reported that by the age of 18 -20 years, the majority of individuals have a mature dentogingival relationship.<sup>9</sup>

Multiple factors have been proposed as possible causes for APE. These include occlusal interference by soft tissue during the eruption phase, the presence of thick fibrotic gingiva, genetics, the presence of thick bone, orthodontic trauma and endocrine conditions.<sup>10</sup>

APE can be classified into two types, based on the position of the mucogingival junction in relation to the cemento-enamel junction.<sup>9</sup> Type 1 APE is characterised by the mucogingival junction being apical to the alveolar bone crest, usually with a wide band of attached gingiva.<sup>6</sup> This band of attached gingiva is usually wider than the generally

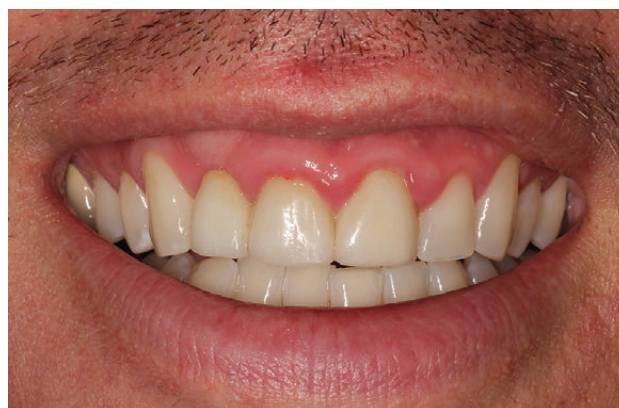

Figure 3: A gummy smile due to vertical maxillary excess where teeth are almost fully exposed.

accepted mean width of 3,0 - 4,2 mm in the maxilla and 2,5 - 2,6 mm in the mandible.<sup>6</sup> In contrast, Type 2 APE is defined by the presence of a band of attached gingiva which falls within the normal mean width.<sup>6</sup> In type 2 APE, the mucogingival junction is located at the level of the cemento-enamel junction, with the whole band of attached gingiva located on the anatomic crown.<sup>6</sup> Both type 1 and type 2 APE, can further be subclassified into subgroup A or subgroup B.<sup>6</sup> In subgroup A, the alveolar bone crest is located at the normal position, 1 – 3 mm apical to the cemento-enamel junction.<sup>6</sup> Subgroup B refers to those cases where the alveolar bone crest is located at or coronal to the level of the cemento-enamel junction.<sup>6</sup> Correct classification and diagnosis of each case is of critical importance before treatment commences. APE type 1 subgroup A may be treated with gingivectomy alone, whereas the authors recommend a two-stage crown lengthening approach for all other classifications.<sup>6</sup> Whether the second stage surgery (gingivectomy) in a two-stage crown lengthening approach

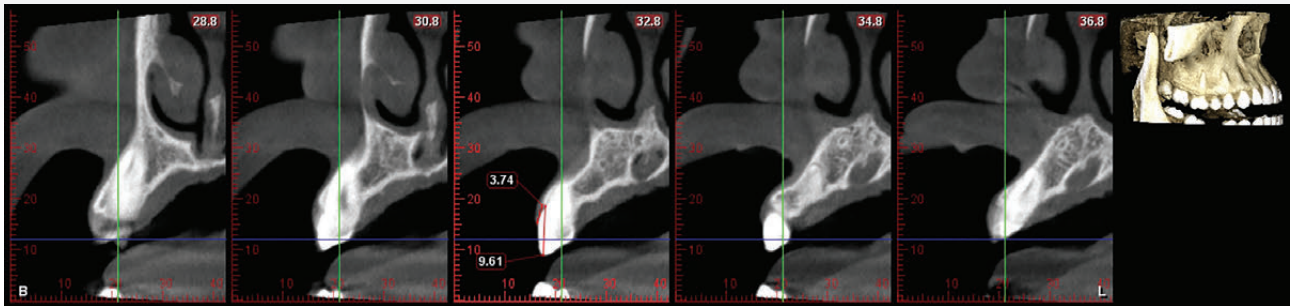


Figure 4: Soft tissue retraction allows for measurement of supra-crestal gingival dimensions.

is required, will be determined by the outcome after healing following the first stage surgery. It is the author's experience that a second stage gingivectomy is often not required due to adequate recession after ostectomy. All patients are given the choice of the second stage and very few opt to have a second stage. Should the planning however involve crowning of the anterior maxillary teeth, it is for the restorative clinician to decide whether optimal lengthening has been reached.

### Supracrestal attached tissues (biologic width) and dento-gingival complex

The term biologic width was recently replaced with the term supracrestal attached tissues.<sup>2,11</sup> The physiological function of the supracrestal attached tissues is that of a protective barrier for the periodontal ligament and supporting alveolar bone.<sup>12</sup> The supracrestal attached tissues include the junctional epithelium and connective tissue attachment, the average dimensions which were measured to be 0,97 mm and 1,07 mm respectively, yielding an average dimension of 2.04 mm for the supracrestal attached tissues.<sup>13</sup> A more recent systematic review found similar mean values of the supracrestal attached tissues, reported as 2.15 mm - 2.30 mm.<sup>12</sup> It is however extremely difficult, if not impossible, to clinically measure the dimension of the supracrestal attached tissues accurately. For this reason, we should rather rely on the dimension of the dento-gingival complex, which can be measured clinically or by soft tissue CBCT (Figure 4). The dento-gingival complex includes the sulcus depth, in addition to the junctional epithelium and connective tissue attachment. A study examining the supraosseous gingiva dimension (dento-gingival complex), found the mean dimension of the maxillary facial dento-gingival complex to range between  $3,71 \pm 0,51$  mm and  $4,03 \pm 0,41$  mm.<sup>14</sup>

Disagreement still exists among authors with regards to the amount of ostectomy needed during crown lengthening

procedures.<sup>6</sup> The suggested distance between bone crest and cemento-enamel junction range between 1 - 3 mm and the suggested distance from bone crest to planned gingival margin is  $\geq 3$  mm.<sup>7,15-23</sup> Therefore, it is reasonable to perform presurgical measurement of the dento-gingival complex in each patient, to determine the extent of bone removal during a crown lengthening procedure.

It has been shown that significant alterations can occur in the marginal periodontal tissue level from the day of surgery up to 12-months following healing.<sup>24</sup> The greatest changes occur during the first 3 months after surgery.<sup>25</sup> The coronal shift of the soft tissue margin during healing, also referred to as soft tissue rebound, is more pronounced in thick periodontal phenotypes, compared to thin phenotypes.<sup>24</sup> For this reason, planning the extent of ostectomy should also take into consideration the patient's periodontal phenotype.<sup>4</sup> The term periodontal biotype was recently replaced with the term periodontal phenotype.<sup>2</sup> Periodontal phenotype describes both the gingival phenotype (gingival thickness and keratinized tissue width) and the thickness of the buccal bone plate.<sup>11</sup> Biotype refers to a group of organs which have the same genotype, whereas phenotype refers to the appearance of an organ based on a multifactorial combination of genetic traits and environmental factors.<sup>11</sup> The phenotype, unlike genotype, can change over time or can be modified by means of clinical intervention.<sup>11</sup>

To further complicate treatment planning, the mere action of elevating a full thickness flap during crown lengthening, may cause marginal bone loss. Two clinical studies reported a mean crestal bone loss of 0,6 mm and 0,47 mm respectively, after full thickness flap elevation.<sup>26,27</sup> If the surgeon did not plan for this additional bone loss, treatment may lead to unsatisfactory results such as exposed root surfaces or crown margins. It is thus clear that meticulous treatment planning should be performed before treatment commences.

# Planmeca ProSensor® HD

Intraoral sensor with three different sizes

Our **Planmeca ProSensor® HD** intraoral sensor offers a unique combination of unparalleled image quality, high-end patient-centred design and advanced usability. The digital sensor has been designed to last and provides durability that can be counted on.



**R67 000,00** Incl VAT (price for size 1)

**NOW available over 12 months - INTEREST FREE!**

**12 month term at 0% interest subject to the following:**

Credit approval

Completed application form

Completed assets and liabilities form

## Unparalleled HD Imaging

Supporting detailed diagnostics, **Planmeca ProSensor® HD** captures sharp, low-noise and high-contrast images. With a true resolution of over 20 lp/mm, the intraoral sensor delivers HD image quality and its wide dynamic range ensures successful results each and every time.

**ORDER YOURS TODAY!**

**Adriaan van der Spuy**

+27 76 821 6239

adriaan.vds@planmeca.com

www.planmeca.com



**PLANMECA**

 **Retail  
Capital**  
ASSET FINANCE

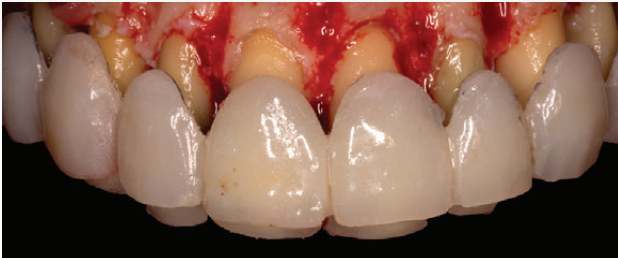

Figure 5: Surgical stent used to assess osteotomy levels.

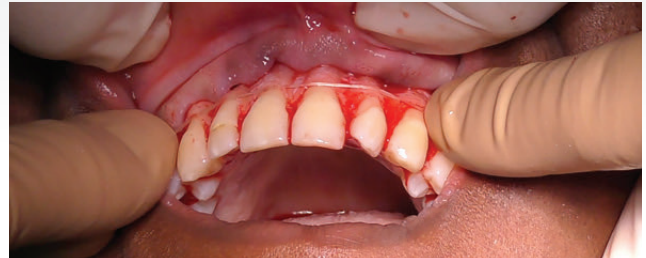

Figure 6: Floss can be cold sterilized and used intra-operative to assess symmetry in bone levels.

### Two Stage Crown lengthening

The technique of performing a CL in two stages, with osteotomy and osteoplasty done in stage 1 and a gingivectomy, if indicated, in stage 2, is a predictable procedure with a low trauma impact to the patient. The alveolar bone is removed and shaped in the first procedure without any soft tissue removal and after a few months of healing, a second procedure of gingivectomy may be needed if there has not been sufficient gingival recession.

The classic procedure of crown lengthening is a single procedure, involving a simultaneous soft tissue contouring (excision) and bone removal (osteotomy). David Garber introduced the two stage crown lengthening in the early 1990's, describing a procedure where the bone contouring is done in the first procedure and the gingival contouring in a subsequent procedure after a suitable period of healing.<sup>28</sup> Removing gingiva (and bone) in one procedure in a perfect aesthetic symmetry is difficult and will harm the patient by

reducing vital attached gingiva needed for long-term stability. In the authors' experience, very few if any patients have enough gingiva to undergo excision during a crown lengthening. It may also prove difficult to achieve a thin feather edge to the marginal gingiva, which gives the most ideal aesthetics, when excising gingival tissue in a one stage procedure.

Bone contouring by itself, is a more controlled slow process, where different diamond burs are used to sculpt the bone and finish it in a thin feather edge- which in turn will induce a thin marginal gingival edge. Achieving perfect symmetry with this process is also easier due to the slow controlled removal of tissue whilst allowing measurements using either a periodontal probe, a surgical stent (Figure 5) and floss to do a quick check intra-operatively (Figure 6).

Before any periodontal aesthetic surgery for excessive gingival display can be planned, a simple decision-making tree can be utilized to determine the diagnosis and following from that the correct procedure can be selected (Figure 7):

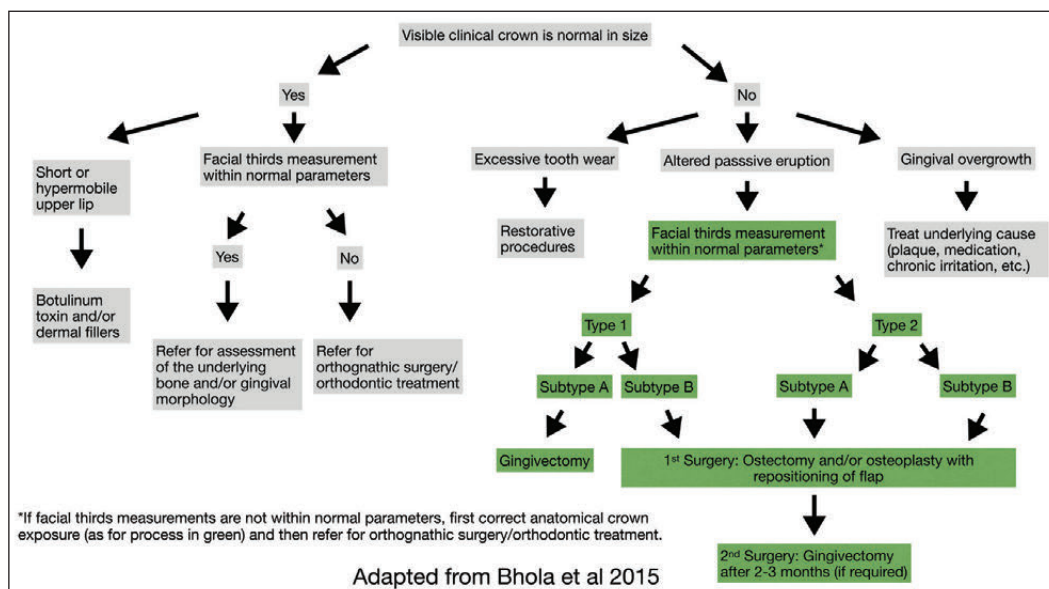


Figure 7: Decision tree for diagnosing excessive gingival display and selecting appropriate treatment.

# STRONGEST IN THEIR CLASS



Also  
available as  
**disc**

## STRONGEST IN THEIR CLASS

### Exceptional material providing strength for CAD / CAM restorations

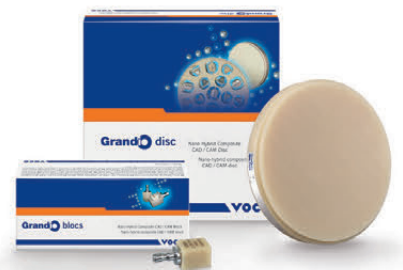- For the fabrication of definitive crowns, inlays, onlays, veneers and implant-supported crowns
- Highest filler content (86 % w/w) for long-lasting durable restorations
- Resembles natural teeth perfectly
- Excellent physical values for flexural strength and abrasion
- Can be polished and repaired optimally
- Based on the nano-hybrid technology



VOCO Distribution Partner  
in South Africa  
Toll Free 0800 111 796

**HENRY SCHEIN®** Johannesburg & Durban  
DENTAL WAREHOUSE

## Grandio® blocs Grandio® disc



**Tooth measurements**

The visible crowns of the anterior six maxillary teeth are important in the smile. Before any crown lengthening can be contemplated, the tooth sizes should be measured and documented in the file. Central incisor teeth are approximately the same size as the canines and in the range of 10-13mm, whereas lateral incisors are slightly smaller and in the range of 9-11mm.<sup>29</sup>

**Case report: Two stage crown lengthening - a 25-year follow-up**

A 34-year-old patient presented with a gummy smile (Figure 8) which was classified as altered passive eruption type 1B. The patient needed a full rehabilitation of the occlusion due to a deep bite, attrition on the palatal aspects of teeth 13-23 and loss of posterior occlusal stability. The patient had excellent plaque control, no periodontal disease and a non-vital 11 due to trauma a few years prior to consultation.

Radiographic examination revealed no alveolar bone loss and clinical probing depths varied from 1-3 mm.

The anterior maxillary teeth had over-erupted due to the attrition and lack of occlusal stability.

It was decided to perform a two-stage crown lengthening as it required extensive lengthening and the patient's aesthetic expectations were high. After a wax-up, a surgical crown lengthening guide was manufactured to fit over the teeth (Figure 9) to give an indication of what would be required to restore the smile surgically as well as prosthetically. The stent was fitted in the patient's mouth and a black pencil was used to block-out the incisal edges to simulate the final incisal edges and size of the teeth (Figure 10). This allowed a clear estimation of how much lengthening would be required. Photographs were taken and it was decided to do an ostectomy first, followed by a second stage of gingivectomy after 3-4 months.

Following administration of local anaesthesia, the ostectomy and osteoplasty was performed after elevating a full thickness buccal flap with no palatal flap elevation (Figure 11). The surgical guide served as a reference for the planned crown margins, to ensure adequate amount of ostectomy and to prevent future violation of the space to be occupied by the supra-crestal attached tissues. Deep interdental split thickness flap design allowed full access to the interdental bone for contouring. No interdental crestal reduction was done, mainly because it was not indicated

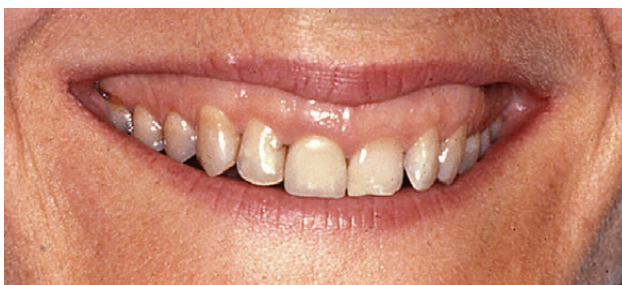

Figure 8: Altered passive eruption with a component of vertical maxillary excess, showing incomplete exposure of clinical crowns.

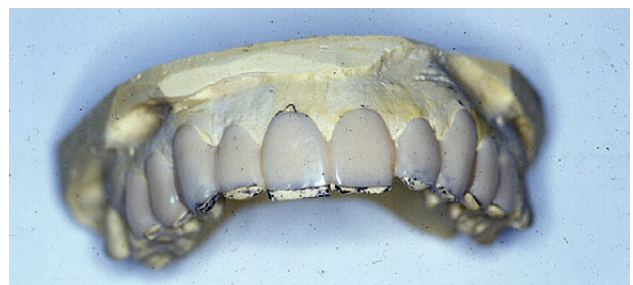

Figure 9: Surgical stent to indicate the new planned clinical crowns.

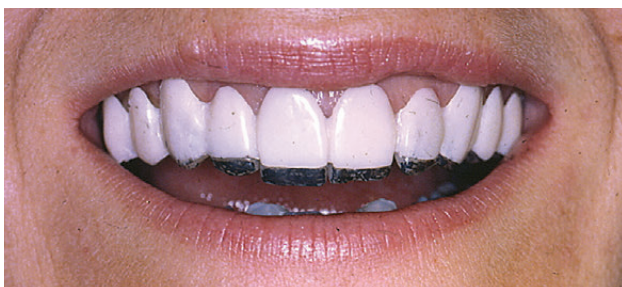

Figure 10: Surgical stent placed intra-orally with incisal edges blocked out using a black pencil.

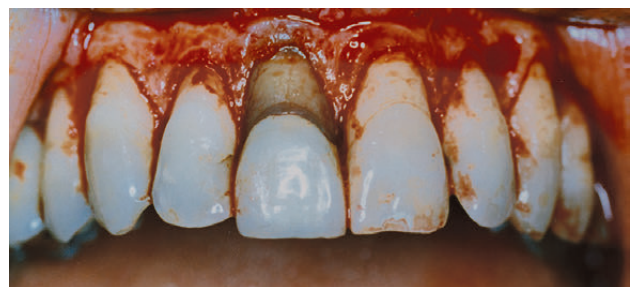

Figure 11: Full flap reflection with partial thickness interdentally, allowing access to buccal and interdental bone for ostectomy and osteoplasty.

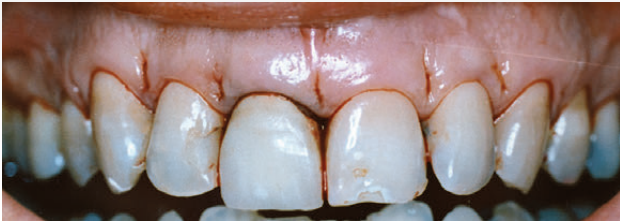

Figure 12: Closure of flap with vertical everting mattress sutures to allow for maximum soft tissue fill in embrasure spaces.

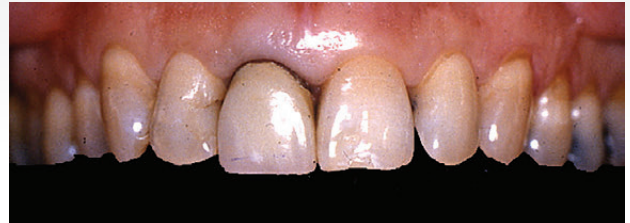

Figure 13: Healing after 3 months showing 2-3mm of recession in a symmetrical pattern, following the bone contour.

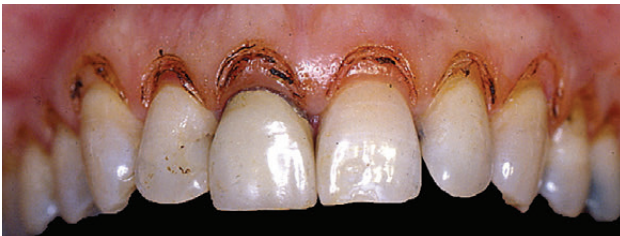

Figure 14: Second stage gingivectomy after 4 months.

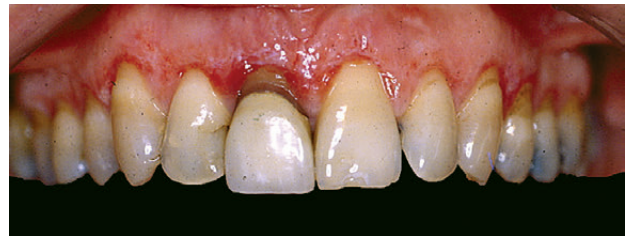

Figure 15: Two weeks after second stage surgery, showing the extent of lengthening.

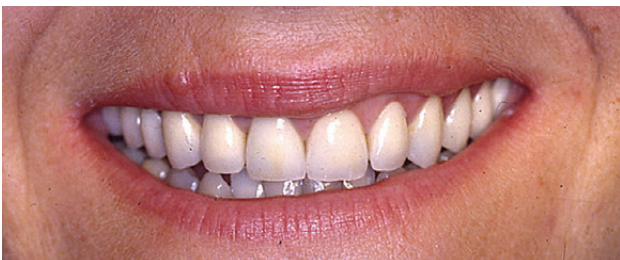

Figure 16: Six months after placing final crowns.

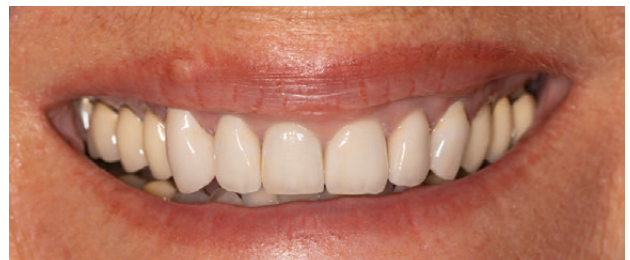

Figure 17: 25 Years after surgery, showing stable gingival margins.

in this case, but also to prevent inadequate papillae fill in the gingival embrasure spaces after healing (Figure 11). Vertical everting mattress 6/0 braided sutures were used to close the flap with maximum embrasure filling with soft tissue (Figure 12). Although monofilament sutures such as nylon have less bacterial contamination potential, softer braided sutures are much more comfortable to the patient. Healing was uneventful and some lengthening was obtained with the recession that took place after osteotomy (Figure 13).

After 4 months, gingivectomy was done with scalpel, cauterization and thinning of the tissue by course diamond drills (Figure 14). This was possible due to the presence of a wide band of attached keratinized mucosa (altered passive eruption type 1). Two weeks later, healing shows extensive lengthening (Figure 15)

VITA In-Ceram® (VITA Zahnfabrik, Germany) all-porcelain crowns were placed after a further 4 months of healing and tissue maturation, with a good aesthetic outcome (Figure 16).

The patient was followed up at regular intervals and after 15 years the anterior 6 crowns (13-23) were replaced due to marginal fractures of the In-Ceram® crowns on the palatal aspects.

The periodontal tissues are stable at 25 years (Figure 17). This case demonstrates a stable long-term result of performing extensive aesthetic crown lengthening utilizing a two-stage surgical protocol with a predictable step-by-step treatment. This allowed full control and minimal loss of attached gingiva, due to at least 2-3 mm of lengthening obtained from the process of recession.

#### Acknowledgements

The authors would like to thank Dr. Callie Hamman, Prosthodontist, private practice, Durbanville, Cape Town for the prosthodontic concept, stent and crowns of the Case Report. as well as Dental Technician: Ian Robertson, Bellville, Cape Town



## References

1. Prato GPP. Mucogingival deformities. *Ann. Periodontol.* 1999; 4(1):98-100.
2. Caton JG, Armitage G, Berglundh T, Chapple IL, Jepsen S, Kornman KS, et al. A new classification scheme for periodontal and peri-implant diseases and conditions—introduction and key changes from the 1999 classification. *J. Periodontol.* 2018; 89:S1-S8.
3. Miller JP. Concept of periodontal plastic surgery. *Practical periodontics and aesthetic dentistry: PPAD.* 1993; 5(5):15-20, 2; quiz 2.
4. Marzadori M, Stefanini M, Sangiorgi M, Mounssif I, Monaco C, Zucchelli G. Crown lengthening and restorative procedures in the esthetic zone. *Periodontol.* 2000. 2018; 77(1):84-92.
5. Januario AL, Barriviera M, Duarte WR. Soft tissue cone-beam computed tomography: A novel method for the measurement of gingival tissue and the dimensions of the dentogingival unit. *Journal of esthetic and restorative dentistry.* 2008; 20(6):366-73.
6. Mele M, Felice P, Sharma P, Mazzotti C, Bellone P, Zucchelli G. Esthetic treatment of altered passive eruption. *Periodontol.* 2000. 2018; 77(1):65-83.
7. Robbins JW. Differential diagnosis and treatment of excess gingival display. *Practical periodontics and aesthetic dentistry: PPAD.* 1999; 11(2):265-72; quiz 73.
8. Volchansky A, Cleaton-Jones P. Delayed passive eruption. A predisposing factor to vincent's infection. *J. Dent. Assoc. S. Afr.* 1974; 29:291-4.
9. Vanarsdall R, Coslet J, Weisgold A. Diagnosis and classification of delayed passive eruption of the dentogingival junction in the adult. *The Alpha Omegan.* 1977.
10. Alpilellueca F. Altered passive eruption (ape): A little-known clinical situation. *Med. Oral Patol. Oral Cir. Bucal.* 2011; 16(1):e100-4.
11. Jepsen S, Caton JG, Albandar JM, Bissada NF, Bouchard P, Cortellini P, et al. Periodontal manifestations of systemic diseases and developmental and acquired conditions: Consensus report of workgroup 3 of the 2017 world workshop on the classification of periodontal and peri-implant diseases and conditions. *J. Clin. Periodontol.* 2018; 45:S219-S29.
12. Schmidt JC, Sahrman P, Weiger R, Schmidlin PR, Walter C. Biologic width dimensions—a systematic review. *J. Clin. Periodontol.* 2013; 40(5):493-504.
13. Gargiulo AW, Wentz FM, Orban B. Dimensions and relations of the dentogingival junction in humans. *The Journal of Periodontology.* 1961; 32(3):261-7.
14. Perez JR, Smukler H, Nunn ME. Clinical dimensions of the supraosseous gingivae in healthy periodontium. *J. Periodontol.* 2008; 79(12):2267-72.
15. Cairo F, Graziani F, Franchi L, Defraia E, Pini Prato GP. Periodontal plastic surgery to improve aesthetics in patients with altered passive eruption/gummy smile: A case series study. *International journal of dentistry.* 2012; 2012.
16. Camargo PM, Melnick PR, Camargo L. Clinical crown lengthening in the esthetic zone. *Journal of the California Dental Association.* 2007; 35(7):487-98.
17. Rossi R, Benedetti R, Isabel Santos-Morales R. Treatment of altered passive eruption: Periodontal plastic surgery of the dentogingival junction. *European Journal of Esthetic Dentistry.* 2008; 3(3).
18. Dolt AH, Robbins JW. Altered passive eruption: An etiology of short clinical crowns. *QUINTESSENCE INTERNATIONAL-ENGLISH EDITION.* 1997; 28:363-74.
19. Batista Jr EL, Moreira CC, Batista FC, de Oliveira RR, Pereira KK. Altered passive eruption diagnosis and treatment: A cone beam computed tomography-based reappraisal of the condition. *J. Clin. Periodontol.* 2012; 39(11):1089-96.
20. Ribeiro FV, Hirata DY, Reis AF, Santos VR, Miranda TS, Faveri M, et al. Open-flap versus flapless esthetic crown lengthening: 12-month clinical outcomes of a randomized controlled clinical trial. *J. Periodontol.* 2014; 85(4):536-44.
21. Levine R, McGuire M. The diagnosis and treatment of the gummy smile. *Compendium of continuing education in dentistry (Jamesburg, NJ: 1995).* 1997; 18(8):757-62, 64; quiz 66.
22. Claman L, Alfaro MA, Mercado A. An interdisciplinary approach for improved esthetic results in the anterior maxilla. *The Journal of prosthetic dentistry.* 2003; 89(1):1-5.
23. Abou-Arraq RV, Souccar NM, editors. *Periodontal treatment of excessive gingival display.* *Semin. Orthod.*; 2013: Elsevier.
24. Pontoriero R, Carnevale G. Surgical crown lengthening: A 12-month clinical wound healing study. *J. Periodontol.* 2001; 72(7):841-8.
25. Pilalas I, Tsalikis L, Tatakis DN. Pre-restorative crown lengthening surgery outcomes: A systematic review. *J. Clin. Periodontol.* 2016; 43(12):1094-108.
26. Donnenfeld OW, Marks RM, Glickman I. The apically repositioned flap—a clinical study. *The Journal of Periodontology.* 1964; 35(5):381-7.
27. Tavtigian R. The height of the facial radicular alveolar crest following apically positioned flap operations. *J. Periodontol.* 1970; 41(7):412-8.
28. Garber DA, Salama MA. The aesthetic smile: Diagnosis and treatment. *Periodontol.* 2000. 1996; 11(1):18-28.
29. Magne P, Gallucci GO, Belser UC. Anatomic crown width/length ratios of unworn and worn maxillary teeth in white subjects. *The Journal of prosthetic dentistry.* 2003; 89(5):453-61.



# SteriWright

## Chlorine Dioxide Tablets



Switch & Save



THE ONLY DIFFERENCE YOU WILL NOTICE IS THE PRICE!

99.99% Kill Rate!

### SAFE. RAPID. EFFECTIVE.

- Cost effective & easy to use
- No bulky storage or heavy shipping
- Simply pop a tablet into water



### Disinfect Your Waterline And Aerosol

#### The Right Sterilant / Disinfectant For You!

Tailored to precise control rates, SteriWright is a controlled, sustained release tablet whereby Chlorine dioxide gas is released into the water.

#### High-Level Disinfectant

**30 seconds contact time is all it takes**

- Bactericidal
- Viricidal
- Mycobactericidal

Sporicidal in the presence of organic material in 2-3 minutes. 3 minute immersion time is all it takes!

#### Non-Corrosive\*

Can be used on metal instruments

[Click Here For More Information](#)

Product Code	Price Incl VAT	
WAY2000	R276.00	24 Tablets

#### 0.5g Tablet Pack size: 24 Tablets

#### WATERLINE TREATMENT

##### Directions of use:

1 x 0.5g tablet in 1 litre of water (5ppm) = Waterline treatment  
\*(small bottle)

2 x 0.5g tablet in 2 litre of water (5ppm) = Waterline treatment  
\*(large bottle)

\*When following the instructions correctly

**24 Tablets make 24 Litres of Waterline Treatment Solution**

ONLY  
R11,50  
PER LITRE

Product Code	Price Incl VAT	
WAY1000	R690.00	12 Tablets

#### 1.0g Tablet Pack size: 12 Tablets

#### DISINFECTANT/ STERILANT

##### Directions of use:

1 x 1.0g tablet in 5 litre of water (24ppm) = **Disinfectant\***  
**12 Tablets make 60 Litres of Disinfectant Solution**  
Walls & Floors, working surfaces, Chair Upholstry  
\*When following the instructions correctly

ONLY  
R11,50  
PER LITRE

2 x 1.0g tablet in 5 litre of water (48ppm) = **Sterilizer\***  
**12 Tablets make 30 Litres of Sterilizer Solution**  
\*When following the instructions correctly

ONLY  
R23,00  
PER LITRE

Prices include 15% VAT and are subject to Exchange Rate fluctuations. Terms & Conditions Apply. Discount cannot be used in conjunction with another discount. Pictures used may be for representation only. E&OE. While Stocks Last. Offer ends 31 August 2020

# The efficacy of disinfectants in the decontamination of dental unit water lines: an *in vitro* laboratory study

Mrudula Patel<sup>1</sup>, Jainisha Desai<sup>1</sup> and Peter C Owen<sup>2</sup>

## Abstract

**Objectives/aims:** This *in vitro* laboratory study compared the efficacy of water, sodium percarbonate (SPC) and chlorine dioxide (ClO<sub>2</sub>) solutions in the disinfection of dental unit water lines (DUWLs).

**Materials and methods:** New DUWL tubes were cut, split open, and mono-culture and mixed-culture biofilms of *Staphylococcus aureus*, *Enterococcus faecalis* and *Streptococcus mutans* were grown. Harvested biofilms from the sectioned DUWL tubes were exposed to sterile distilled water, SPC or 5 and 10 p.p.m. ClO<sub>2</sub> in both a stationary phase and through a constant flow. Bacterial counts were compared using the Kruskal–Wallis nonparametric rank test.

**Results:** In the mono-culture biofilms, SPC, 5 and 10 p.p.m. ClO<sub>2</sub> significantly reduced all the test organisms (P<0.01). However, no significant difference was found between SPC and ClO<sub>2</sub>. In the mixed-culture biofilms exposed to disinfectant without flow, ClO<sub>2</sub> significantly reduced the biofilm (P = 0.02) compared with water and SPC. Similarly, in the constant flow study, ClO<sub>2</sub> proved to be superior to water.

**Conclusion:** At low concentrations, ClO<sub>2</sub> with and without flow significantly reduced the mixed-culture biofilm grown *in vitro* on the sections of the DUWL tubes. Therefore, it has the potential to be used in the patient treatment water, as it is potable at these concentrations, and to decontaminate and limit the biofilm formation in the water lines.

BDJOpen (2016) 2, 16003; doi:10.1038/bdjopen.2016.3; published online 26 February 2016

## Introduction

The dental chair unit contains water lines that supply water from a reservoir or municipal supply to the handpieces, the triplex air/water syringe and spittoon. These lines vary in thickness and material construction, and become contaminated with environmental microorganisms, pathogens and opportunistic pathogens. These bacteria create biofilms on the tube walls that provide nutrients and protection to one another.<sup>1</sup> The flow of water in the dental unit water lines (DUWLs) generates shear forces that detach pieces of biofilm and planktonic forms of microorganisms and their endotoxins. Contamination of DUWLs therefore becomes a potential source of infection particularly for immunocompromised patients and is hazardous for both patients and dental health-care personnel. The source of contamination is tap water or retrograde aspiration of oral secretions by handpieces.<sup>2,3</sup>

Among the many physical methods that can improve the microbiological quality of DUWL output water, the use of disinfectant is the most efficacious means of ensuring decontamination. Chemicals such as sodium percarbonate (SPC), hydrogen peroxide and sodium perborate have been tested and they have shown variable efficacy<sup>4</sup> mainly owing to the different test concentrations and the type of interventions. Most studies

<sup>1</sup> Division of Oral Microbiology, Department of Oral Biological Sciences, School of Oral Health Sciences, Faculty of Health Sciences, University of The Witwatersrand, Johannesburg, South Africa

<sup>2</sup> Department of Oral Rehabilitation, School of Oral Health Sciences, Faculty of Health Sciences, University of The Witwatersrand, Johannesburg, South Africa.

### Correspondence:

M Patel (mrudula.patel@wits.ac.za)

**Table 1. Effect of water, SPC and ClO<sub>2</sub> on the biofilms of Staphylococcus aureus, Enterococcus faecalis and Streptococcus mutans on the dental unit waterline yellow, white and grey tubing**

Experiments	Mean ± s.d. (bacterial counts in c.f.u./ml)				
	Control	H <sub>2</sub> O	SPC	5 p.p.m. ClO <sub>2</sub>	10 p.p.m. ClO <sub>2</sub>
Stationary <sup>a</sup> (n = 27)	8.3 × 10 <sup>6</sup> ± 1.8 × 10 <sup>7</sup>	3.4 × 10 <sup>5</sup> ± 8.8 × 10 <sup>5</sup>	5.1 × 10 <sup>4</sup> ± 8.5 × 10 <sup>4</sup>	7 ± 38	0 ± 0
Stationary <sup>b</sup> (n = 27)	7.0 × 10 <sup>5</sup> ± 1.7 × 10 <sup>6</sup>	6.8 × 10 <sup>4</sup> ± 2.3 × 10 <sup>5</sup>	1.8 × 10 <sup>4</sup> ± 3.6 × 10 <sup>4</sup>	1.9 × 10 <sup>2</sup> ± 5.6 × 10 <sup>2</sup>	65 ± 1.5 × 10 <sup>2</sup>
Pump study <sup>c</sup> (n = 15)	5.7 × 10 <sup>5</sup> ± 6.6 × 10 <sup>5</sup>	4.2 × 10 <sup>3</sup> ± 6.4 × 10 <sup>3</sup>	4.5 × 10 <sup>2</sup> ± 7.6 × 10 <sup>2</sup>	0 ± 0	0 ± 0

Abbreviations: ClO<sub>2</sub>, chlorine dioxide; SPC, sodium percarbonate.

<sup>a</sup>Mono-culture biofilm on each type of tubing repeated three times.

<sup>b</sup>Mixed-culture biofilm on each type of tubing repeated three times (bacterial counts obtained for each organism).

<sup>c</sup>Mixed-culture biofilm on the grey tubing only repeated five times (bacterial counts obtained for each organism).

have tested the efficacy of disinfectants as flushing solutions with intermediate use of a normal water supply. However, disinfectants may only be effective when the development of biofilm is minimised and the intermittent exposure of normal water is also eliminated. Disinfectants used in DUWLs have to not only eliminate heterotrophic bacteria but also common pathogens. In addition, the disinfectant has to be safe and biocompatible. This study compared the efficacy of a commonly used product, SPC and newly available product, chlorine dioxide (ClO<sub>2</sub>), in the disinfection of DUWLs and their possible use during patient treatment.

## Materials and methods

### Cultures and inoculums

*Staphylococcus aureus* ATCC 2943, *Enterococcus faecalis* ATCC29121 and a clinical strain of *Streptococcus mutans* were used in the study. Ethical clearance was obtained from the Human Research Ethics committee of The University of Witwatersrand, Johannesburg. Cultures were grown on blood agar plates, and inoculums were prepared to obtain an optical density of 0.5 at 405nm (~10<sup>6</sup>–10<sup>7</sup> c.f.u./ml).

### Test products

These products are commercially available and the solutions were prepared according to the manufacturer's instructions. The SPC tablet (SPC, N-alkyl dimethyl benzyl ammonium chloride, N-alkyl dimethyl ethylbenzyl ammonium chloride and silver nitrate) is known as A-dec ICX (A-dec, Newberg, OR, USA), and 5 and 10 p.p.m. of slow release ClO<sub>2</sub> tablets known as SteriWright (Wright Millners, Johannesburg, South Africa). Sterile distilled water was used as a control to represent flushing.

### Standardisation of technique

Three-centimetre segments of standard-sized yellow (water

supply to spittoon), white (to auxiliary devices) and grey (to the air turbines) new DUWL tubes (A-dec) were cut and slit into two halves. The tubes were decontaminated with 70% alcohol and by placing them under ultraviolet light for 48h. To grow biofilms, the tubes were placed in Brain Heart Infusion broth, inoculated with 100µl of the appropriate culture inoculum and incubated at 37°C for 72h. They were rinsed with sterile distilled water to remove residues of media and unattached bacterial cells, and the biofilms were then scraped off with swabs. The swabs and the tubes were placed in 5ml sterile distilled water, vortexed, and bacterial counts were obtained on blood agar plates using the serial dilution technique. These experiments were repeated five times, and the results were analysed using a one-sample t-test.

### Efficacy of disinfectants - in vitro study

For the mono-culture experiments, biofilms were grown on five sets of the yellow, white and grey tubes. One set of tubes with biofilms were cultured for the quantity of bacteria using the serial dilution technique (control count). The other four sets were allowed to stand in either of the test chemicals or water for 24h. They were then removed, and the standardised procedure described above was followed to obtain the bacterial counts.

For the mixed-culture experiments, biofilms were grown using all three cultures of bacteria. In this case, the bacterial counts were obtained using Baird-Parker agar (*S. aureus*), MacConkey agar (*E. faecalis*) and Mutans Bacitracin agar plates (*S. mutans*).

For both the experiments, the percentage kill was calculated using control counts of unexposed tubes using the formula:

$$(\text{control counts} - \text{test counts} / \text{control counts}) \times 100 = \text{percentage kill.}$$

All the experiments were repeated three times. These data were compared using Kruskal-Wallis nonparametric rank tests.

### *Efficacy of disinfectants—simulation study*

A fish-tank pump was used to simulate the dental unit. This pump had the capacity to pump 400 litres of water per hour. This experiment was repeated using only the grey tubes. A 25-cm segment of tube was cut, fitted onto a pump and submerged into a beaker containing 70% alcohol. The pump was switched on for 2h to decontaminate the pump and tube. The tube was removed and placed under ultraviolet light. After 24h, the pump was removed from the alcohol, drained thoroughly, air dried and the decontaminated tube was reconnected. This assembled system was submerged into 650ml of Brain Heart Infusion broth. The media were inoculated with 1ml of mixed-culture inoculum, incubated for 72h with a change of medium every day. The pump was switched on for 8h a day and the rest of the time the tubes were left in the same medium. A 3cm segment was cut, wiped with 70% alcohol and split open using a sterile scalpel. Biofilms from the inner walls of the tube were then scraped off with swabs. The swabs and the tubes were placed in 5ml sterile distilled water, vortexed and bacterial counts were obtained using Baird–Parker agar (*S. aureus*), MacConkey agar (*E. faecalis*) and Mutans Bacitracin agar plates (*S. mutans*). The bacterial counts were taken as control counts. The rest of the tubing was also wiped with 70% alcohol, reconnected to a decontaminated pump, submerged into sterile distilled water, switched on for 8h and kept in the same sterile distilled water at room temperature for 24h. Five 3-cm segments were cut, the outer surface was decontaminated and the biofilm from the inner wall was cultured. Similarly, 72-h biofilms were exposed to SPC, and 5 and 10 p.p.m.  $\text{ClO}_2$  solutions. These experiments were repeated five times for each disinfectant. The percentage kill data for each organism were pooled to provide 15 readings per disinfectant, which were compared using Kruskal–Wallis nonparametric rank tests.

## Results

### *Standardisation of technique*

The mean biofilm counts of *S. aureus*, *E. faecalis* and *S. mutans* was  $1.3 \times 10^7$ ,  $2.6 \times 10^7$  and  $1.0 \times 10^5$  per tube. No significant difference in the bacterial counts between the repeats per tubes and between all the tubes was found (*S. aureus*:  $P = 0.06$ , *E. faecalis*:  $P = 0.15$ , *S. mutans*:  $P = 0.5$ ). Therefore, it was determined that the technique was standardised. However, the adherence ability of *S. mutans* was found to be weaker than *S. aureus* and *E. faecalis*. In addition, the adherence ability of the test organisms was not tube dependent.

When the efficacy of the disinfectants was compared between the tubes no significant difference in the % kill was found ( $P = 0.6$ ). When the efficacy of the disinfectants was compared between the test organisms, no significant difference in the % kill was found ( $P = 0.4$ ). Therefore, all the results were combined (% kill for the all the tubes and all the organisms,  $n = 27$ ) and the efficacy of disinfectants were compared.

### *Efficacy of disinfectants*

The bacterial counts are shown in the Table 1, which shows the mean number of challenged organisms and the reduction in the number of organisms. Continuous pumping of  $\text{ClO}_2$  showed complete removal of mixed-culture biofilm. For each test, these bacterial counts were converted into % kill. When the disinfectants were compared using % kill, the results (Figure 1) showed that in the mono-culture biofilm experiments, SPC, 5 p.p.m.  $\text{ClO}_2$  and 10 p.p.m.  $\text{ClO}_2$  had significantly high ( $P < 0.01$ ) % kill compared with water. However, there was no difference in the % kill between the test disinfectants.

In the mixed-culture biofilm experiments, the test disinfectants had significantly higher % kill compared with water (Figure 2). Both concentrations of  $\text{ClO}_2$  also had significantly higher % kill compared with SPC ( $P = 0.02$ ) and no difference in the % kill of the two concentrations of  $\text{ClO}_2$ .

In the mixed-culture biofilm pump experiments (Figure 3), SPC did not prove any different from water ( $P = 0.1$ ). However, both the concentrations of  $\text{ClO}_2$  proved to be better than water ( $P = 0.01$ ).

## Discussion

Although data related to transmission of infections due to DUWL are under reported, it is still a threat especially to immunocompromised patients.<sup>4</sup> This study has shown that the test chemicals can significantly reduce the biofilms compared with water, which suggest that flushing the unit with water alone will not be adequate.<sup>3,5,6</sup> Many products containing disinfectants are available and they have been shown to have variable efficacy purely because of the unique nature of the DUWL system.<sup>4</sup> It becomes contaminated with different types of bacteria, which forms highly structured microbial communities that are difficult to remove.

This study has shown that biofilm containing mixed flora could not be eliminated with SPC (Table 1). Nevertheless, SPC performed slightly better when the test organisms were challenged individually and used in the pump system. It has been suggested that sodium perborate and

## RVG 5200 Sensor

*The Faster, Simpler  
Way To Raise  
Your Performance*

- + Sophisticated yet simple
- + Easier workflow
- + Rugged and reliable
- + Intuitive and easy to install

**R61 900**  
INCL VAT

## CS 2100 X-Ray

*Intraoral X-Ray System*

Obtain sharp, high contrast images quickly and easily with this affordable high-frequency generator - ideal for your basic intraoral needs.

**R44 600**  
INCL VAT



## REDEFINE THE WAY YOU COMMUNICATE

## CS 1200 Intraoral Camera

*Case Acceptance Starts With An Image*

Combining high-quality images, ease of use and multiple connections for easy sharing, the CS 1200 is the perfect entry level intraoral camera option. It features an auto-adjustable, 6-LED lighting system and a generous 3mm-25mm focus range.

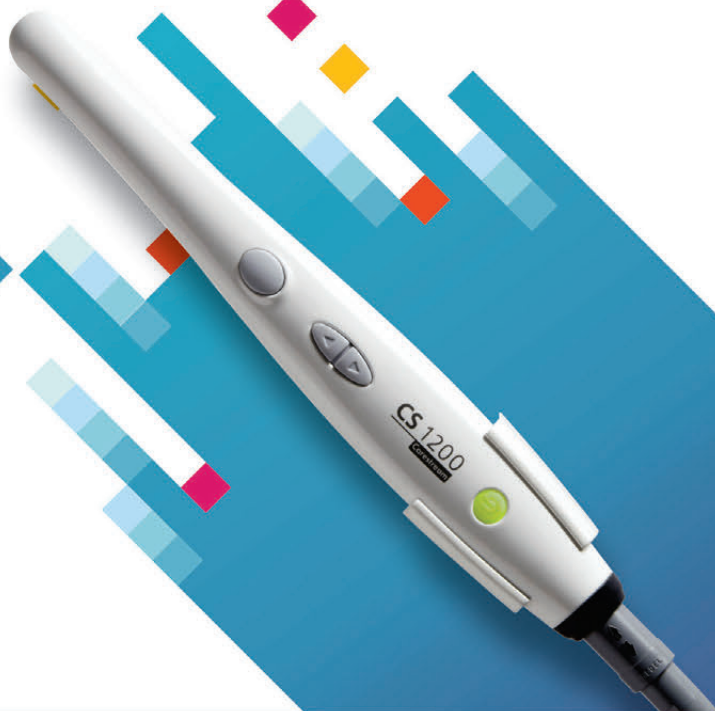- Stores up to 300 images
- Eliminates the need for memory cards or computers in each operatory
  - Supports PC, video and analog displays

**NOW ONLY**

**R17 449**  
INCL VAT

Includes:  
Pack Of 100  
Hygienic Sleeves  
Valued At R820

ZK06559884A



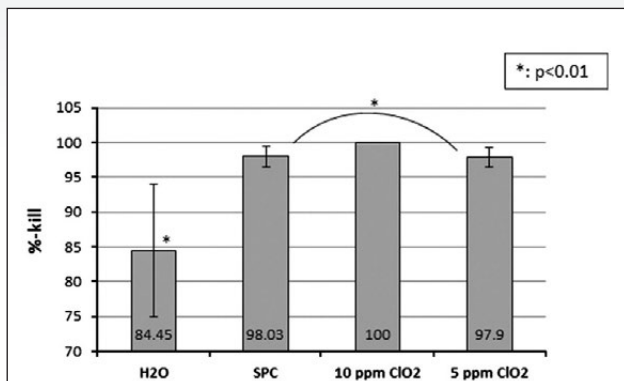


Figure 1: Comparison of disinfectants in the disinfection of yellow, white and grey tubes contaminated individually (mono-culture) with *S. aureus*, *E. faecalis* and *S. mutans* where n = 27.

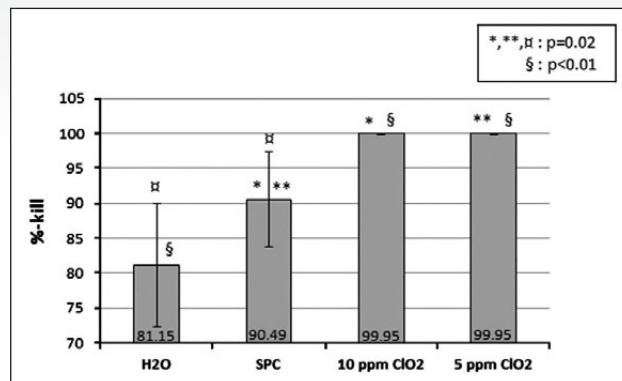


Figure 2: Comparison of disinfectants in the disinfection of yellow, white and grey tubes contaminated with mixed-cultures of *S. aureus*, *E. faecalis* and *S. mutans* in an in vitro stationary environment. Bacterial counts for each organism were pooled where n = 27.

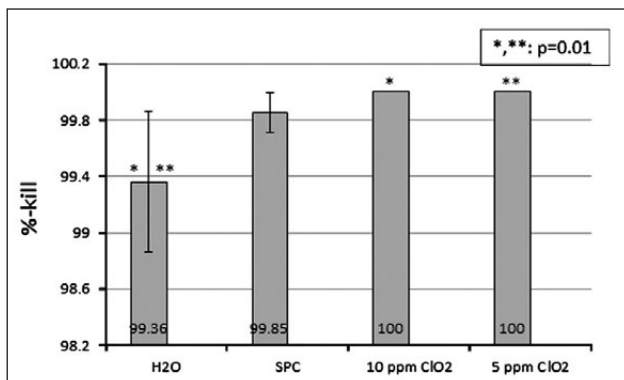


Figure 3: Comparison of disinfectants in the disinfection of simulation pump-attached grey tubes contaminated with mixed-cultures of *S. aureus*, *E. faecalis* and *S. mutans*. Bacterial counts for each organism were pooled where n = 15.

sodium carbonate, which are similar to SPC, generally have variable efficacy.<sup>4</sup> Similarly, the test product SPC that contained SPC, surfactants with biocidal activities and antimicrobial compound silver nitrate also displayed variable efficacy. In a study, sodium carbonate together with sodium carbonate peroxy hydrate has shown inconsistent results at different time intervals.<sup>6</sup> It has been reported that SPC can efficiently eliminate heterotrophic bacteria and produce water containing bacterial counts within the permitted quantity of <math>500\text{ c.f.u./ml}</math><sup>7-9</sup> and yet we failed to show this phenomenon. Although the efficacy of all the disinfectants improved in the pump study compared with the stationary experiments, SPC did not prove to be better than water. On the other hand, ClO<sub>2</sub> consistently showed better results than water.

As the results in our study have shown, Environmental Protection Agency (EPA) approved ClO<sub>2</sub> is an excellent biocide and its use in DUWL has been recommended.<sup>1,6</sup> However, Smith et al.<sup>10</sup> reported that up to 50 p.p.m. ClO<sub>2</sub> did not consistently provide potable quality water from an intermittently treated DUWL, although it reduced the total viable bacteria. In contrast, 3 p.p.m. ClO<sub>2</sub> was reported to produce water with <math><500\text{ c.f.u./ml}</math> of heterotrophic bacterial counts.<sup>11</sup> Similarly, the use of ClO<sub>2</sub> (unknown concentration) in DUWLs was shown to maintain <math><10\text{ c.f.u./ml}</math> of bacteria for up to 11 days.<sup>6</sup> This suggests that to achieve a significant beneficial effect, ClO<sub>2</sub> should be used continuously and not intermittently.<sup>5,6,12</sup> Continuous use of ClO<sub>2</sub> in the DUWLs may prevent biofilm formation by reducing the number of bacteria that will also improve the quality of water.

Regular use of disinfectant may also create other problems particularly with chlorinated compounds as they are considered corrosive. ClO<sub>2</sub> is reported to cause no corrosion at neutral pH, but can cause corrosion at an acidic pH of 2–3 and at very high concentrations.<sup>13</sup> It is extremely unlikely that such an acidic pH would ever occur in DUWLs, which suggests that corrosion may not be a problem. It has been shown that the maintenance of the DUWL system can be achieved either by flushing with a disinfectant regularly or by adding a low concentration of disinfectant to the treatment water. However, the low concentrations of SPC studied here were ineffective in reducing the bacterial counts to <math><100</math> and even <math><200\text{ c.f.u./ml}</math> as recommended by European Union and American Dental Association, respectively.<sup>14,15</sup> This study has shown that continuous use

# Roland

## Cost to produce a crown?

Machine: DWX-4 Henry Schein  
The Dental Warehouse  
Material: Vita Enamic  
Machine Price: **R138 474.51** ExVAT\*  
Suitable Materials : Wax, PMMA  
Zirconia & Compsite Resins

**Total Machine time: 26 min 6 sec**

Finance Cost : R7.50 (391) to R731.28 (4) \*\*  
**Total per Crown: R1297.64\*\* (4)**  
Material Cost: R380.00  
Tool Cost : R189.92

\*\* Finance cost = Monthly instalment @9.5%  
on a 60 month contract and a presumed  
production of only 4 crowns a month.  
Machine Capacity 391 crowns per month  
( 22days, 8 hours day.)



**Total Machine time: 23 min 13 sec**

Finance Cost: R6.12 (1800) to R2 770.00 (4) \*\*  
**Total per Crown: R3 315.15\*\* (4)**  
Material Cost: R380.00  
Tool Cost : R165.15

\*\* Finance cost = Monthly instalment @9.5%  
on a 60 month contract and a presumed  
production of only 4 crowns a month.  
Machine capacity 1800 crowns per month.  
(24 by 7 days), fully automated disk changer  
with remote monitoring.

Machine: DXW-52DCi Henry Schein  
The Dental Warehouse  
Material: Vita Enamic  
Machine Price: **R524 524.66** ExVAT\*  
Suitable Materials : PEEK, Pectin,Wax,  
PMMA, Zirconia,Gypsum, Sinter Metals

**Total Machine time: 23 min 8 sec**

Finance Cost: R18.52 (440) to R2 049.00 (4)  
**Total per Crown: R2 598.93\*\* (4)**  
Material Cost: R380.00  
Tool Cost : R169.93

\*\* Finance cost = Monthly instalment @9.5%  
on a 60 month contract and a presumed  
production of only 4 crowns a month.  
Machine Capacity 440 Crowns per month  
(22days,8 hours a day)

Machine: DXW-52D Henry Schein  
The Dental Warehouse  
Material: Vita Enamic  
Machine Price: **R388 004.55** ExVAT\*  
Suitable Materials : PEEK, Pectin,Wax,  
PMMA, Zirconia,Gypsum, Sinter Metals



**Total Machine time: 29 min 53 sec**

Finance Cost: R26.92 (252) to R1 706.25 (4)  
**Total per Crown: R2 297.09\*\* (4)**  
Material Cost: R380.00  
Tool Cost : R210.84

\*\* Finance cost = Monthly instalment  
@9.5% on a 60 month contract and a  
presumed production of only 4 crowns a  
month. Machine Capacity 252 crowns per  
month (22days, 8hours day)

Machine: DXW-4W Henry Schein  
The Dental Warehouse  
Material: IPS e.max  
Machine Price: **R323 107.19** ExVAT\*  
Suitable materials, Composite Resins  
and Galss Ceramics'.



**Question is - Can you afford not to move?**

**DGSHAPE**

\*Subject to stock on hand, special pricing deadlines & minimal forex fluctuations (2%), failing which exchange rate variations or list pricing could be applicable.

imagine.dental

You are - I am - We are, team...

www.rolanddg.co.za | sales@rolanddg.co.za  
0800ROLAND (76 5263) | +27(11) 875 9300

**Roland**





of 5 p.p.m. concentration of  $\text{ClO}_2$  was effective in killing pathogenic bacteria present in the form of biofilm on the DUWLs and this concentration is acceptable in the treatment water. EPA and Centers for Disease Control and Prevention (CDC) allow 8 p.p.m.  $\text{ClO}_2$  in drinking water.<sup>16</sup> Therefore, 5 p.p.m.  $\text{ClO}_2$  may be safely used to continuously disinfect the DUWL tubes and water during dental operations. Addition of disinfectant into the treatment water is easy and less time-consuming.

One of the limitations of this study is that actual dental chair units were not used. However, an artificial pump system was created to simulate the DUWL system, as also shown by Spratt et al.<sup>17</sup> In this simulated system, mixed-culture biofilms of three common pathogens were grown and decontaminated successfully, validating the results. However, further research is required to test this product in the DUWLs to establish its *in situ* and long-term efficacy. One of the limitations of *in situ* studies, however, is that the output water is usually tested, which contains only a fraction of bacteria detached from the biofilm. The number of challenged bacteria is important, and in *in vitro* studies at least known quantities of bacteria including pathogens can be challenged, which is perhaps more representative of the clinical setting.

## Conclusion

This study has shown that 5 p.p.m.  $\text{ClO}_2$  can kill 99.95% of mixed-culture biofilm grown *in vitro* on the sections of the DUWL tubing and it is potable at this concentration, therefore has the potential to be used as a disinfectant in these lines and to be used in the treatment water. Further research is required to assess the DUWL disinfectant efficacy of  $\text{ClO}_2$  in a normal clinical setting and to ascertain whether it might result in adverse corrosion of dental surgery equipment.

## Acknowledgements

We thank Thamsanqa Ngabaza for some of the experimental work.

## Competing interests

The authors declare no conflict of interest.

## References

1. Walker J, Marsh P. Microbial biofilm formation in DUWS and their control using disinfectants. *J Dent* 2007; 35:721–730.
2. Atlas R, Williams J, Huntington M. Legionella contamination of dental unit waters. *Appl Environ Microbiol* 1995; 61: 1208–1213.
3. Pankhurst C, Coulter W. Do contaminated dental unit waterlines pose a risk of infection? *J Dent* 2007; 35:712–720.
4. O'Donnell M, Boyle M, Russell R, Coleman DC. Management of dental unit biofilms in the 21st century. *Future Microbiol* 2011; 6:

1209–1226.

5. Wirthlin MR, Marshall GW Jr. Evaluation of ultrasonic scaling unit waterline contamination after use of chlorine dioxide mouthrinse lavage. *J Periodontol* 2001; 72: 401–410.

6. Wirthlin MR, Marshall GW Jr, Rowland RW. Formation and decontamination of biofilms in dental unit waterlines. *J Periodontol* 2003; 74: 1595–1609.

7. Meiller TF, Kelley JJ, Zhang M, DePaola LG. Efficacy of A-dec's ICX dental unit waterline treatment solution in the prevention and treatment of microbial contamination in dental units. *J Clin Dent* 2004; 15:17–21.

8. McDowell JW, Paulson DS, Mitchell JA. A simulated-use evaluation of a strategy

9. American Dental Association. ADA statement on Dental Unit Waterlines, Oral Health Topics, American Dental Association (2015). <http://www.ada.org/en/member-center/oralhealthtopics/dental-unit-waterlines>. Accessed 14 December 2015.

10. Smith AJ, Bagg J, Hood J. Use of chlorine dioxide to disinfect dental unit waterlines. *J Hosp Infect* 2001; 49:285–288.

11. Bansal R, Puttaiah R, Harris R, Reddy A. Evaluation of two methods in controlling dental treatment water contamination. *J Contemp Dent Pract* 2011; 12:73–83.

12. Dallolio L, Scuderi A, Rini MS, Valente S, Farruggia P, Sabattini MA et al. Effect of different disinfection protocols on microbial and biofilm contamination of dental unit waterlines in community dental practices. *Int J Environ Res Public Health* 2014; 11: 2064–2076.

13. Bohner HF, Bradley RL. Corrosivity of chlorine dioxide used as sanitizer in ultra-filtration systems. *J Dairy Sci* 1991; 74: 3348–3352.

14. Anonymous. ADA statement on dental unit water lines. *J Am Dent Assoc* 1996; 127:185–186.

15. European Union. Council directive 98/83/EC of 3 November 1998 on the quality of water intended for human consumption. *Off J Eur Commun* 1998; L330:32–54.

16. U.S. Environmental Protection Agency. National Primary Drinking water regulation. U.S. EPA, Office of Water (2015). <http://water.epa.gov/drink/contaminants/index.cfm>. Accessed 12 December 2015.

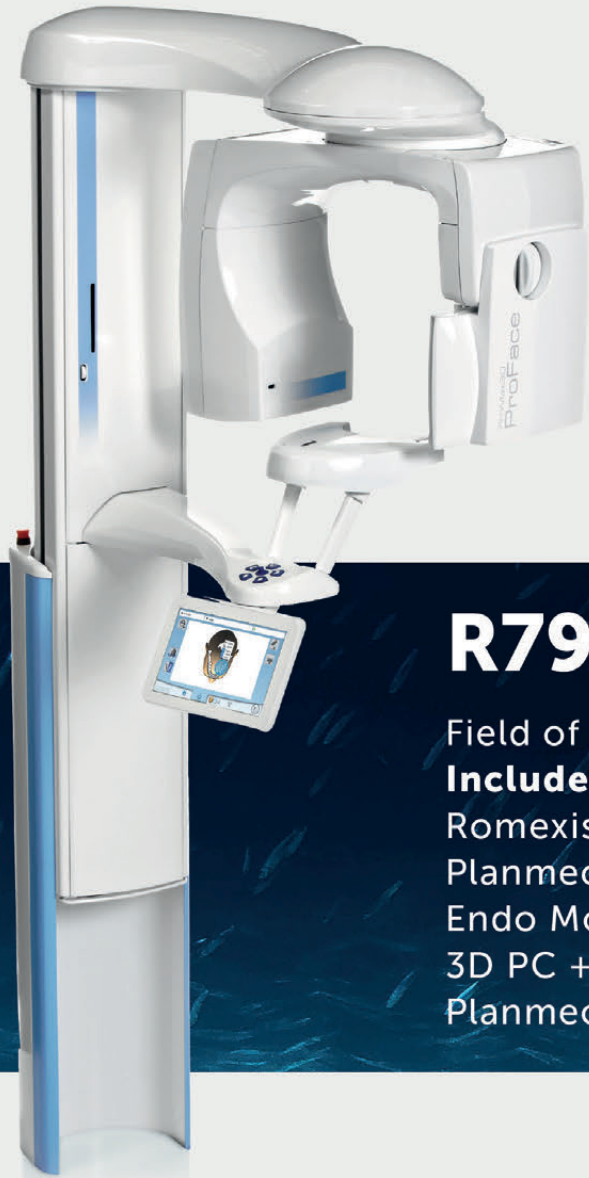17. Spratt DA, Latif J, Montebugnoli LL, Wilson M. *In vitro* modelling of dental water line contamination and decontamination. *FEMS Microbiol Lett* 2004; 235: 363–367.

Patel M, Desai J, Owen PC. The efficacy of disinfectants in the decontamination of dental unit water lines: an *in vitro* laboratory study. *BDJ Open* 2016; 2: 16003



This work is licensed under a Creative Commons Attribution 4.0 International License. The images or other third party material in this article are included in the article's Creative Commons license, unless indicated otherwise in the credit line; if the material is not included under the Creative Commons license, users will need to obtain permission from the license holder to reproduce the material. To view a copy of this license, visit <http://creativecommons.org/licenses/by/4.0/>





# Planmeca ProMax<sup>®</sup> 3D Classic

Extended Excellence

**R795 000** Incl VAT

Field of view 80 x 80mm (upgradeable to 110 x 80mm)

**Includes the following:**

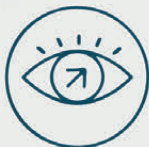Romexis 6 Implant Planning Software

Planmeca CALM (Latent movement correction algorithm)

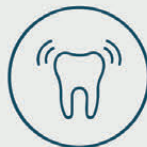Endo Mode - 75um Voxel size

3D PC + Medical Grade Monitor

Planmeca Ultra Low Dose protocol



**Premium range quality**



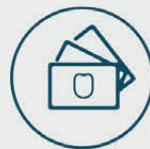**Automatic patient movement correction**



**Ultra low dose imaging**



**Comprehensive imaging software**



**Versatile imaging options**

**ORDER YOURS TODAY!**

Adriaan van der Spuy | +27 76 821 6239

adriaan.vds@planmeca.com | [www.planmeca.com](http://www.planmeca.com)

# All-ceramic single-tooth restorations for treating damaged dental enamel: Long-term results in patients with and without amelogenesis imperfecta

Andrea Klink, Fabian Hüttig and Martin Groten

## Introduction

Teeth that have been affected by extensive wear or a genetic disorder can be successfully restored with adhesively bonded all-ceramic restorations. The following article summarizes the outcomes of a series of complex clinical cases. Two different groups of patients require the rehabilitation of impaired full dentitions:

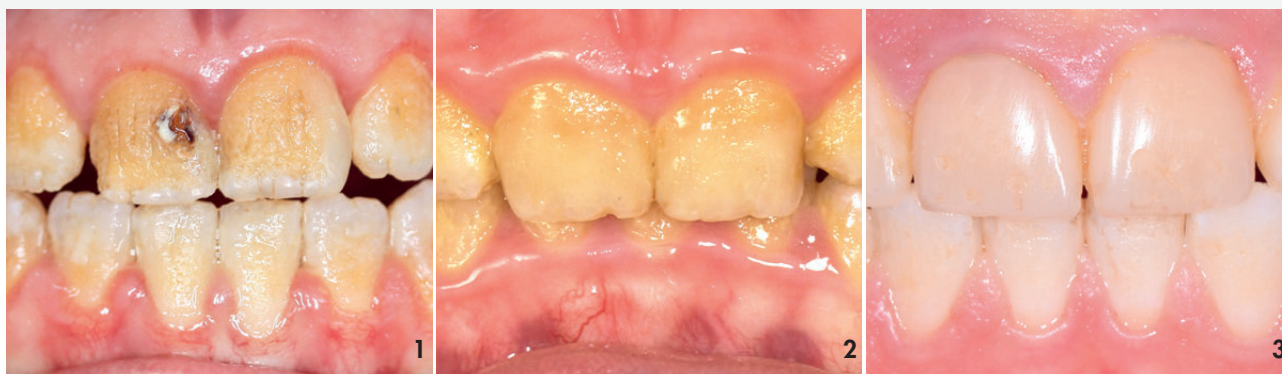1. Patients whose teeth show extensive erosion, abrasion or attrition caused by their diet (e.g. consumption of energy drinks) and/or overuse (e.g. grinding)
2. Patients who have a genetic disorder that affects the tooth structure and the composition of the tooth enamel (e.g. amelogenesis imperfecta, AI) (Figures 1 to 3)

Patients in the first group usually start experiencing problems (e.g. pain and compromised esthetics) in their forties and fifties. The teeth become shorter and look yellowish; parts of the existing tooth structure become fragile and a loss of vertical dimension occurs. Patients with a genetic enamel defect generally require treatment when they are in their teens. Today's advanced all-ceramic and adhesive systems allow minimally invasive tooth preparation and they produce durable, functional and esthetic restorations.

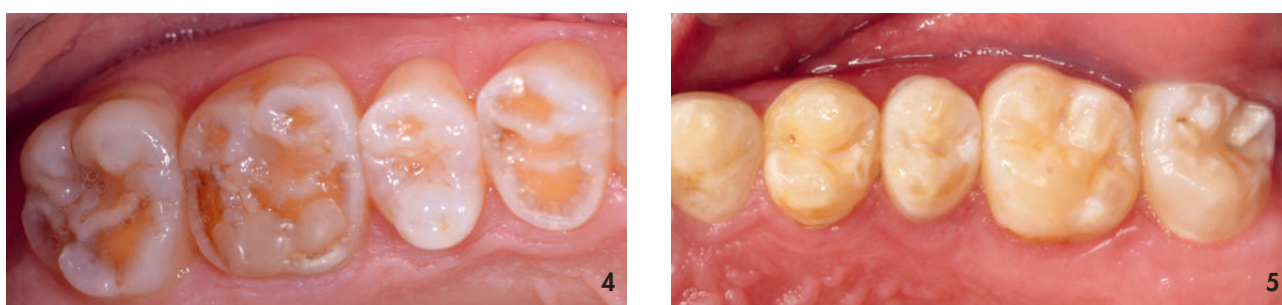
Before treating patients with dental erosion, it is important to obtain their full medical history (e.g. bulimia nervosa or reflux disease) and find out about their eating habits. If possible their general practitioner should also be involved in the treatment. If the patient is experiencing functional problems, these should be addressed in a pre-treatment phase. In patients with a congenital defect of the tooth structure, a thorough clinical and radiological examination is of utmost importance, since in addition to the enamel defects (Figures 4 and 5), these individuals may also suffer from follicular cysts, abnormal tooth eruption, retained or impacted teeth, an open bite or dental pulp calcification (Figures 6 to 8). The disorder is furthermore associated with gingival and periodontal disease. This must be taken into consideration in the preliminary treatment of hypomineralized and hypocalcified enamel. Depending on the severity of the impairment of the enamel formation, an adhesive bond may be much weaker than it would be on healthy enamel. As a result, the adhesive bond must be generated in the dentin in most cases (Figure. 9).

Correspondence address:  
Dr Andrea Klink, Dr Fabian  
Hüttig, PD Dr Martin Groten  
Universitätsklinikum Tübingen  
(Universitätsklinik für Zahn-, Mund-  
und Kieferheilkunde / Center for  
Dentistry, Oral Medicine, and  
Maxillofacial Surgery)  
Oslanderstraße 2-8  
72076 Tübingen/Germany

andrea.klink@med.uni-tuebingen.de  
www.medizin.uni-tuebingen.de



Figures 1 - 3: Three phenotypes of the autosomal dominant inherited amelogenesis imperfecta in the anterior teeth of three sisters



Figures 4 & 5: The posterior teeth of AI patients also show different types of enamel defects. The enamel layer may be missing entirely.

At present, no guidelines or scientific reports of an evidence-based protocol are available for the treatment of patients with AI. In a long-term study conducted at the Tübingen University Hospital, we identified the type of complications which could arise with adhesively placed all-ceramic single-tooth restorations in the mentioned patient groups.

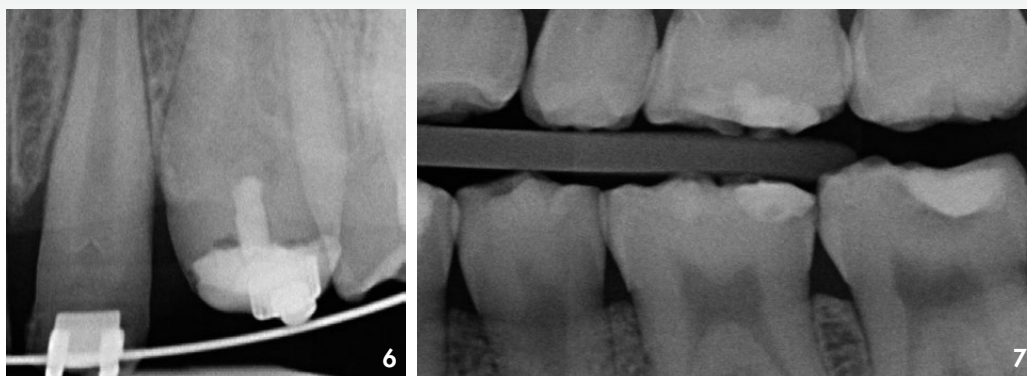
#### Data base and examinations

For our study, we selected patients who regularly attended the recall appointments and who had been treated as follows:

Single-tooth restorations (crowns, partial crowns) made of silicate (Si) or lithium disilicate ceramic (LiDi) had been placed with an adhesive composite. Table 1 contains a list

Table 1 — Overview of materials used

Group	Name	Manufacturer	Other characteristics
Silicate ceramic	Celay (feldspathic ceramic)	Vita Zahnfabrik, Bad Säckingen, Germany	Copy milling, predecessor product of Vitablocs Mark II
	IPS Empress 1	Ivoclar Vivadent, Schaan, Liechtenstein	Leucite-reinforced silicate ceramic
Lithium disilicate ceramic	IPS Empress 2	Ivoclar Vivadent, Schaan, Liechtenstein	Lithium disilicate ceramic of the 1 <sup>st</sup> generation
	IPS e.max Press		Lithium disilicate ceramic of the 2 <sup>nd</sup> generation: Only the vestibular aspect of anterior restorations was veneered (IPS e.max Ceram – Ivoclar Vivadent): cut-back technique
Veneered zirconium oxide frameworks	Ceramill Zolid	Amann Girrbach, Pforzheim, Germany	Zirconium oxide frameworks veneered with IPS e.max Ceram (Ivoclar Vivadent) Zirconium oxide frameworks veneered with Cercon Ceram Kiss (Degudent) Zirconium oxide frameworks veneered with Cercon Ceram Kiss (Degudent)
	Vitablocs YZ	Vita Zahnfabrik, Bad Säckingen, Germany	
	Cercon	DeguDent, Hanau, Germany	



Figures 6 & 7: The entire crown of tooth 23 is missing (Fig. 6). The bitewing radiograph (Fig. 7) shows normally formed dentin: parts of it are bare, while other parts are covered with only a thin layer of enamel.

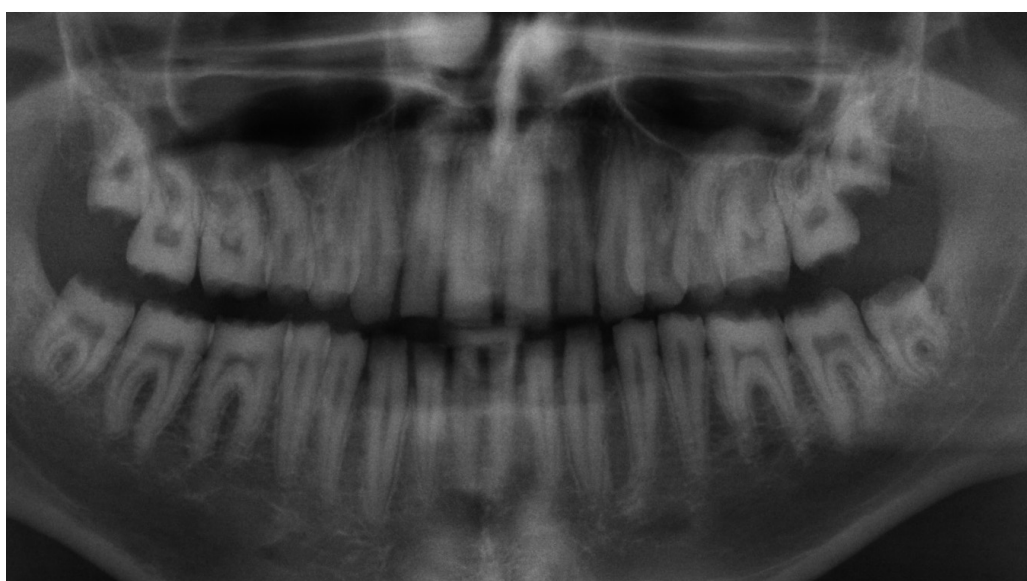

Figure 8: The panoramic radiograph shows a severe form of AI. None of the teeth show any enamel coverage.

of the materials used.

The patients had lost a maximum of four teeth. The missing teeth were replaced with not more than a three-unit all-ceramic bridge or a single-tooth implant with an all-ceramic crown. The patients whose vertical dimension of occlusion had to be opened by more than 4 mm were given an occlusal appliance which they had to wear 24/7 for at least four months before the treatment. The rapid developments in the field of all-ceramic materials continue to open up new treatment modalities. Initially, however, feldspathic and leucite-reinforced silicate ceramics were copy-milled to produce esthetic single crowns, which could be used in posterior teeth and were placed with the adhesive technique.

A clinical check-up program was initiated in order to monitor the quality of the treatment results. Therefore, the tooth status, periodontal probing depth and papillary bleeding index as well as the quality of all the restorations were annually assessed and classified according to the Ryge criteria. Irreparable fractures, tooth loss and deep probing depths were classified as "absolute failures". If the quality of a restoration was deemed to be compromised, but a new restoration was not justified, it was classified as a "relative failure" (e.g. chipping, cracking of the ceramic).

#### **Patients, observations and results**

The study involved 17 patients between the ages of 12 and 69 (at the time of the restoration placement) and a total of

**DENTAL AERO-GUARD  
EXTERNAL AEROSOL SUCTION**

**1. HEPA Double activated  
Carbon + HEPA  
high precision Filter, 4  
quadruple filtering**

**2. Powerful 4000W  
suction motor**

**3. UV-C Irradiation +  
Plasma sterilization**

**4. Removes liquid droplets,  
aerosols, dust and odors**

**5. Wide-mouth  
suction hood**

**6. Suction efficiency  
rates of 99,9%**

**7. Larger unit, larger  
volume capacity**



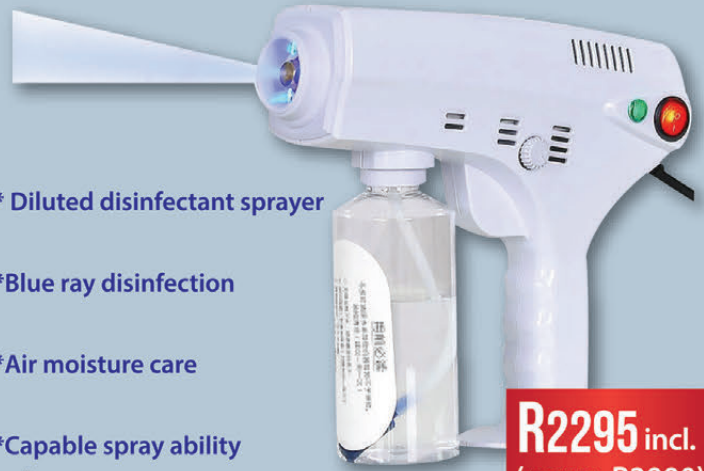**COVID-19 SPECIAL  
SUBSIDISED PRICE  
R22,900 incl.  
(norm. R29900)**

**UV-C Irradiation +  
Plasma Serilization**

**Greatly reduces the risk of cross  
infection between  
doctors and patients,  
protects respiratory health**

- \*Reduce bacterial and viral infections
- \*Defends against cross infection
- \*Eliminates airborne bacteria and viruses from handpiece spray
- \*Helps to remove potential infections during daily treatments

**BLUE RAY - NANO SPRAY GUN**



- \* Diluted disinfectant sprayer
- \*Blue ray disinfection
- \*Air moisture care
- \*Capable spray ability

**R2295 incl.  
(norm. R2990)**

**COMBO DEAL  
BUY BOTH @  
R5500**

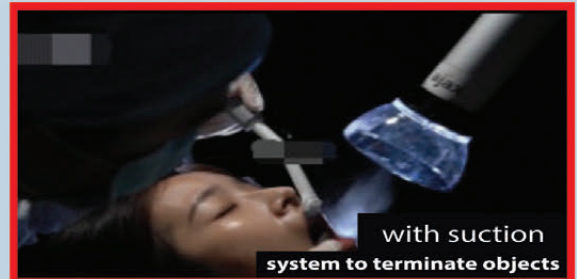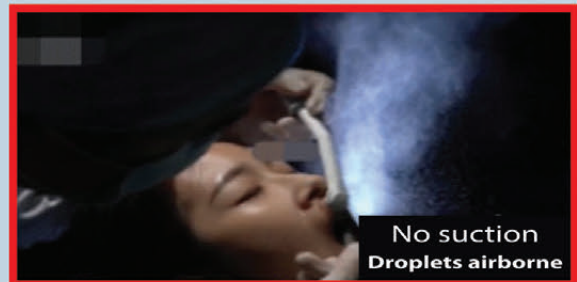**V9 ELETROLYSIS MACHINE  
HYPOCHLORUS ACID MAKER**



- \* Efficient sterilization
- \*Homemade usage
- \*Healthy and essential
- \*Three concentrations
- \*Takes only 5 minutes

**R3495 incl.  
(norm. R3990)**

**Suction treatment  
VS no suction treatment**



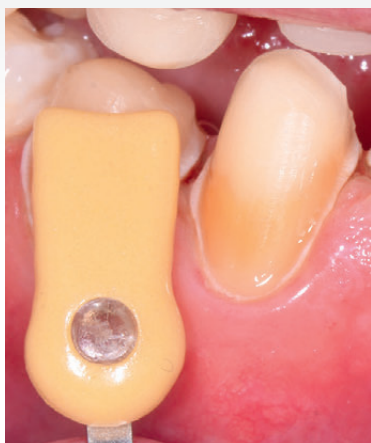

Figure 9: In many cases, the dentin colour deviates considerably from the norm. It is therefore important to select the correct tooth shade for an esthetic outcome of the monolithic crowns.

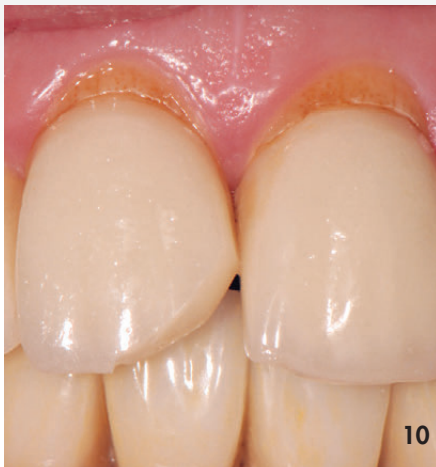

Figure 10: Grade 3 chipping of an IPS Empress II anterior crown after 16 years. The restoration was repaired by adhesively bonding the fragment in place again.

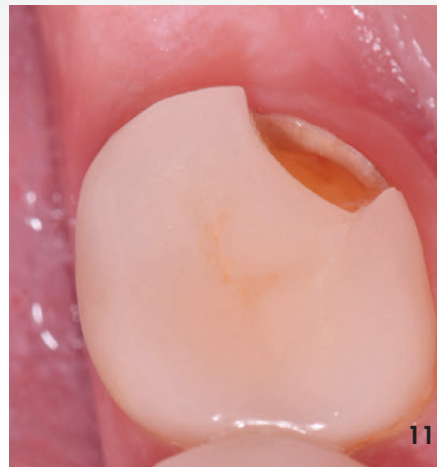


Figure 11: Classical fracture of a molar crown (in this case Celay silicate ceramic, Vita Zahnfabrik) after 14 years. The crown was completely removed and a new restoration was placed after minimal preparation.

450 restorations (Table 1 – QR code). Nine of the patients suffered from some form of AI. The patients were observed over a period of maximum 17 years. During this time, the following complications occurred in 44 restorations (10 %) in 11 patients (65 %):

- Eleven of the 44 restorations were classified as “absolute failures”, which translates to an overall survival rate of 99.8 % after three years and 91.4 % after ten years. No significant

differences were noted between patients with or without AI.

- Thirty-three of the “relative failures” were caused by chipping (25). It is interesting to note that 11 of the “chip-offs” were recorded in one patient alone. Despite the observed complications, the success rate was 95.7 % after three years and 81.4 % after ten years. A statistically relevant difference was noted between patients with and without AI. The success rate of patients with AI was significantly higher.

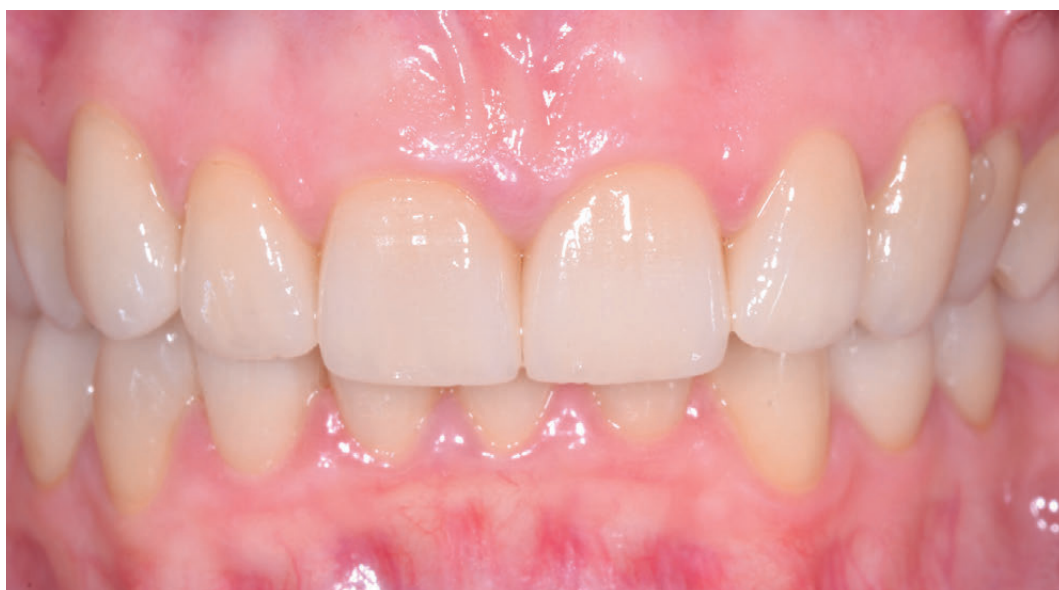

Figure 12: Photo of the restorations placed in the patient shown in Figure 2 after five years of service.

# Welcome!



## CS 8100 Evo & CS 8100 3D Evo



Authorised Dealer

### A FRESH LOOK AT COMPACT 2D/3D IMAGING



#### CS 8100 / CS 8100 3D Family TOMOSHARP TECHNOLOGY

**NEW**

Brand new algorithm delivers best-in-class panoramic images

#### CS Adapt Anatomic family

Brand new processing engine delivers outstanding panoramic and cephalometric images

#### CS 8100 3D Family ADVANCED NOISE REDUCTION

**NEW**

New algorithm designed to reduce noise while preserving image details

#### CS MAR

Carestream Dental's high-end MAR algorithm effectively reduces metal artifacts



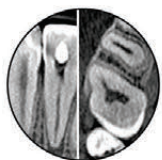#### Powered By: CS Imaging Version 8 Software (CSi8)

Our latest imaging software provides one-stop access to all your 2D images, 3D images and CAD/CAM data—the first step to an effective digital workflow.

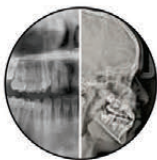
Also comes with 20 Carestream licenses allowing you to also upgrade all your existing Carestream products to operate on CSi8 interface.

\* PC requirements need to be analysed before installation

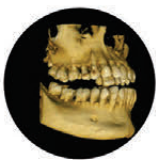[Click here for PC Requirements](#)




INTRAORAL IMAGING



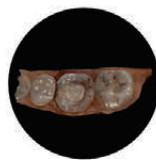EXTRAORAL IMAGING



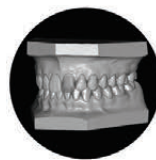CBCT IMAGING



3D APPLICATIONS



DIGITAL IMPRESSION



CAD/CAM

Click Here To View The **8** Reasons to Buy the CS 8100 Evo Edition



Terms & Conditions Apply. Pictures used may be for representation only. E&OE. While Stocks Last



**Table 2 — Overview of all restorations placed, their observation period and material groups, assigned to the respective patient.**

Pat#(AI?)	Age at the time of treatment	Observation period (months)	Crowns Lithium disilicate ceramic	Silicate ceramics	Partial crowns Lithium disilicate ceramic	Bridges	Total number of restorations
1 (AI)	12-13	171	6	22	0	0	28
2	41	182	0	27	0	0	27
3	60	88	0	22	0	1	23
4 (AI)	17	101	28	0	0	0	28
5 (AI)	39	98	28	0	0	0	28
6	31	26	28	0	0	0	28
7 (AI)	18	81	24	0	0	0	24
8	69	72	17	9	11	0	28
9 (AI)	18	65	27	0	0	0	27
10	65	61	20	0	4	1	25
11 (AI)	48	59	24	0	0	0	24
12 (AI)	23	51	27	0	0	0	27
13	43	50	27	0	0	0	27
14	45	43	20	0	0	2	22
15	26	41	28	0	0	0	28
16 (AI)	20	36	28	0	0	0	28
17 (AI)	17	23	27+1*	0	0	0	28
<b>N= 8</b>							
(without AI)	Ø 47.5 y.	Ø 70 months	141	49	15	4	208
<b>N=9</b>							
(without AI)	Ø 23.6 y.	Ø 76 months	219	22	0	0	242

\*: Single-tooth crown (lithium disilicate ceramic), adhesively cemented on an implant abutment  
AI: Amelogenesis Imperfecta

**Discussion**

The long-term performance of the different materials shown in Table 1 and 2 was assessed on the basis of adhesively bonded single-tooth restorations. During an observation period of ten years, we found that fractures of single-tooth silicate ceramic restorations were spread over the entire length of time (Figures 10 and 11), whereas lithium disilicate crown failures tended to occur towards the end of it. These results are comparable to those in the literature. Nevertheless, it must be noted that even though the number

of restorations involved in our study was high, the number of patients was relatively low. Consequently, our findings are limited in terms of their validity. However, they do allow us to identify certain trends.

Molar restorations fractured most frequently: after about five years of service and primarily in patients whose vertical dimension had not been opened. The type of material used may have been responsible for the fractures or the restorations may have been too thin. We were surprised by the fact that the patients with AI had fewer complications

# Penguin<sup>RFA</sup>

## Now Available In South Africa!!!

The Penguin<sup>RFA</sup> measures implant stability and osseointegration to provide sufficient information to make a decision when to load an implant

Autoclavable MultiTiegs with guaranteed accurate readings up to 20 cycles and available for most implant systems sold in South Africa

Enquire about our ISQ device trade in programme and start saving today



than the patients without AI. We had assumed that their restorations would not perform as well due to the "unfavourable" conditions for the adhesive bond. Age may have played a role in this finding, since the patients with AI were about 24 years younger on average compared with the other subjects. In addition, the results of the AI patients showed that adhesive all-ceramic restorations do not cause any endodontic problems. Therefore, they can be classified as a long-term treatment option. Nonetheless, the teeth of patients with AI require circumferential preparation to prevent any weak areas such as cement lines and to restore the function and anatomy of the teeth.

### Summary

Adhesively cemented all-ceramic single-tooth restorations achieve excellent clinical results irrespective of the initial situation (Figure. 12). However, patients with a history of functional problems are expected to have a higher rate of technical complications. Overall, it is likely that about two in one hundred crowns every year will show some sort of complication after five to ten years of service and that primarily restorations in molars will fracture. Therefore, we recommend at least one check-up per year in order to treat any complications as early as possible and therefore minimize the risk of failure.

### Annotation

The present results were previously published in the following article: Klink A, Groten M, Huettig F; Complete rehabilitation of compromised full dentitions with adhesively bonded all-ceramic single-tooth restorations: Long-term outcome in patients with and without amelogenesis imperfecta. J Dent. 2018 Mar;70:51-58. doi: 10.1016/j.jdent.2017.12.011. Epub 2017 Dec 21.

*Reprinted with permission by Reflect 01/2020*



0825469585 | 0737746358  
sales@osseomedical.net  
www.penguinrfa.com

# Aesthetic anterior tooth restorations with nano-ceramic hybrid CAD/CAM blocks

João Mauricio Ferraz da Silva<sup>1</sup> and Danilo de Souza Andrade<sup>2</sup>

## Introduction

For decades now we have been observing a rise in the desire among patients for aesthetic improvements to their smiles. A multidisciplinary treatment makes it possible to achieve a harmonious and healthy smile by adapting the shape, colour, size and positioning of the teeth on the basis of facial parameters. Thanks to scientific progress overall and advances in the materials and techniques used, it is now possible to effect such changes with less invasive procedures. One such treatment technique is ceramic veneers (Belser et al., 1997; Radz, 2011; Rotoli et al., 2013).

The production of veneers begins with minimal preparation of the tooth in such a way that as much healthy dental hard tissue as possible is preserved on the one hand and changes to the shape and even small changes to the colour of the tooth are possible on the other. This novel concept was introduced under the term “minimally invasive dentistry” (Radz, 2011).

The material most commonly employed in the production of ceramic veneers is lithium disilicate-based ceramic, which displays good mechanical properties thanks to its resilience, offers excellent visual properties thanks to its ability to reproduce natural tooth characteristics well and is also bio-compatible with the neighbouring oral tissues (Chen et al., 2018; Palla et al., 2018; Zhi et al., 2016).

Composite-based blocks are also used to produce indirect restorations with the aid of CAD / CAM technology. During the production process, they are exposed to heat and pressure for polymerisation and, as a result, display superior mechanical properties in comparison with direct composite restorations (Mainjot et al., 2016). In terms of their modulus of elasticity and strength, the composite-based CAD / CAM blocks achieve values similar to those of natural tooth substance, i.e., enamel and dentine. These properties can be controlled by the percentage of resin matrix in the constituents of the blocks. In addition, this material displays greater resistance to fatigue compared with ceramics (Alamouh et al., 2018; Magne et al., 2010), and such properties make this material an excellent choice for durable, indirect restorations. Grandio blocs (VOCO GmbH, Cuxhaven, Germany) is an example of a hybrid ceramic block for CAD / CAM systems – it is a nano-ceramic hybrid material containing 86 % inorganic fillers in a polymer matrix. The composite systems for CAD / CAM are indicated for the indirect production of permanent single-tooth restorations such as inlays, onlays, full crowns and veneers.

<sup>1,2</sup> Prof. Dr. João Mauricio Ferraz da Silva and Danilo de Souza Andrade, São Paulo State University, São José dos Campos, Brazil

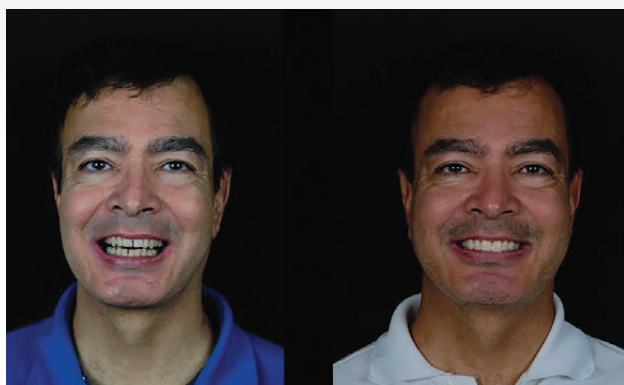

Figure 1: Portrait photo before and after treatment.

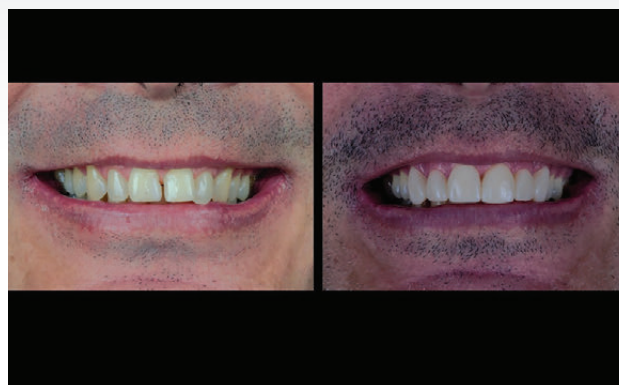

Figure 2: Close-up of smile before and after treatment.

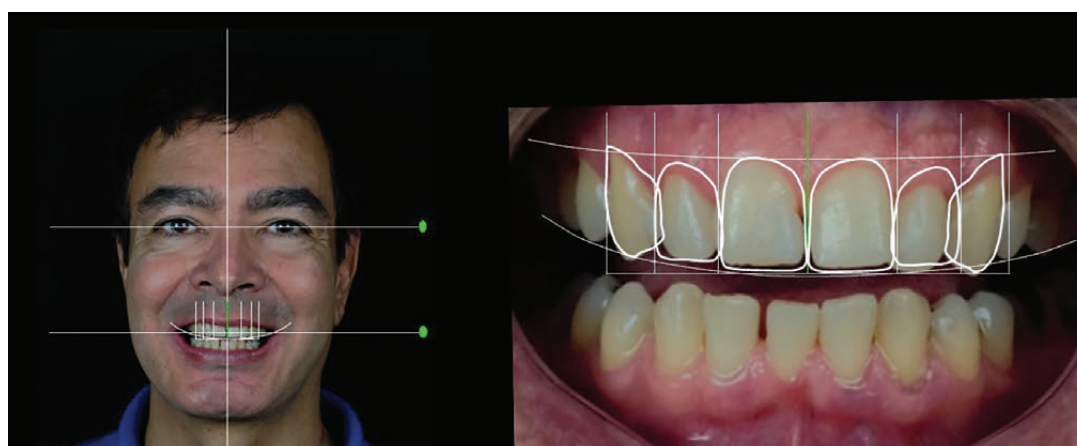


Figure 3: Digital smile design.

Alongside the mechanical advantages, the composite blocks also offer the possibility of shade adaptation directly after the milling process without any need for additional crystallisation, as is the case with ceramic blocks. This represents another advantage of this production technique (Allen et al.). A further interesting factor worthy of note when these blocks are used is that, compared with ceramics, the margins of the restoration do not display any microcracks and are more homogeneous (Tsitrou et al., 2007). The restorations produced using composite-based materials are easier to repair intraorally if and as required, if necessary by freshening up the area, silanising the restoration afterwards, applying an adhesive system and performing the repair directly with the composite (Tsitrou et al., 2010).

This clinical case thus aims to illustrate the possibility for using CAD / CAM technology and composite-based blocks for the indirect restoration of anterior teeth.

### Case report

A 50-year-old patient presented in the clinic of the university project *Construindo Sorrisos Confiantes* (Building Confident Smiles) run by the Department of Dental Materials and Prosthetics at the Institute for Science and Technology at the Federal University of São Paulo in São José dos Campos, Brazil. The patient was unhappy with his smile and particularly did not like the gaps between his teeth or their shade. In the first session, the patient's medical history was recorded, a clinical examination performed and photographs taken for the purpose of the diagnosis and subsequent treatment planning (Fig. 1, Fig. 2).

The examinations revealed that the patient was in good general health and maintained good oral hygiene without any systematic conditions which might affect and / or hinder dental treatment.

The extraoral photographs, comprising a front portrait

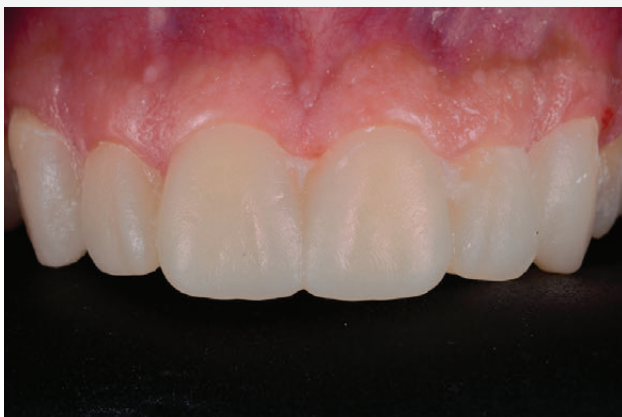

Figure 4: Mock-up.

photograph with lip retractor and forced smile, 45° from the side and a photograph in the 12 o'clock position, and the intraoral photographs, comprising a close-up of the smile, maximal intercuspitation with lip retainers and the maxillary teeth against a black background, were taken prior to the start of treatment (Fig. 3). This was followed by 2D digital smile design (DSD) using the diagnostic photographs, based on the main problem and with the aim of resolving it. The ideal smile was constructed on the basis of the patient's facial features and the function of the stomatognathic system. The parameters employed when designing the smile were the smile line and the position of the lips, the gingival zenith, tooth proportions, the face format and the increase in size in accordance with the principles of the RED correlations (Stanley et al., 2018). Once the final 2D smile design was complete, the data were sent along with the patient's models to the dental laboratory for production of a diagnostic wax-up for the patient.

The model with the diagnostic wax-up was then used to produce a silicone impression, which replicates the proposed new dental anatomy and allows production of a mock-up on the patient's teeth without the need for any tooth preparation, solely with the aim of simulating the proposed aesthetic restoration for the patient. The dentist uses this simulation to analyse the aesthetics and function for the case in question and either recommends or rejects the plan. In addition, the trying-in of the mock-up is ideal for giving the patient an idea of how the proposed aesthetic restoration will look and building up his confidence in the planned treatment.

The mock-up is made using bis-acrylic, which boasts material characteristics such as low heat emission during the polymerisation reaction. It also reproduces the shape of the

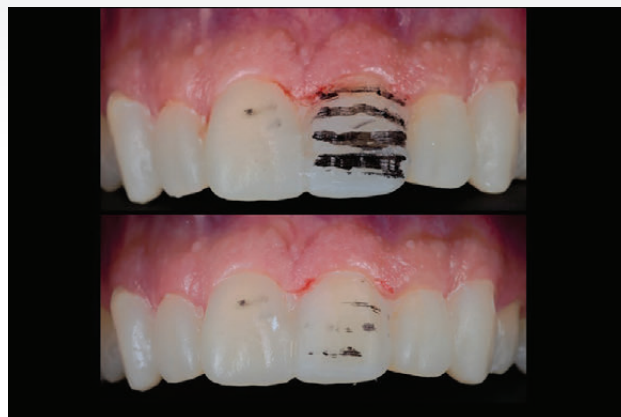

Figure 5: Preparation on the mock-up.

tooth copied using the silicone tray well and has a similar colour to natural dental tissue. The Structur 2 bis-acrylic composite (VOCO GmbH) was used. It was introduced into a silicone tray with the tip of the mixing tip always in the deepest part of the impression so as to avoid air bubbles. Once filled, the tray was inserted into the patient's mouth and the excess material removed during the early stages of the polymerisation. The material was then allowed to cure completely. Once fully polymerised, the silicone tray was removed from the patient's mouth and the surface of the finished mock-up wiped with a piece of gauze soaked in alcohol in order to remove any remaining monomer (Fig. 4).

Once the patient and dentist were both satisfied with the completed planning, a treatment plan for attaining the treatment goal described in the first phase was submitted to the patient. The following treatment was proposed to the patient: tooth whitening to achieve a homogeneous tooth shade and production of veneers made from hybrid blocks (Grandio blocs – VOCO GmbH) for six teeth from tooth 13 to 23 in order to redesign the shape of the teeth.

The technique proposed by Kern & Ahlers (2015) was used as a reference for the preparation of the teeth, with the mock-up serving as a guide for removal of the dental substance. A 4141 grinding bur (KG Sorensen, Cotia, Brazil), characterised by diamond-coated rings, was used to carve reference grooves into the vestibular surfaces of the respective teeth, taking into consideration the incline of the tooth in each third, and an approximately 0.5 mm thick layer of substance removed from mesial to distal. An extra-fine 3145FF diamond bur was then used to remove a second layer of substance from each vestibular surface until the groove placed during the first step was levelled out. The preparation was completed with an extra-fine 3203FF

**AUTOMATICALLY PRODUCE  
DISINFECTANT TO ELIMINATE BACTERIA**



**Dental Suppliers**

**ELECTROLYSIS DISINFECTION**

**ATOMIZER**



\*On Preorder  
**R14995**



\*On Preorder  
**R17995**



SCHOOLS



MALLS



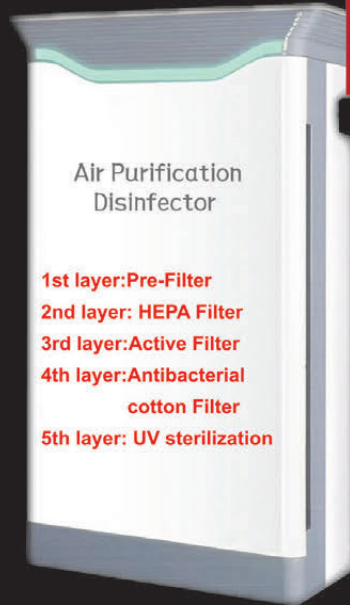
HOSPITALS



HOTELS

**AIR PURIFIER**

**R6995 incl.**  
(norm. R9995)



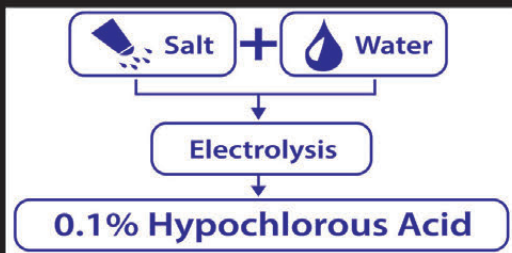

Air Purification  
Disinfecter

- 1st layer: Pre-Filter
- 2nd layer: HEPA Filter
- 3rd layer: Active Filter
- 4th layer: Antibacterial cotton Filter
- 5th layer: UV sterilization



- \*Kills virus
- \*Kills bacteria
- \*Removes smell
- \*Absorbs dust
- \*Cleans air

5 Layers of filters



- \*Uses salt and produces 0.01% hypochlorous
- \*Ideal for waiting room areas
- \*Naturally healthy, no chemicals

**SPUNBOUND GOWNS**



**EACH  
R89.00  
INCL.VAT**

- \*60gsm
- \*Blue and Black
- \*Washable
- \*Reusable
- \*Limited use

**MICRO FIBRE GOWNS**



**EACH  
R479.00  
INCL.VAT**

- \*Fluid Resistant
- \*Blood Resistant
- \*Washable
- \*Wipeable
- \*Reusable
- \*Light Grey Only



**MICRO PEACH GOWNS**

- \*Fluid Resistant
- \*Multiple colours
- \*Washable
- \*Wipeable
- \*Reusable

**EACH  
R379.00  
INCL.VAT**

**BUY 5 For R399**

**HOSPITAL QUALITY**

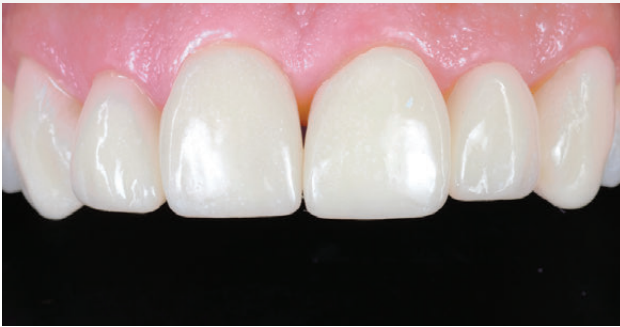

Figure 6: Dry try-in.

diamond bur, with the cervical and proximal preparation margins being defined so as to achieve better marginal integrity for the respective veneers and determine the exact size of the veneers (Fig. 5).

The impression was taken in the same treatment session following the preparation and a single #000 knitted cord (Ultrapak – Ultradent Products Inc., South Jordan, USA) used for the gingival retraction in advance. The cord was soaked in a little haemostatic solution and placed into the gingival sulcus. The impression was performed in two stages with an addition-curing silicone (Virtual – Ivoclar Vivadent AG, Schaan, Liechtenstein). The DSD planning and the model were sent to the laboratory as references and for the production of the restorations.

For insertion of the restorations, a dry try-in was performed in the mouth in advance in order to assess the marginal integrity and final position of the veneers and make any proximal adjustments if and as necessary (Fig. 6). The interior sides of the veneers were produced in the following




Figure 7: Application of Ceramic Bond on veneers.

way in accordance with the manufacturer's specifications: sandblasting with aluminium oxide (25-50 µm), followed by cleaning of the pieces in an ultrasound bath for 5 minutes. The surface was then treated with the bonding agent Ceramic Bond (VOCO GmbH) (Fig. 7): an applicator brush was used to apply the agent to the interior sides of the veneers before it was allowed to work for 60 seconds and then dried quickly with compressed air. The teeth were pretreated with 37% phosphoric acid for 30 seconds as the preparation of the teeth occurred exclusively in the enamel, then rinsed thoroughly with air and water and dried with compressed air. The adhesive Futurabond U (VOCO GmbH) was applied to the tooth surface and massaged in for 20 seconds, followed by removal of the excess material with a fine suction device and light stream of air (Fig. 8).

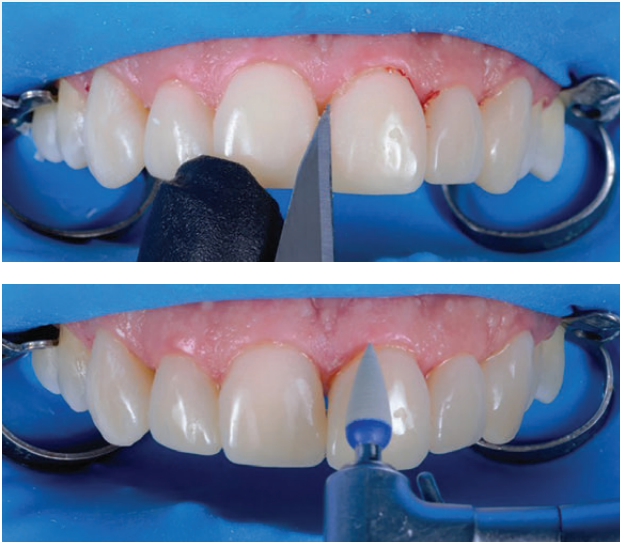
Following the preparation of the veneers and the teeth, the next step was the final insertion of the composite. The dual-curing composite-based luting system Bifix QM (VOCO GmbH) was applied to the interior side of the veneers, the

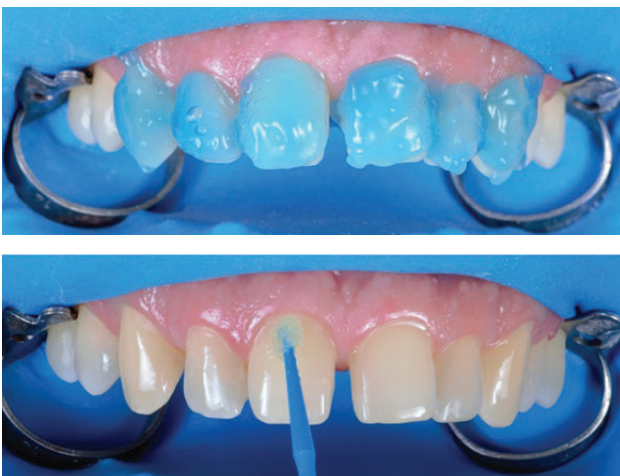

Figure 8: Preparation of the teeth: 37% phosphoric acid for 30 seconds, apply Futurabond U and massage in for 20 seconds.

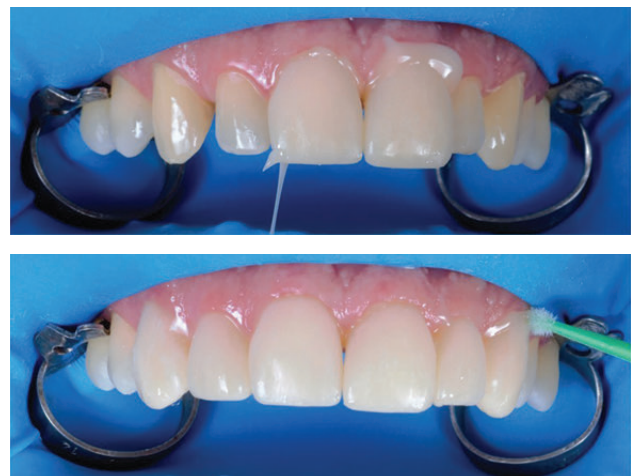

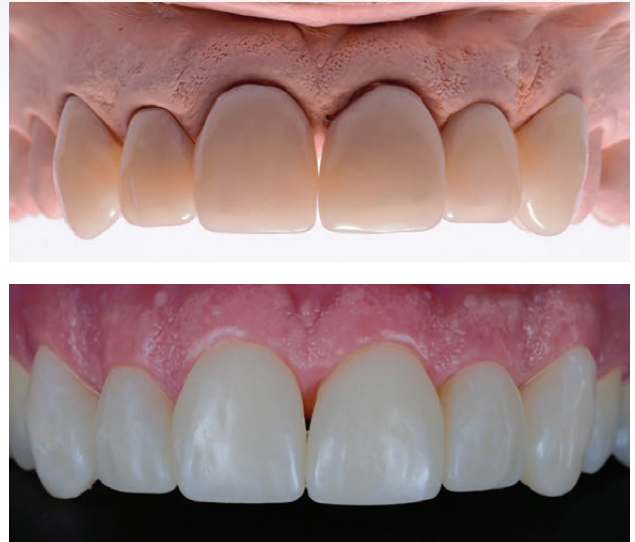Figure 9: Removal of excess Bifix luting material.



*Figure 10: Removal of excess material with scalpel and polishing with the Diamanto polishers.*



*Figure 11: The restoration on the model and in its final position in the mouth.*

veneers brought into their final position and a check for excess material performed. Following removal of the excess material with a brush, the material was light-cured for five seconds to stabilise the veneers. With the restorations fixed in this way, the next step was to remove the excess material using dental floss on the proximal surface and a no. 11 scalpel on the cervical surface (Fig. 9).

This was followed by the final light curing for 40 seconds on each side of the veneer. Once polymerisation was complete, the remaining excess material was removed using a periodontal curette and an interproximal saw. The occlusion was then ground in on the basis of the markings using occlusal articulating film (Accufilm – Parkell Inc., Edgewood, USA) on a holder in accordance with the criteria for optimal occlusion with double-sided and even contact and clearly defined guide surfaces.

Following the grinding, the veneers were finished and polished using Diamanto diamond polishers (VOCO GmbH), giving them their final smooth and lustrous surface (Fig. 10).

The patient was instructed in the essential care and monitoring of the restoration before being discharged with the first follow-up appointment scheduled for 48 hours later. After two follow-up sessions in which the marginal integrity, possible excess material, occlusal contact points and oral hygiene were assessed without any complaints, the patient was briefed on the importance of maintaining good oral hygiene and the requirement for a check-up every six months and then permanently discharged (Fig. 11).

## Conclusion

This case illustrates clearly that the CAD / CAM technique is already a clinical reality and will soon become the only practised means of producing indirect restorations. In addition, we should take the use of alternatives to ceramic materials, which have already established themselves in the scientific literature, into consideration for aesthetic restorations in the anterior region. The hybrid material described displayed good aesthetic and mechanical characteristics in this case, although further clinical studies into the longevity of the material remain necessary.

## References

1. Alamouh RA, Silikas N, Salim NA, Al-Nasrawi S, Satterthwaite JD. Effect of the Composition of CAD / CAM Composite Blocks on Mechanical Properties. *Biomed Res Int.* 2018;2018. doi: 10.1155/2018/4893143.
2. Allen KL, Schenkel AB, Estafan D. An overview of the CEREC 3D CAD / CAM system. *Gen Dent.* ;52 (3):234–5. PMID: 15206254.
3. Belser UC, Magne P, Magne M. Ceramic laminate veneers: continuous evolution of indications. *J Esthet Dent.* 1997;9(4):197–207. PMID: 9468884.
4. Chen X, Zhang Y, Zhou U J, Chen C, Zhu Z, Li LEI. Effect of different surface treatments and retainer designs on the retention of posterior Pd-Ag porcelain-fused-to-metal resin-bonded fixed partial dentures. *Exp Ther Med.* 2018;15(2):2006–14. doi: 10.3892/etm.2017.5630.
5. Kern M, Ahlers MO. Controlling the depth of ceramic



veneer preparations by using a color marker in the depth grooves. *J Prosthet Dent.* 2015;114(6):862–4. doi: 10.1016/j.prosdent.2015.06.010.

6. Magne P, Schlichting LH, Maia HP, Baratieri LN. In vitro fatigue resistance of CAD / CAM composite resin and ceramic posterior occlusal veneers. *J Prosthet Dent.* 2010;104(3):149–57. doi: 10.1016/S0022-3913(10)60111-4.

7. Mainjot AK, Dupont NM, Oudkerk JC, Dewael TY, Sadoun MJ. From Artisanal to CAD-CAM Blocks. *J Dent Res.* 2016;95(5):487–95. doi: 10.1177/0022034516634286. PMID: 26933136.

8. Palla E-S, Kontonasaki E, Kantiranis N, Papadopoulou L, Zorba T, Paraskevopoulos KM, et al. Color stability of lithium disilicate ceramics after aging and immersion in common beverages. *J Prosthet Dent.* 2018;119(4):632–42. doi: 10.1016/j.prosdent.2017.04.031.

9. Radz GM. Minimum Thickness Anterior Porcelain Restorations. *Dent Clin North Am.* 2011;55(2):353–70. doi: 10.1016/j.cden.2011.01.006. PMID: 21473998.

10. Rotoli B, Lima D, Pini N, Aguiar F, Pereira G, Paulillo L. Porcelain Veneers as an Alternative for Esthetic Treatment: Clinical Report. *Oper Dent.* 2013;38(5):459–66. doi:

10.2341/12-382-T. PMID: 23550911.

11. Stanley M, Paz AG, Miguel I, Coachman C. Fully digital workflow, integrating dental scan, smile design and CAD-CAM: case report. *BMC Oral Health.* 2018;18(1):134. doi: 10.1186/s12903-018-0597-0. PMID: 30086753.

12. Tsitrou EA, Helvatjoglu-Antoniades M, van Noort R. A preliminary evaluation of the structural integrity and fracture mode of minimally prepared resin bonded CAD /CAM crowns. *J Dent.* 2010;38(1):16–22. doi: 10.1016/j.jdent.2009.07.003. PMID: 19683378.

13. Tsitrou EA, Northeast SE, van Noort R. Brittleness index of machinable dental materials and its relation to the marginal chipping factor. *J Dent.* 2007;35(12):897–902. doi: 10.1016/j.jdent.2007.07.002. PMID: 17977638



25  
YEARS

UAE International Dental Conference &  
Arab Dental Exhibition

تحت رعاية سمو الشيخ  
حمدان بن راشد آل مكتوم  
نائب حاكم دبي وزير المالية رئيس هيئة الصحة بدبي

Under the patronage of His Highness Sheikh  
Hamdan bin Rashid Al Maktoum  
Deputy Ruler of Dubai, Minister of Finance and  
President of the Dubai Health Authority

إيكد  
AEEEDC  
DUBAI

9-11 February 2021

Dubai International Convention & Exhibition Centre

Largest International Annual Scientific  
Conference and Exhibition in the World

Organized by



Strategic Partner



الهيئة الاتحادية للهوية والجنسية  
FEDERAL AUTHORITY FOR IDENTITY & CITIZENSHIP

حكومة دبي  
GOVERNMENT OF DUBAI



هيئة الصحة بدبي  
DUBAI HEALTH AUTHORITY



Global  
Scientific Dental Alliance



مجلس الصحة  
للدول مجلس التعاون  
Gulf Health Council



جامعة الرياض  
UNIVERSITY OF RIYADH



الجمعية السعودية لطب الأسنان  
SAUDI DENTAL SOCIETY

Supported by

INDEX® Conferences & Exhibitions Organization Est.

INDEX Holding Headquarters | Road # D-62, Opposite Nad Al Hamar | P.O. Box: 13636, Dubai, UAE  
Tel: +971 4 520 8888 | Fax: +971 4 338 4193 | E-mail: info@aeedc.com | Website: index.ae

AEEDCDubai  
aeedc.com



# Highly esthetic results with a new milling machine

Josef Kunkela

## Introduction

CEREC Primemill, Dentsply Sirona's new milling machine, has taken chairside dental restorations to the next level. Thanks to its state-of-the-art technology, a wide range of restorations can now be manufactured faster, using a large variety of materials with results that are very precise and particularly easy to achieve. As a clinical tester for Dentsply Sirona, Dr Josef Kunkela had the opportunity to comprehensively evaluate the new milling machine. The following is a description of his first experiences with CEREC Primemill based on a patient case.

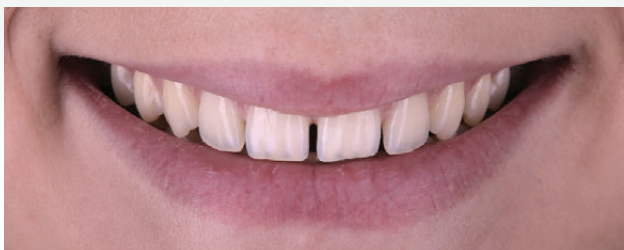I have two essential requirements for digital restorative dentistry: I want to satisfy my patients to the best of my ability for example by producing accurately fitting and very esthetic restorations. I also want to retain complete control over the workflow. This is exactly what CEREC has offered me for 13 years. It's not just about switching from conventional to digital impression taking, it's about the entire process. With the right workflow, I can work very efficiently. This is where CEREC Primemill takes us to a new level. It is a machine that is simple to operate, works with a really fascinating speed and yields high-quality results.

As a Beta tester of CEREC Primemill, I had the opportunity to follow the development process. When this milling machine was set up in my practice, I immediately noticed the new touch interface. In my opinion, it is a great feature to get information about milling cycles and the right instrument recommendation for every procedure.

The second striking point is that the machine works very quietly and above all quickly. CEREC Primemill only takes approximately five minutes using Super Fast mode to fabricate a zirconia crown. In my practice, the assistant takes over the first scan with the new CEREC Primescan. After I have examined the patient and made the therapy decision (which restoration, which shade), the assistant can prepare the CEREC Primemill. Meanwhile, I prepare the teeth to be restored and take the digital impression with CEREC Primescan. The fabrication process then starts directly after the design of the restoration, which is carried out by a dental technician in my affiliated practice laboratory. I can fully concentrate on my work with the patient and on his dental situation. This is efficient and very important for me.

Of course, a perfect workflow also requires the right quality. How useful is it to be finished with everything in the shortest possible time if the restoration does not fit exactly or is visually unattractive? This is where CEREC Primemill once again offers impressive

Josef Kunkela, DMD, PhD, an innovative and renowned dentist and founder of the Kunkela Academy in the Czech Republic



*Figure 1: Initial situation: The patient wants to have an esthetic solution for her diastema.*

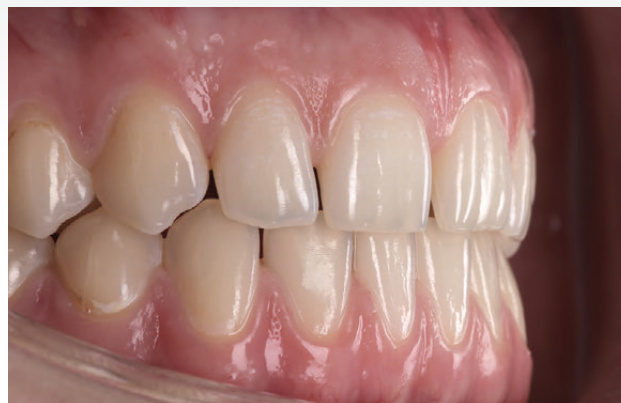results. The surface of the materials is extremely smooth and the margins are very clearly defined.

From a clinical point of view, the following aspects convince me above all else about CEREC: The entire scanning process, including bite registration and preparation control, is very simple. In addition, there are the advantages of the initial scan: catalogue of beautiful natural smile, recycle patient smile, family cross copy smile, gingiva mask over design proposal model, index for direct restorations. If you are going to fabricate a direct restoration of broken incisal edge or corner and if you would like to use layering technique, you benefit from having scanned the initial situation before and from having made a silicone index according to the 3D printed model of patient's natural dentition. And there is greater patient convenience because of the reduction of appointments for treatment and temporary restorations. From an organizational and economic point of view, the efficient workflow, the reduced number of appointments and the ability to delegate many work steps are particularly noteworthy. My experience shows that CEREC begins to pay off at the reception desk when a well-trained assistant plans the appointments and can explain the advantages of this treatment method to the patient.

The most important thing is that CEREC Primescan and CEREC Primemill work together to create a great setup for everyday restorative dentistry. The CEREC system is exceptionally versatile and allows us to freely scan, design and switch from laboratory to chairside software according to our requirements and the daily needs for different material choices and workflows. The following case illustrates this.

### Case Study

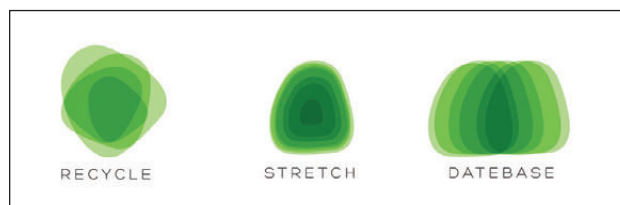A 23-year-old female patient came to my practice and asked for an esthetic solution to her diastema and tremata. The challenge was to preserve the natural surface structure as much as possible. In this case we used the so-called Biocopy Stretch Technique. It is a fairly simple technique



*Figure 2: This is the natural structure of the teeth we wanted to adapt in the final restorations.*

that uses the scanned anatomy to create a larger version of the original while maintaining anatomical accuracy. It is essential that the scanned anatomy is used for the restorations that are to be fabricated. At the same time, it is possible to build a custom tooth library in this way. This can be used for future restorations. This initial scan also offers the possibility to use the gingival mask as a reference for the emergence profile when designing anterior restorations.

With regard to the patient's youth, we opted for non-prep veneers for both the central and lateral anterior teeth. We used the initial scan to make a mock-up of the planned veneers in order to get a better idea of the final treatment result. We sent this scan via the Case Connect Center to our own laboratory where it was processed in the inLab software 19. To further modify the initial proposal, we used the aforementioned Biocopy Stretch Technique. Subsequently, the virtual articulator was used to ensure function in all jaw movements (protrusive and laterotrusive). The mock-up was then milled from PMMA in an MC X5 (Dentsply Sirona). I prefer this method to others because its distinct edge sharpness helps to avoid undercuts and transitions in the final restorations, especially laterally. The



*Figure 3: As there are different methods of copying natural teeth shapes, we decided to categorize them into these three categories of Biocopy.*

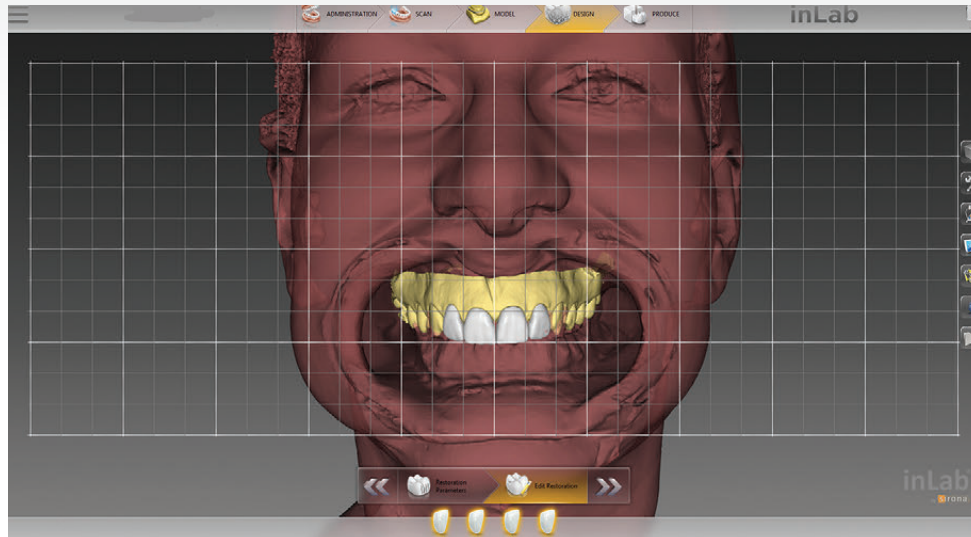


Figure 4: Face-Scan for setting up the occlusal plane and the patient's midline.

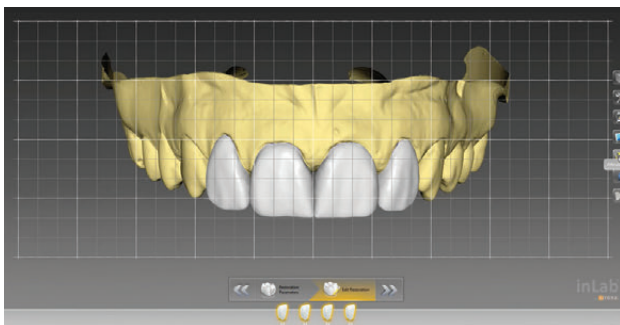


Figure 5: Mock-up design of the veneers in the inLab SW 19.

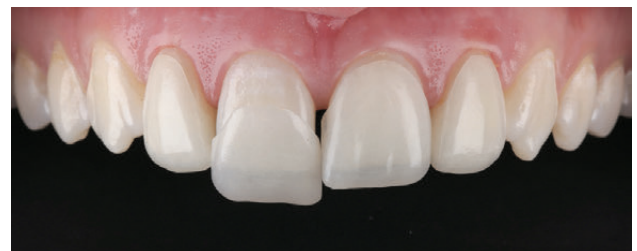

Figure 6: Try-in of the milled mock-up veneers.

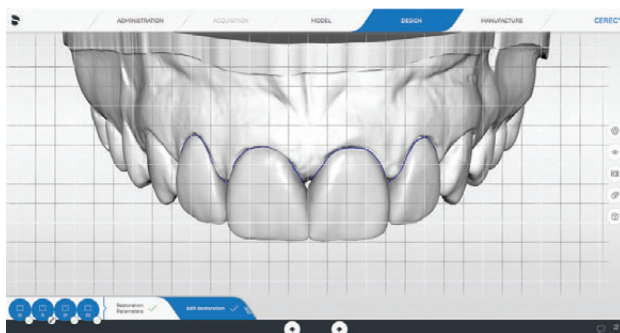


Figure 7: Export of the data into the CEREC SW 5.1.1 and final design of the veneers.

PMMA veneers were then temporarily fixed with a small amount of a flowable composite.

A few days later, the patient returned to the practice. Depending on the degree of satisfaction, the veneers are either re-shaped or used directly as a template for the final

restoration. In this case everything fit perfectly. We then imported the data seamlessly from the inLab software into the CEREC software in dxd-format. In the CEREC software, we simply changed the material setting to composite block and then fabricated the veneers in the new CEREC Primemill. In doing so, we were able to achieve a high level of precision. We used the fine mode because it is ideally suited for the production of ultra-thin veneers.

In order to maintain the high transparency of her natural teeth, the milled veneers were slightly cut back at the incisal edge and constructed with the same restoration material as the blocks used for milling. We then polished the surface in a two-stage system and bonded it adhesively under a rubber dam with composite. The result shows very natural anatomy of the anterior teeth.

### Summary

The CEREC system is exceptionally versatile in allowing us to freely scan, design and switch from lab side to chairside software and then mill or grind a restoration in

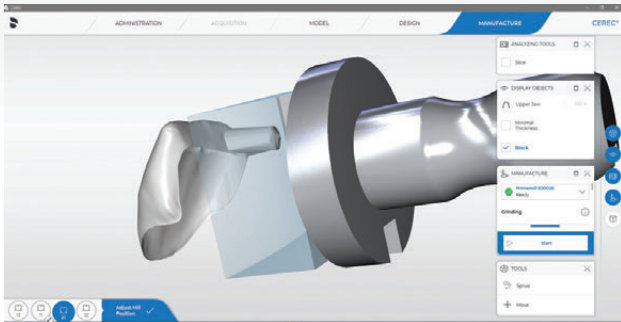


Figure 8: Milling-preview.



Figure 9: Milled veneer in detail.

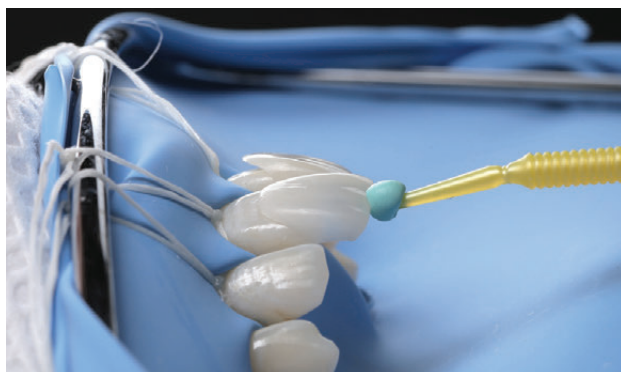

Figure 10: Inserting the veneers using rubber dam for perfectly dry luting surface.

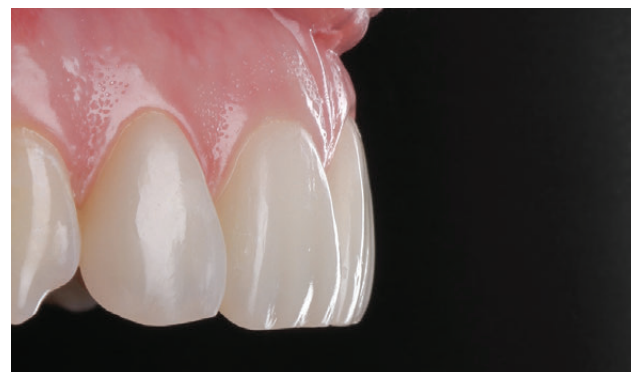

Figure 11: Close-up of the veneer surface which shows the good adaptation of the natural surface of the teeth.

the extraordinarily precise and accurate CEREC Primemill. Capturing the patient's initial situation, position, shape and surface structure for potential future reference, which can also serve as donor anatomies for other patients, will serve

more and more purposes not just in dental prosthetics but also for the manufacturing of 3D models and silicone keys, which are then used for layering restorative materials, digital implantology or dentures.

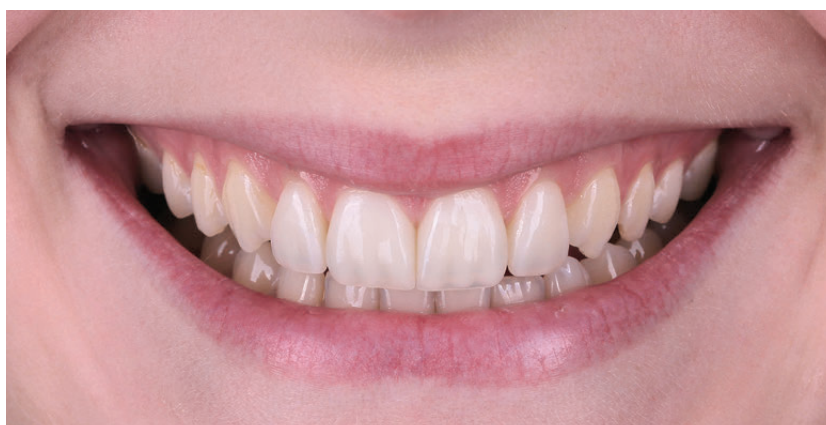

Figure 12: Photo of the restorations placed in the patient shown in Figure 2 after five years of service.



# Advanced concepts. Guided reduction for crowns and bridges.

Attilio Sommella<sup>1</sup>

## Abstract

The aim of the present article is to propose a new clinical procedure for guided dental reduction during preparation using depth markers named "AS Classic depth markers" and "AS-micro depth markers". The proposed clinical procedure applies for the first time an objective numerical value to tooth preparation, thus making it standardized and reproducible. This way, all the basic principles of tooth preparation and minimal invasiveness would be respected.

## Keywords

Minimal invasiveness, calibrated tooth reduction, AS depth marker, AS-micro depth marker, fixed prosthodontics, orientation grooves, guided dental preparation, guided tooth reduction.

## Introduction

Tooth preparation is an irreversible procedure during which the clinical crown is reduced in volume in its three dimensions (height, width, depth) and turned into a prosthetic abutment. Due to its irreversible nature, this procedure requires great attention and manual dexterity.

Biologic tissue preservation (enamel, dentin and root cement) should be the first goal of prosthodontic specialists. As many studies highlighted, this aspect should be balanced out with retention and stability principles as well as the materials used.

We are hereby proposing a novel procedure for tooth preparation in crowns and bridges.

Clinical steps:

1. Occlusal reduction with AS-micro depth markers;
2. Buccal and palatal/lingual orientation grooves with AS Classic depth markers;
3. Axial supra-equatorial reduction;
4. Interproximal separation;
5. Axial sub-equatorial reduction;
6. Polishing and finishing of tooth preparation.

<sup>1</sup>Attilio Sommella, Dr DT  
Dental Laboratory Technician,  
Dental Creation snc,  
Naples, Italy

Email: [somenic66@gmail.com](mailto:somenic66@gmail.com)  
[www.dentalcreationsnc.com](http://www.dentalcreationsnc.com)

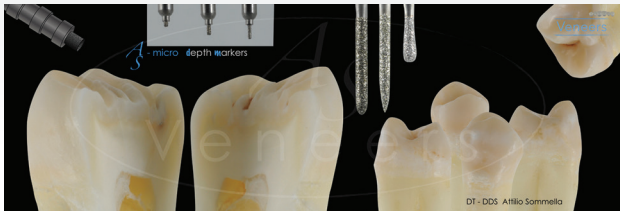

Figure 1: AS- micro markers.

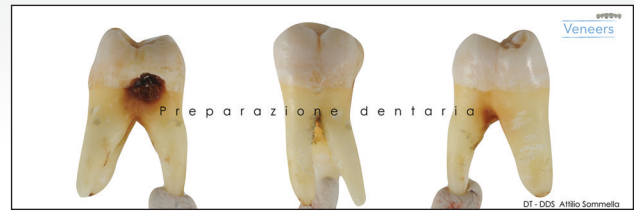

Figure 2: Extracted natural tooth.

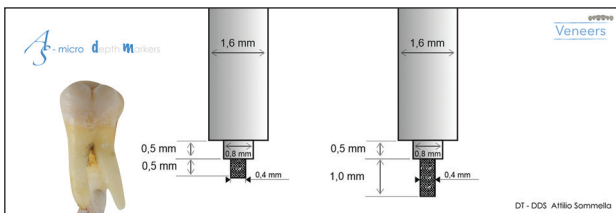


Figure 3: AS-micro markers design and dimensions.

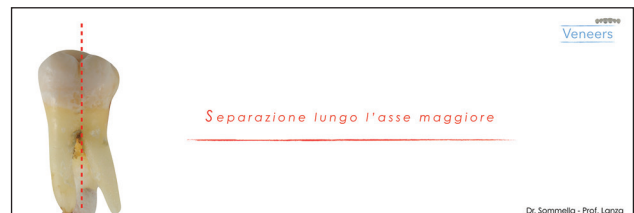


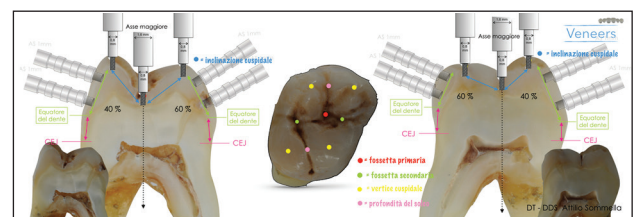
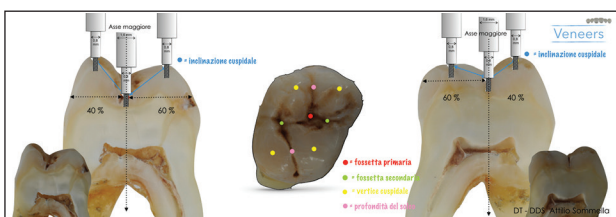
Figure 4: Separation along the long axis of the tooth.

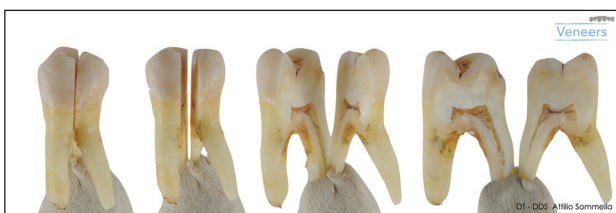

Figure 5: Separated tooth in the laboratory.

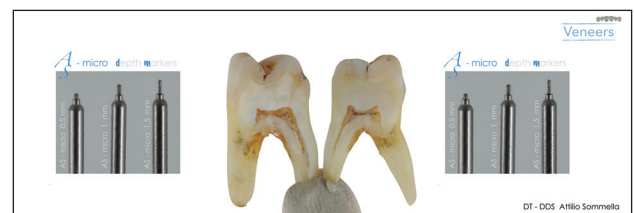

Figure 6: AS-micro markers kit includes 3 cut dimensions: 0,5mm, 1mm and 1,5mm.



Figures 7 & 8: Summary of the minimally-invasive cutting technique using AS-micro and AS-Classic depth markers.

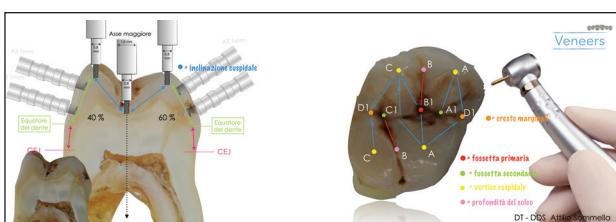


Figure 9: Using a cutting instrument, the corono-apical tooth reduction will be carried out by following the orientation of the internal triangular ridges.

### Technique Description

The present technique will allow clinicians to carry out a reproducible and standardized procedure, based on geometrical principles.

In fact, the innovation has been allowed thanks to the novel "AS-micro depth markers" (Figures 1-9) to be used in conjunction with "AS depth markers Classic" for the guided tooth reduction of molars.

AS-micro depth markers should be used first in order to define the depth cut chosen in specific areas (e.g. primary



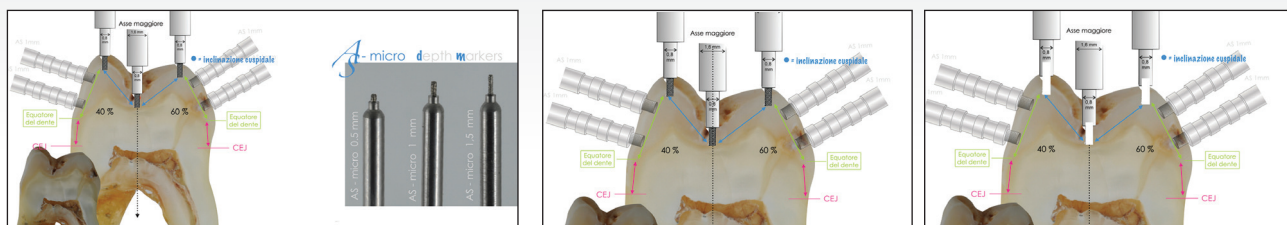
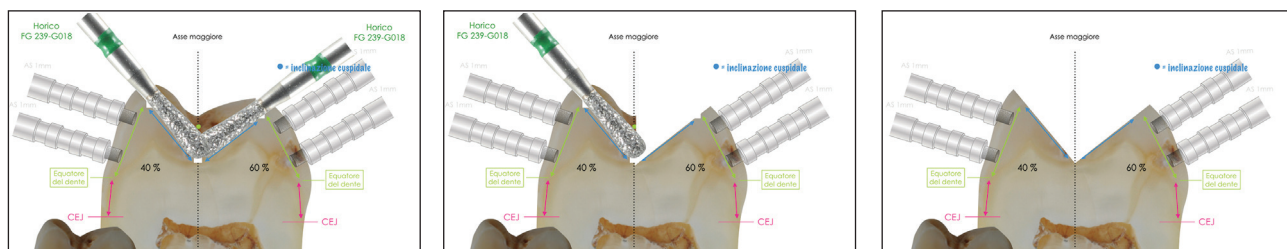


Figure 10: Step-by-step illustration of the technique. Figures 11 & 12: AS-micro markers will cut in the landmark points identified.



Figures 13 = 15: Micrometric control of both cut depth and angulation. Tooth reduction is carried out with a rounded bur (green ring) by following the depth cut previously identified with AS-micro markers.

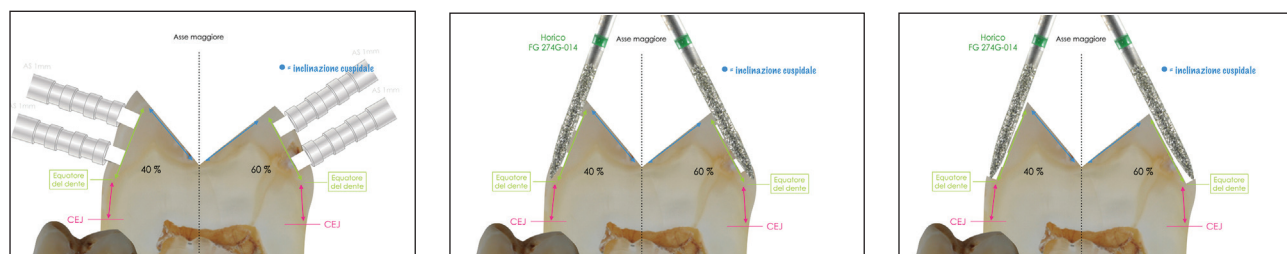
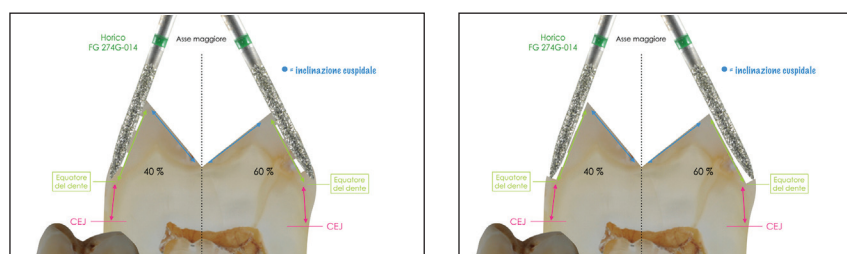


Figure 16: A 1 mm AS-Classic marker will be used to cut the buccal and palatal/lingual surfaces in specific areas.



Figures 17 & 18: By using a pointed green ring bur, we will reduce residual dental anatomy until reaching the depth identified by As markers.

and secondary fossae, cusps, center of every internal triangular ridge, in occluso-buccal and occluso-palatal-lingual grooves), particularly paying attention to mark the same depth at the center of the mesial and distal marginal ridges.

Due to its reduced and streamlined dimensions, the depth marker will easily fit into the narrow spaces of the fossae, thus marking the desired depth right where the most apical point of occlusal reduction will stand (Figures 10-12).

The reduction cut will be then carried out with a rounded cylindrical diamond bur (green ring) by joining the buccal and palatal points A-B-C with the centro-occlusal points A1-B1-C1-D-D1 (Figures 13-15). Afterwards, AS Classic depth

markers will be used for a circumferential reduction by marking the depth cut and then by carrying out a reductional cut until reaching the chosen depth. This reduction will include the tooth area between the most coronal point of the newly-created cusp and tooth equator (Figures 16-18).

While using this technique, clinicians can choose whichever finish line they prefer (Figures 19-22); moreover after the first cut, a diamond bur (red ring) will smooth all surface roughness of the tooth preparation (Figures 23,24).

### Conclusion

Depth cut identification and cut direction have always been two crucial issues in dental preparation techniques. The

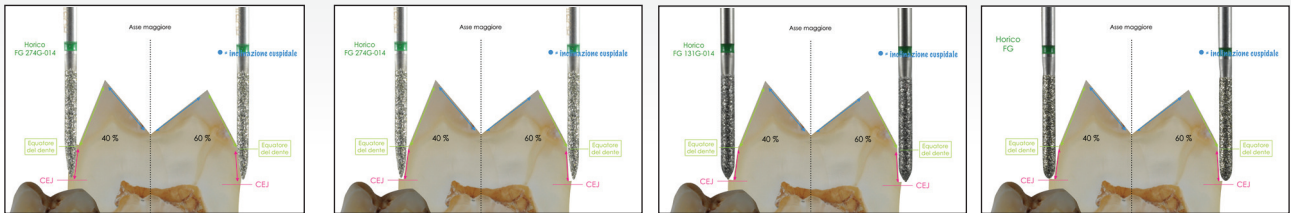


Figure 19: The cervico-axial reduction will be completed along the long prosthetic axis identified.

Figures 20 - 22: Any finish line could be chosen after using these novel depth markers.

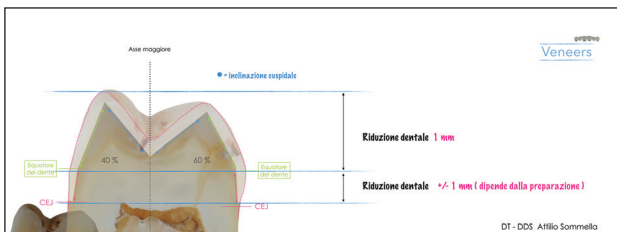


Figure 23: AS Preparation technique and As depth markers will allow clinicians to create a circumferential tooth preparation according to a mathematical/geometrical concept, thus reducing sensitivity operator.



Figure 24: Image summarizing the work-flow for a calibrated tooth reduction.



Figure 25: The AS Depth Marker kit (HORICO, Berlin, Germany)

proposed technique is the first one to date to provide tooth preparation with "solid numeric values" as well as to assist the clinician in carrying out a geometrically-assisted cut, thus minimizing irreversible damage to dental structure.

**Acknowledgements**

I sincerely thank my family and collaborators for supporting and encouraging me in this research. A special commendation to Horico Dental for manufacturing the AS Classic depth markers and the AS-Micro Markers.

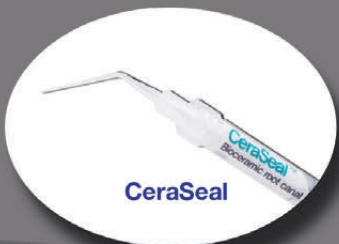
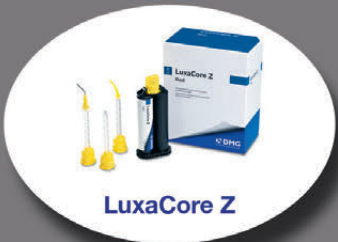
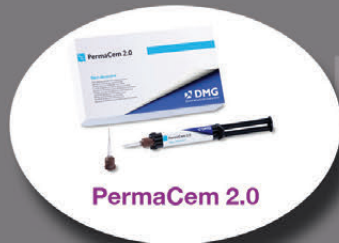**Article: Aesthetic two stage crown lengthening for altered passive eruption: A 25-year case report and review.**  
**Van Zyl & Snyman, page 6**

1. What is the reported prevalence of delayed passive eruption in South Africa?
  - a 19%
  - b 21%
  - c 12%
  - d 9.5%
2. What is the proposed treatment for Altered Passive Eruption type 1A?
  - a Osteoplasty followed by gingivectomy
  - b Gingivoplasty
  - c Gingivectomy
  - d Osteoplasty only
3. Is it always necessary for the 2nd stage surgery, in a two-stage crown lengthening approach?
  - a It depends on the bleeding risk of patient
  - b Only if the dental technician requires it
  - c No, most often not necessary
  - d Yes, that is why it is called two stage
4. What is the physiological function of the supracrestal attached tissues?
  - a It gives the firmness to gingiva to protect against bacteria
  - b Provides a protective barrier for the alveolar bone and the neuro-vascular structures
  - c Provides a protective barrier for the periodontal ligament and supporting alveolar bone
  - d Provides a protective barrier for the gingiva and the alveolar bone
5. The dento-gingival complex is composed of the connective tissue attachment, junctional epithelium and \_\_\_\_?
  - a Cementum
  - b Alveolar bone
  - c Sulcus depth
  - d Periodontal pocket

**Article: Aesthetic two stage crown lengthening for altered passive eruption: A 25-year case report and review.**  
**Van Zyl & Snyman, page 6**

6. Can gingival phenotype be modified by clinical intervention?
  - a No, it is determined by genetics only
  - b Yes, but only in identical twins
  - c Yes, it can
  - d Not, it is impossible
7. Name two methods which can be utilized to measure the dimension of the dento-gingival complex?
  - a Intra-oral radiography can be used
  - b Soft tissue CBCT and bone sounding
  - c CBCT and clinical imaging
  - d Soft tissue CBCT and gingival sounding
8. What is the suggested distance between bone crest and planned gingival margin after crown lengthening?
  - a 5-6 mm
  - b 2 mm in more than 90% of cases
  - c  $\geq$  3mm
  - d Between 2-3mm
9. Is soft tissue removed during the first stage of a two-stage crown lengthening approach?
  - a Yes, but only in a limited manner
  - b No, only the bone
  - c Yes, it is the first stage before bone removal
  - d Yes, bone and soft tissue need to be contoured
10. With regards to Altered Passive Eruption subgroup A, where is the alveolar bone crest located?
  - a 1-3mm coronal to cemento-enamel junction
  - b 1-3mm apical to cemento-enamel junction
  - c At the cemento-enamel junction
  - d Can be above or below the cemento-enamel junction



"Passionate about Dentistry!"

**LuxaCrown**

Semi permanent crowns that can last up to 5 years

**PermaCem 2.0**

The dual curing properties of PermaCem 2.0 offer an exceptional bond across all substrates.

**LuxaCore Z**

The core build up material that cuts like dentine

**Top Head System**

Better retention, built in ferrule and easier core build-up

**LuxaBond**

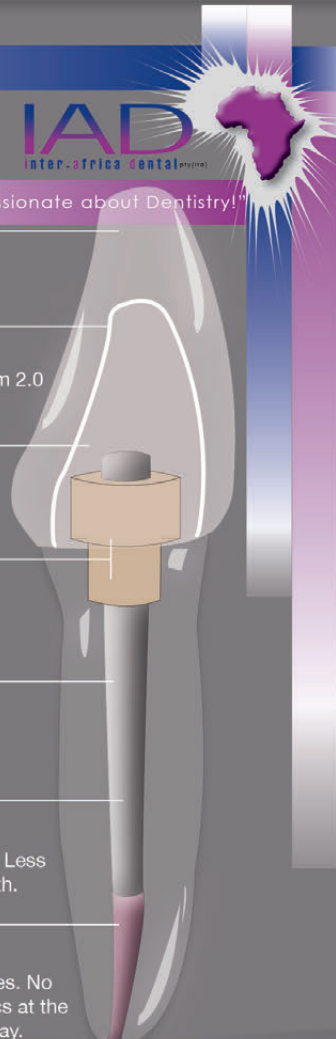
Dual cure bonding made to be used in deep canals

**NTI Fibre Post**

Modulus of elasticity similar to dentine. Less stress on the root for longer lasting teeth.

**Ceraseal**

Pure pre-mixed Calcium Silicate particles. No resin, no cytotoxicity. Actual bioceramics at the best value for money on the market today.



**Article: The efficacy of disinfectants in the decontamination of dental unit water lines: an *in vitro* laboratory study. Patel et al, page 16**

11. Which statement is correct: Contamination of DUWLs becomes a potential source of infection for:
- a Dental health-care personnel                      b Immunocompromised patients  
c Neither of the above                                      d Both of the above
12. Which chemicals have shown to be efficacious in ensuring decontamination of DUWL output water:
- a Hydrogen peroxide  
b Sodium perborate  
c Sodium percarbonate  
d None of the above  
e All of the above
13. Which of the *Enterococcus* species was used in the study:
- a *Enterococcus faecium*  
b *Enterococcus durans*  
c *Enterococcus faecalis*
14. Which statement is correct: In the mixed-culture biofilm pump experiments
- a SPC did not prove any different from water  
b SPC proved to be better than water  
c Both the concentrations of ClO<sub>2</sub> did not prove any different from water
15. The study described showed that continuous use of which concentration of ClO<sub>2</sub> was effective in killing pathogenic bacteria present in the form of biofilm on the DUWLs:
- a 8 p.p.m.  
b 5 p.p.m.  
c 3 p.p.m.

**Article: All-ceramic single-tooth restorations for treating damaged dental enamel: Long-term results in patients with and without amelogenesis imperfecta. Klink et al, page 24**

16. Amelogenesis imperfecta is caused by:
- a Extensive erosion  
b A genetic disorder that affects the tooth structure and the composition of the tooth enamel  
c Grinding
17. What are the main causes of dental erosion?
- a Diet  
b Reflux disease  
c Bulimia nervosa  
d None of the above                                      e All of the above
18. In the study described, the patients had lost a maximum of how many teeth?
- a 5  
b 4  
c 3
19. Patients in the group with irreparable fractures, tooth loss and deep probing depths were classified as:
- a Relative failures  
b Absolute failures  
c Neither of the above
20. Which statement is correct: During an observation period of ten years, it was found that:
- a Lithium disilicate crown failures were spread over the entire length of the period  
b Fractures of single-tooth tended to occur towards the end  
c Lithium disilicate crown failures tended to occur towards the end



Melanie Savvides has worked in the Dental Industry for the last 32 years and was the MD of one of the largest Dental supply companies in South Africa. She has travelled around the world through dentistry, attending numerous courses, workshops and events.

Contact Melanie to improve your patient's experience, focussing on the visit to your practice, the duration and the treatment.

- Infection control audits/ new protocols
- Practice assessment
- Team Building
- Internal marketing
- Staff training



Contact Melanie Savvides | Email: [melaniesavv@gmail.com](mailto:melaniesavv@gmail.com) | Cell: 082 788 1832



