

# A closer look

Steve Jones<sup>1</sup>

Most prosthodontic implant practices have a lot in common. This report describes two typical dental implant placement cases and provides some personal preferences for ensuring a longlasting, esthetic result.

A crestal incision towards the palatal to create small, full thickness flaps makes it possible to roll the excess buccal tissue to boost the tissue thickness on the buccal or labial of the final restoration.

One, two or three unit restorations are usually made in porcelain fused to metal or zirconia and these are usually cemented. Flat top Direct Abutments™ may not always be an optimal choice since some parts of the tissue margin tend to be too subgingival to control the cement. TiDesign™ abutments are manufactured in a wide variety of heights and widths and the margins can be further refined by the dental technician on a soft tissue model.

## Supragingival abutment margin

Leaving the lingual or palatal abutment margin supragingival makes it easy to visually verify the full seating of the restoration. This also acts as a first point of exit for the cement to extrude from, though it is important that the healing abutment is of the same approximate dimension as the definitive emerging restoration. Too much tissue blanching suggests

otherwise, and is to be avoided.

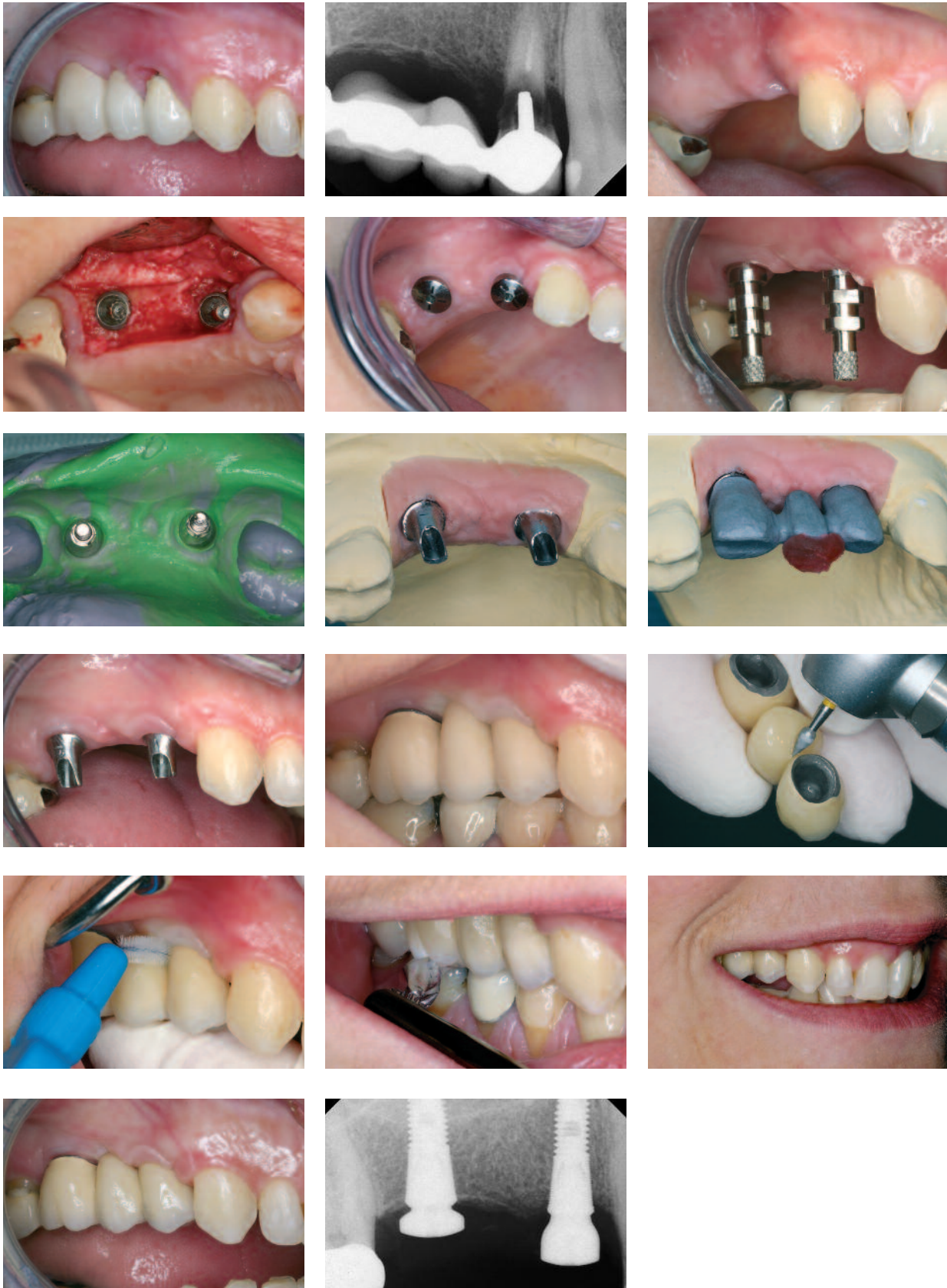Single tooth crowns and small bridges are the most commonly performed procedures. With larger bridges, consider using acrylic teeth to keep costs down and think about incorporating some screw-hole access for easy retrievability.

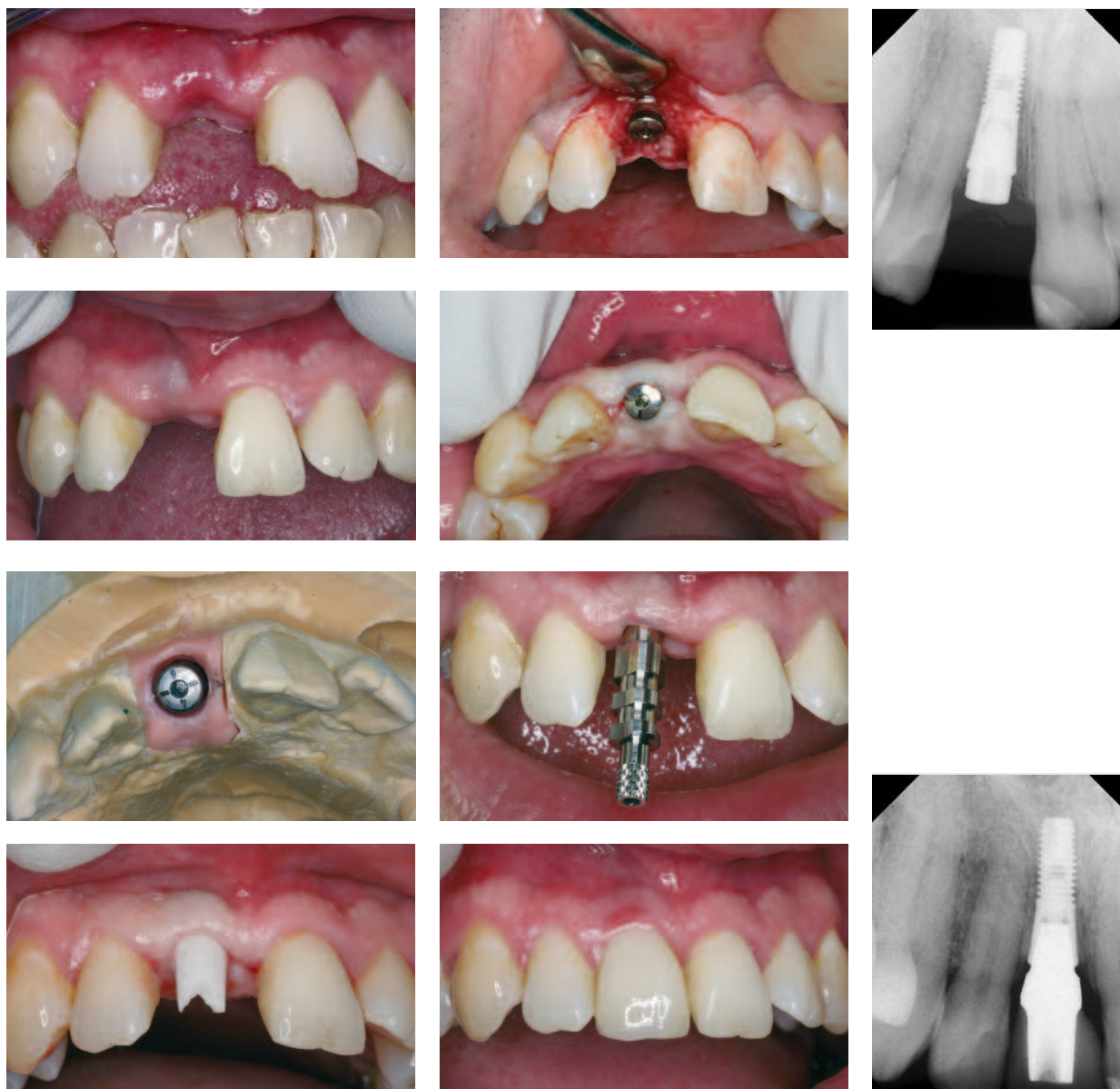
## Case 1

This 48-year old woman was referred for consideration of her failed upper fixed bridge. The premolar abutment was extracted and the distal molar abutment was polished mesially and retained as a single crown PFM restoration. The patient decided to have no temporary denture restoration in place for two months. Two implants were placed as a one-stage procedure with crestal tissue used to augment the buccal soft tissue defect at the premolar site. These smaller bridges are usually cemented over laboratory modified TiDesign™ abutments. Larger bridges usually incorporate some screw retention. Bridgework cases are fully assessed at both metal framework and porcelain bisque-bake try-in procedures. These try-in procedures study occlusal and esthetic factors plus the design features incorporated to allow patients to easily use specific oral hygiene measures – prior to the delivery of the final prosthesis. A metal collar high up buccally on the molar implant was accepted, since it was not visible even with a wide smile.

<sup>1</sup> Prosthodontist  
Newbury, UK

Case 1





**Case 2**

This 37-year old man was referred following a bicycle accident some two months before. On placing the implant, a healing abutment was placed in a submerged procedure to act as a 'tissue scaffold'.

No augmentation material was used. The ability of an Astra Tech implant to hold bone in these situations was very helpful. A ZirDesign™ abutment was placed to ensure good tissue color immediately above the

restoration.

The one year post-implantation radiograph shows the implant head still holding the available bone, thus supporting soft tissue which provides ample healthy papillary tissue on both sides of the restoration – indistinguishable from that around the other natural teeth.

*Reprinted with permission from Insight 10:1:2008*