

PULP REACTION TO VITAL BLEACHING

JO FUGARO, I NORDAHL, OJ FUGARO, BA MATIS, IA MJR

SUMMARY

This study evaluated the histological changes in dental pulp after nightguard vital bleaching with 10% carbamide peroxide gel. Fifteen patients between 12 and 26 years of age with caries-free first premolars scheduled for orthodontic extraction were treated with 10% Opalescence (Ultradent Products, Inc). Tooth #5 had four days of bleaching, tooth #12 was treated for two weeks, tooth #21 was bleached for two weeks followed by two weeks without treatment and tooth #28, serving as the control, was without treatment. All teeth were extracted at the same time. Immediately after extraction, 4 mm of the most apical portion of the root was sectioned off and each specimen was placed in a vial containing 10% neutral buffered formalin. The samples were prepared for histological evaluation at the Scandinavian Institute of Dental Materials (NIOM) and microscopically examined independently at both NIOM and Indiana University School of Dentistry (IUSD). Pulp reactions were semi-quantitatively graded as none, slight, moderate and severe. Slight pulpal changes were detected in 16 of the 45 bleached teeth. Neither moderate nor severe reactions were observed. The findings indicate that the slight histological changes sometimes observed after bleaching tend to resolve within two weeks post-treatment. Statistical differences existed only between the untreated control and the four-day ($p=0.0109$) and two-week ($p=0.0045$) treatment groups.

The findings from this study demonstrated that nightguard vital bleaching procedures using 10% carbamide peroxide might cause initial mild, localized pulp reactions. However, the minor histological changes observed did not affect the overall health of the pulp tissue and were reversible within two weeks post-treatment. Therefore, two weeks of treatment with 10% carbamide peroxide used for nightguard vital bleaching is considered safe for dental pulp.

Jessica O Fugaro, DDS, MSD, Indiana University School of Dentistry, Indianapolis, IN, USA

Inger Nordahl, MSc, Scandinavian Institute of Dental Materials (NIOM), Haslum, Norway

Orlando J Fugaro, DDS, MSD, Lieutenant Commander, USN, director, San Mateo Branch Clinic, Camp Pendleton, CA, USA

*Bruce A Matis, DDS, MSD, associate professor, Department of Operative Dentistry, Indiana University School of Dentistry, Indianapolis, IN, USA

Ivar A Mjr, BDS, MSD, MS, Dr odont, University of Florida College of Dentistry, Gainesville, FL, USA

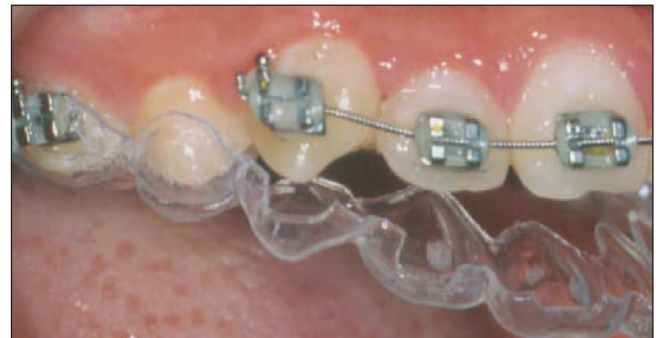


Figure 1. The trays used for bleaching.

INTRODUCTION

Currently, the dental profession relies on a wide variety of esthetic treatments, some more conservative than others. Vital bleaching procedures are considered one of the most conservative treatments, since they do not require any reduction in tooth structure. This fact has led to its increased popularity in the field of cosmetic dentistry. Little is known about the effects of hydrogen peroxide and/or carbamide peroxide on dental pulpal tissues. Therefore, controversy exists relative to the safety of this procedure despite certain products having been accepted by the American Dental Association (ADA) as being safe and effective. The majority of the evidence of pulp sensitivity is based on subjective reports by clinicians and patients. In vivo (Edwall & Olgart, 1972) and in vitro (Cooper, Bokmeyer & Bowles, 1992; Markovic & others, 2000) data have shown that hydrogen peroxide penetrates enamel and dentin within minutes. Pulp studies of histological changes following bleaching with carbamide peroxide have indicated a range of reactions varying from none to minor (Cohen, 1979; Anderson & others, 1999) to occasionally mild to moderate inflammatory responses (Kwong & others, 1993). Thus, uncertainty related to pulp reactions to vital bleaching procedures still exists.

This in vivo study evaluated an ADA-accepted home vital bleaching product on human dental pulp tissues in an attempt to answer some of the concerns associated with vital bleaching procedures. The study evaluated histological changes in pulp as a response to vital bleaching procedures.

METHODS AND MATERIALS

The study population consisted of 11 females and 4 males ranging in age from 12 to 26 years, with a mean age of 16.7 years. Each required the extraction of permanent premolars for

orthodontic reasons. The patients were recruited from the Universidad Latinoamericana Graduate Orthodontic Program and Centro de Estudios Superiores de Ortodoncia, both in Mexico City, Mexico and were required to meet the following criteria:

Patient inclusion criteria:

- Permanent first premolars scheduled for orthodontic extraction.
- Scores of 2 or less using the periodontal screening record. (Evaluation consisted of examining the premolars with a periodontal probe).
- Completed root formation.
- 12 to 35 years of age.

Tooth exclusion criteria:

- Presence of caries.
- Presence of restorations.
- Presence of visible structural defects.
- Presence of pulpal symptoms or radiographic periapical lesions.

The Indiana University-Purdue University Indianapolis Institutional Review Board approved the study. The patients who agreed to be a part of the study were asked to sign a consent form. Parents were asked to sign the consent form for those patients under 18 years of age. One patient required extraction of only three first premolars, making 59 premolars available for the study, 45 equally divided into three bleaching groups and 14 which served as controls.

At the screening appointment, maxillary and mandibular alginate impressions were taken of each patient. Study models were fabricated and trimmed appropriately using Modern Materials Labstone Buff (Heraeus Kulzer, Amherst, NY, USA). On teeth #5, 12 and 21, a 0.5-mm thick veneer of unfilled Block Out Resin (Ultradent Products Inc, South Jordan, UT, USA) was placed on the facial surface to within 1.0 mm of the mesial, distal and occlusal margins and to 1.5 mm of the gingival margin. Vacuum-formed bleaching trays were then fabricated from 0.035-inch plastic sheets (Sof-Tray, Ultradent Products Inc) for each of the maxillary and mandibular casts (Figure 1). Using microscissors, the trays were trimmed to within 0.5 mm of the gingival margin to minimize gingival trauma. The trays were modified with windows to provide accommodation for orthodontic brackets, and the molar areas of the trays were removed to allow for better seating because of orthodontic bands (Figure 1).

At the second appointment the patient was provided a mandibular bleaching tray with a single reservoir for tooth #21, one tube of 10% carbamide peroxide (Opalescence, Ultradent Products, Inc) whitening gel and a container to hold the tray when not in use. The tray was placed in the mouth to ensure a good fit and no interference. The patient was instructed to wear the tray for at least six hours each night for 14 days.

The third appointment followed 15 days after the second appointment. Patients returned their mandibular bleaching trays and were then given the maxillary bleaching tray with reservoirs for teeth #12 and #5, along with one tube of Opalescence whitening gel. They were then instructed to bleach tooth #12 for 10 days as described above; on the 11th day, they were to continue bleaching tooth #12 and begin bleaching tooth #5 for four days. This schedule provided alternative treatment times for the premolars as follows: #5 bleached four days, #12 bleached two weeks, #21 bleached for two weeks followed by two weeks without treatment and #28, which comprised 14 teeth, served as controls with no bleaching treatment. The patients were questioned about any sensitivity during the bleaching treatment.

Oral surgeons extracted the premolars under local anesthesia (2% lidocaine with 1:100,000 epinephrine) using a simple elevator-forceps technique; immediately after extraction, the teeth were wiped clean of any debris with gauze. The most apical 4 mm of the root was then sectioned off using a Lil-trimmer saw (Lapcraft Inc, Powell, OH, USA). After sectioning, the tooth was placed in a screw top vial (Nalgene cryoware, Nalge Co, Rochester, NY, USA) containing 10% neutral buffered formalin and securely fastened. Each vial was labeled with a patient identification number and the corresponding tooth number. The time between tooth extraction and placement in 10% neutral buffered formalin was not more than five minutes. Once all teeth in the study were bleached, all samples were returned to IUSD at which point the samples were sent for histological processing at NIOM. The teeth were demineralized in 5% HNO₃ for 16 to 30 hours. The endpoint of demineralization was checked radiographically. The teeth were embedded in paraffin and serially sectioned axio-facio-lingually through the pulp. Four to six slides, each with four to six sections from different locations in the central part of the pulp, were then stained with hematoxylin and eosin. After histological preparation and examination, the sections were returned to IUSD for an independent examination.

Histological Evaluation

Light microscopic examination of the pulps in stained axio-bucco-lingually sectioned teeth was performed at 40x to 400x magnifications. Since no system for classifying general pulp reactions exists, the well-established semi-quantitative classification commonly used to evaluate local pulp reactions (Stanley, 1968a,b; Mjr & Tronstad, 1972; Browne, Plant & Tobias, 1980) was adapted for generalized pulp reactions in this study. The evaluation included a qualitative assessment of the number of cells in the cell-free zone, irregularities in the odontoblastic layer, the presence of inflammatory cells and extravasated erythrocytes, with attention to the facial aspect of the pulp. Examination for additional reactions included assessment of displaced odontoblasts nuclei into dentinal tubules and disturbance of predentin formation.

A total of 1,068 stained sections were examined microscopically, and the number of sections in each group that showed pulp reactions was evaluated for statistical differences using the generalized estimation equation and paired t-tests.

Results

Most of the experimental and control teeth showed no pulp reactions (Figure 2). Sixteen of the 45 premolars subjected to bleaching demonstrated a slight pulp reaction in a limited part of the coronal pulp. The cellfree zone was less distinct in some areas on the facial surface of those teeth, that is, cells may have migrated into the area (Figure 3). Scattered leukocytes were occasionally observed and irregularities in the pseudostratified odontoblastic layer could be discerned.

None of the teeth demonstrated a moderate or severe reaction to the bleaching agent. Scattered free erythrocytes were occasionally observed in both the bleached and untreated experimental teeth (Figure 4). Displaced odontoblast nuclei were sometimes discerned in the dentin that corresponded to the trauma caused by the forceps at the cemento-enamel junction in both the experimental and control teeth. Vacuolization of the odontoblastic layer was observed in some teeth, and it was the same in bleached and untreated teeth. If present, it was predominantly found in the area of the pulp horns, indicating that it could be an artifact due to inadequate fixation of the pulp. No signs 365 Fugaro & Others: Pulp Reaction to Vital Bleaching cell-rich and cell-free zones, a normal pseudostratified odontoblastic layer, and predentin. Hematoxylin/eosin stain. Original magnification 100x.366 Operative Dentistry of disturbance in the predentin formation were found in any of the teeth. None of the patients had experienced any pulpal discomfort during treatment, but one patient reported gingival sensitivity from incorrect use of the

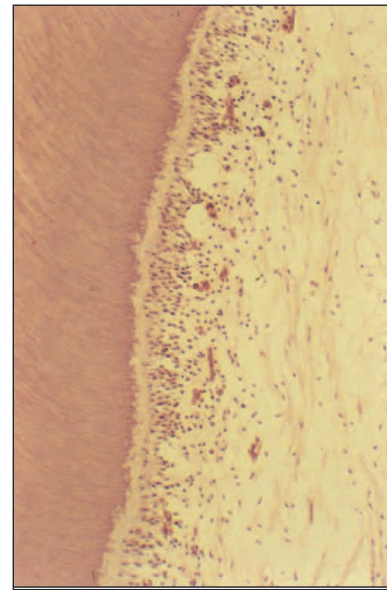


Figure 2. Normal pulp structure showing cell-rich and cell-free zones, a normal pseudostratified odontoblastic layer, and predentin. Hematoxylin/eosin stain. Original magnification 100x.

bleaching tray.

Table 1 outlines the distribution of pulp reactions according to bleaching treatment. The intraindividual comparison of teeth as a function of bleaching time showed that in the six patients with slight pulp reactions after four days of bleaching, three teeth exhibited slight reactions after two weeks of bleaching, along with one of the teeth that was treated for two weeks followed by two weeks with no treatment. Three of the seven patients with slight reactions after two weeks of bleaching also showed slight reactions in the three teeth bleached for four days, but in none of the teeth bleached for two weeks followed by two weeks of no treatment. Of the three patients with teeth showing slight pulp reactions after two weeks of bleaching and two weeks recovery, only one of the other teeth showed a slight reaction after four days of treatment and another demonstrated a slight reaction after two weeks of bleaching. In one patient, the only tooth showing a slight reaction was the one bleached for two weeks followed by two weeks with no treatment. Thus, no pattern could be discerned when comparing slight reactions in teeth from the same patient.

Statistical assessments were based on the number of sections in each treatment group that showed slight or no reactions. Significant differences were found between the four-day bleaching group and the control teeth and between the two found between other groups that were compared (Table 2).

Discussion

Young patients were selected for this study because they had teeth scheduled for extraction in conjunction with

orthodontic treatment and they had intact teeth that were subject to minimal wear or age changes. The enamel and dentin in teeth from young patients is also more permeable than that of older individuals (Mjor, 1980; Mjor, Sveen &

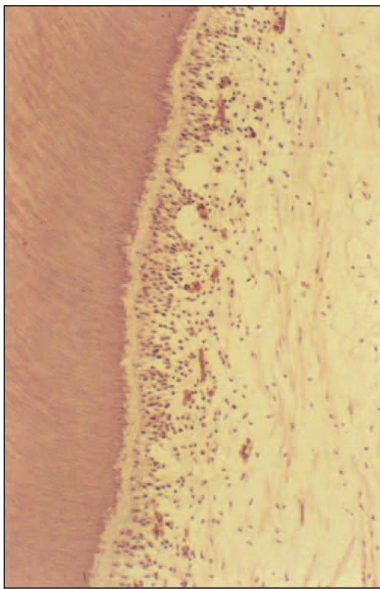


Figure 3. Slight pulp reaction on buccal side of pulp in a tooth bleached for four days. No distinct cell-free zone is present. Hematoxylin/eosin stain. Original magnification 100x.

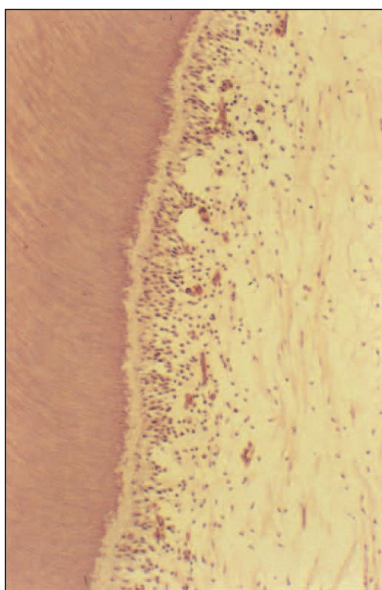


Figure 4. Extravasated red blood cells in the pulp on the facial side of pulp in a tooth bleached for four days. These cells may have been dislodged from the blood vessel during the histological procedure. Hematoxylin/eosin stain. Original magnification 100x.

Heyeraas, 2001). Furthermore, teeth from young patients are generally recommended for testing for pulp reactions (Schroff, 1952; Langeland, 1957; Stanley, 1968a,b; Gvozdenovic-Sedlecki, Qvist & Hansen, 1973).

The time intervals selected for bleaching in this study were based on previous studies, where four days had been the shortest time to show histological changes and two weeks was generally considered the minimum time recommended by dentists and manufacturers for use of 10% carbamide peroxide bleaching agents. These time intervals could also accommodate the needs of orthodontists treating patients.

Methodology is particularly important in evaluating pulpal reactions (Langeland, 1957; Stanley 1968a,b; Mjor, 1980). The histological preparation of teeth for pulp studies has many possibilities for introducing artifacts. However, histological evaluation is considered the most reliable method to evaluate pulpal reactions to clinical procedures (Mjor & others, 2001; Heyeraas, Sveen & Mjor, 2001). Artifacts are generally easily distinguished from histological changes (Langeland, 1957). The few artifacts found in this study were credited to poor fixation or they could be introduced during sectioning of the teeth. Vacuolization of odontoblasts was observed predominantly in pulp horns, irrespective of treatment time. The presence of red blood cells outside blood vessels may be a sign of hemorrhage, but red blood cells may also escape from vessels during passage of sections through various solutions during staining of the sections.

A technique to evaluate histological changes to caries, operative procedures and restorative materials is well established (Langeland, 1957; Stanley, 1968a,b; Fiore-Donno, 1970; Kafrawy, 1978; Heyeraas & others, 2001), and the histological changes are part of a biological assessment of restorative materials for preclinical testing of medical devices used in dentistry (ANSI/ADA Specification 41, 1982; ISO Standard 7405, 1997). The technique is common use focus on pulp reactions subjacent to a discrete lesion, allowing for a comparison with adjacent pulp tissue. There is no classification system available for conditions affecting the main part of pulp or the entire pulp. Therefore, the system used to evaluate localized pulp reactions was adapted to this experimental design, where the entire facial surface of premolars was subjected to bleaching using 10% carbamide peroxide and untreated teeth served as the controls.

The current histological results conform to those reported in other studies (Kwong & others, 1993; Anderson & others, 1999). Since no pulpal sensitivity was reported, the findings also confirm those from other studies (Haywood & others, 1994; Leonard, Haywood & Philipps, 1997; Matis & others,

Table 1: Number of Teeth With and Without Pulp Reaction After Bleaching as a Function of Observation Time

Time of Treatment	Number of Teeth	
	No Pulp Reaction	Slight Pulp Reaction
4 days	9	6
2 weeks	8	7
2 weeks + 2 weeks recovery	12	3
Control	14	0

Table 2: Significance of Differences Between Sections With and Without Slight Pulp Reaction at the Different Observation Periods

Treatment	P
4-day versus control	0.0109
2-week versus control	0.0045
2-week plus 2-week recovery versus control	0.0877
4-day versus 2-week	0.88
4-day versus 2-week plus 2-week recovery	0.27
2-week versus 2-week plus 2-week recovery	0.25

2000) and are in agreement with the histological findings.

Since pulp reactions were small, it was difficult to ascertain whether bleaching per se caused the minor reactions noted. Furthermore, the slight reactions that occurred in some teeth did not show a pattern in the intra-individual comparison of teeth from the same patient. However, statistical analyzes of the number of sections with slight reactions compared to those from the control material showed that significantly more slides were diagnosed with slight reactions in the fourday and two-week bleaching series than in the untreated control material. While these results are encouraging for nightguard vital bleaching with 10% carbamide peroxide gel, the current trend in bleaching is to use faster acting, more efficient products. These approaches generally mean using products of higher concentrations and those that use an activating light or heat source. Great care should be taken in using the current results to justify the use of these higher concentrations. Previous studies have shown that using high concentrations of hydrogen peroxide and heat is potentially harmful to pulp tissue (Seale, McIntosh & Taylor, 1981; Nathanson, 1997).

Conclusions

This study has shown that the nightguard bleaching of teeth with 10% carbamide peroxide gel may cause minor short-term reactions in pulp in about one-third of the intact teeth from young individuals subjected to bleaching. If such changes occur, they are reversible over time. No pulpal sensitivity was reported clinically during the up to two-week bleaching period.

Acknowledgement

The authors thank Dr Carmen Piña for her assistance with this study while in Mexico.

Reprinted with kind permission from Operative Dentistry.

Fugaro JO, Nordahl I, Fugaro OJ, Matis BA, Mjor IA. Pulp Reaction to Vital Bleaching. *Operative Dentistry*, 2004, **29-4**, 363-368

References

Anderson DG, Chiego DJ Jr, Glickman GN & McCauley LK (1999) A clinical assessment of the effects of 10% carbamide peroxide gel on human pulp tissue Journal of Endodontics 25(4) 247-250.

ANSI/ADA Specification 41 (1982) Recommended standard practices for biological evaluation of dental materials American National Standards Institute, New York, NY.

Browne RM, Plant CG & Tobias RS (1980) Quantification of the histologic features of pulpal damage International Endodontic Journal 13(2) 104-111.

Cohen SC (1979) Human pulpal response to bleaching procedures on vital teeth Journal of Endodontics 5(5) 134-138.

Cooper JS, Bokmeyer TJ & Bowles WH (1992) Penetration of the pulp chamber by carbamide peroxide bleaching agents Journal of Endodontics 18(7) 315-317.

Edwall L & Olgart LG (1972) Influence of cavity washing agents on pulpal micro-circulation in the cat Acta Odontologica Scandinavica 30(1) 39-47.

Fiore-Donno G (1970) Discussion of methods and criteria in evaluation of dentin and pulpal responses International Dental Journal 20(3) 528-530.

Gvozdencovic-Sedlecki S, Qvist V & Hansen HP (1973) Histologic variations in the pulp of intact premolars from young individuals Scandinavian Journal of Dental Research 81(6) 433-440.

Haywood VB, Leonard RH, Nelson CF & Brunson WD (1994) Effectiveness, side effects and long-term status of nightguard vital bleaching Journal of the American Dental Association 125(9) 1219-1226.

Heyeraas KJ, Sveen OB & Mjr IA (2001) Pulp-dentin biology in restorative dentistry Part 3: Pulpal inflammation and its sequelae Quintessence International 32(8) 611-625.

ISO Standard 7405 (1997) Dentistry—preclinical evaluation of biocompatibility of medical devices in dentistry—Test methods for dental materials International Organization for Standardization Geneva Switzerland.

Kafrawy AH (1978) Biology of the dental pulp Alumni Bulletin of the Dental School at the Indiana University 4-10.

Kwong K, Mohammed S, McMillan MD & Stokes AN (1993) Evaluation of a 10 percent carbamide peroxide gel vital bleaching agent New Zealand Dental Journal 89(395) 18-22.

Langeland K (1957) Tissue changes in the dental pulp. An experimental histologic study Odontologisk Tidskrift 65 1-146.

Leonard RH Jr, Haywood VB & Phillips C (1997) Risk factors for developing tooth sensitivity and gingival irritation associated with nightguard vital bleaching Quintessence International 28(8) 527-534.

Markovic M, Sieck BA, Takagi S, Chow LC & Majeti S (2000) Diffusion of hydrogen peroxide through sound tooth enamel Journal of Dental Research 79 Abstract #1290 p 305.

Matis BA, Mousa HN, Cochran MA & Eckert GJ (2000) Clinical evaluation of bleaching agents of different concentrations Quintessence International 31(5) 303-510.

Mjor IA (1980) The importance of methodology in the evaluation of pulp reactions International Dental Journal 30(4) 335-346.

Mjor IA, Sveen OB & Heyeraas KJ (2001) Pulp-dentin biology in restorative dentistry Part 1: Normal structure and physiology Quintessence International 32(6) 427-446.

Mjor IA & Tronstad L (1972) Experimentally induced pulpitis Oral Surgery Oral Medicine Oral Pathology 34(1) 102-108.

Nathanson D (1997) Vital tooth bleaching: Sensitivity and pulpal considerations Journal of the American Dental Association 128(Supplement) 41s-44s.

Seale NS, McIntosh JE & Taylor AN (1981) Pulpal reaction to bleaching of teeth in dogs Journal of Dental Research 60(5) 948-953.

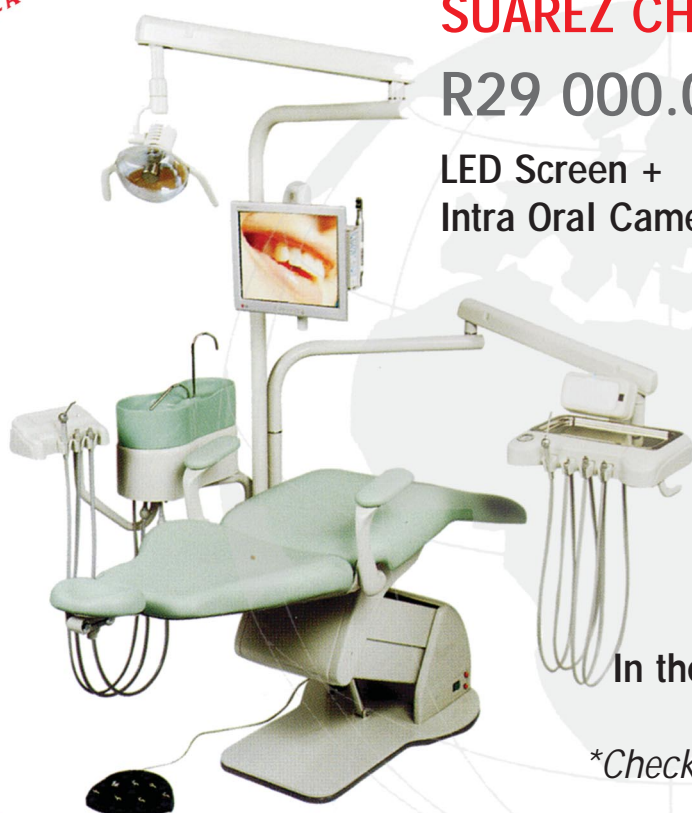Shroff FR (1952) Effects of filling materials on the dental pulp: a critical review Journal of Dental Education 16(4) 246-259.

Stanley HR (1968a) Design for a human pulp study I Oral Surgery Oral Medicine Oral Pathology 25(4) 633-647.

Stanley HR (1968b) Design for a human pulp study II Oral Surgery Oral Medicine Oral Pathology 25(5) 756-764.



Tel: +27 11 315 8040 • Fax: +27 11 315 8060
PO Box 8401 Halfway House 1685



SUAREZ CHAIR

R29 000.00 VAT inc

**LED Screen +
Intra Oral Camera optional**



J.O. SUAREZ
*La Mejor Elección
The Best Option*

BUDGET SURGERY AVAILABLE

FROM

R85 000.00 + VAT

In the Suarez Range with a 2 year guarantee

**Check at Clinical Success Congress for a Demo*