

Advanced restorative techniques and the full mouth reconstruction: the use of gold copings in bridgework

Paul Tipton¹

Introduction

From the studies produced by Lindhe and Nyman, described earlier in the series, it would certainly seem possible to succeed with long span bridgework, provided many of their criteria for success are followed, such as occlusal design, margin placement, oral hygiene etc. The other important aspect of this type of longer span bridgework is to control the stress on cement lutes, where failure can readily occur. This is achieved in the Lindhe and Nyman bridgework design by using the technique only for mobile abutment teeth. When the prognosis of longer span bridgework is in doubt because of the loss of many units or non-mobility of abutments, gold copings can be used (Robertson, 1986). Copings (otherwise known as telescopic crowns) were originally used to overcome problems of parallelism in relation to the path of insertion of fixed restorations (Amsterdam, 1974).

Type of coping

The gold coping is a thin crown, 0.7mm thick, that is waxed directly onto the dies and usually cast in yellow gold. They are made parallel to each other and can be

sandblasted by the technician for extra retention (Figures 1 to 3) (Newburg, 1978). The margins are polished, however, as they will be exposed in the mouth. These copings are permanently cemented over the remaining abutment teeth with a traditional hard cement, such as zinc phosphate. The long span bridgework is then made in the conventional manner and cemented over the gold copings with a softer cement such as zinc oxide and eugenol such as 'Temp-bond' (Kerr). Should excess stress be transferred to the cement lute then one or more of the soft cement lutes will preferentially fail.

However, because the copings have been made parallel to each other there is reasonably good retention of the bridge, even without cement. When all the cement lutes fail and the cement washes out, the patient will usually re-attend for further cementation with more soft cement.

It is unlikely that caries will occur under the bridgework because the tooth structure is protected by the gold coping. Bridgework margins are placed above or incisal to the gold coping margins so that periodontal problems can be avoided. This style of bridge design does, however, require more aggressive tooth removal as an extra 0.6-1mm is required for the extra thickness of the gold coping and cement lute. Alternatively, a non-precious coping can be fabricated when required, bringing the thickness of the coping down to 0.3mm.

¹ Dr Paul A. Tipton, BDS, MSc, DGDGP UK
Private Practice, London, Leeds, Liverpool and Edinburgh, UK

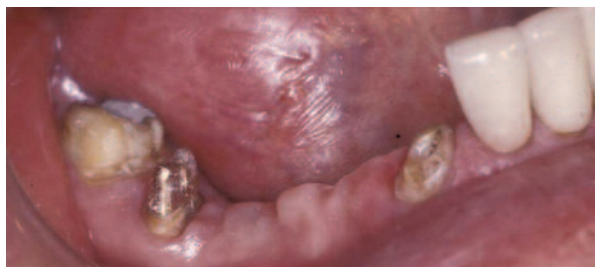


Figure 1: Three root-filled anterior and posterior teeth.

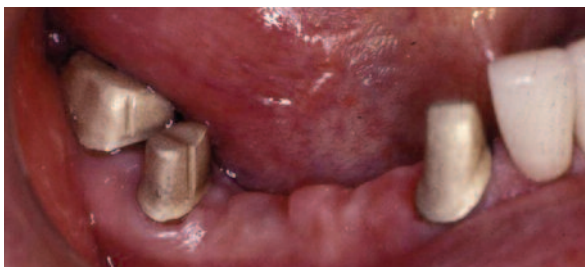

Figure 2: Sandblasted gold copings cemented in place with zinc phosphate.

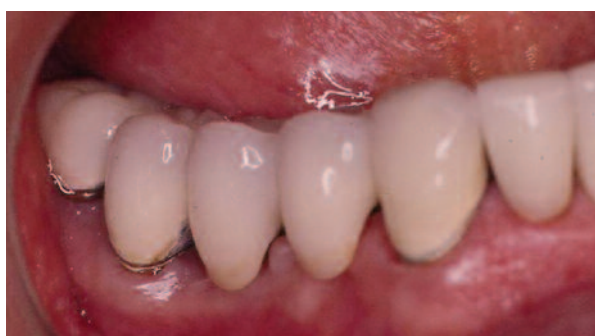

Figure 3: Three-quarter gold crown as a minor retainer in mandible.

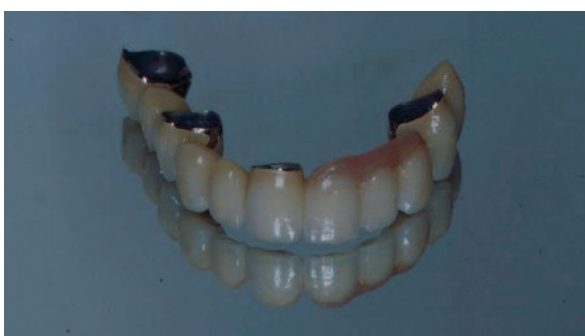

Figure 4: Full arch bridgework.

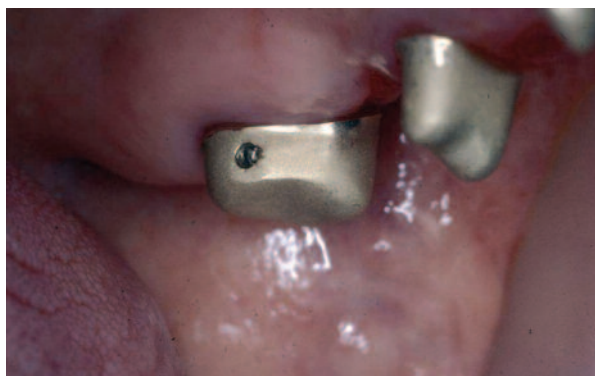

Figure 5: Screw block placed in the posterior gold coping.

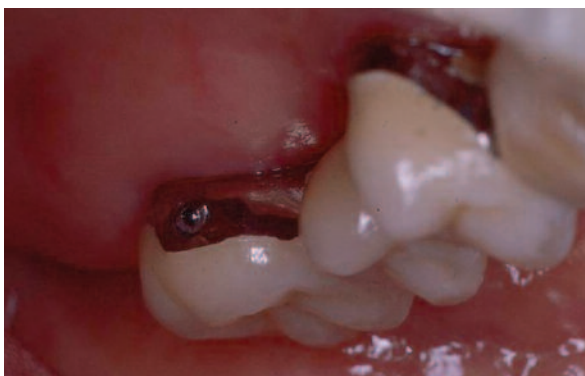

Figure 6: Bridgework screwed into the gold copings.

Screw retention

One or more screws can also be incorporated into the restoration so that when the cement lute fails the bridgework does not fall out of the mouth but is retained by the screws. This gives the patient added confidence in their restoration (Figures 4 to 6) and is especially useful in the upper jaw. Careful preparation techniques are required for this type of retention as the screw could (in certain situations) pull the coping off the tooth, leading to an increased risk of caries.

The screws are usually placed into the end abutments, which require special tooth preparation. The end abutment is prepared so that it is tilting distally, allowing for a distal path of insertion of the coping. Bridgework usually unseats

from an anterior-posterior direction of force and therefore the fit of the coping on the tooth will resist this type of dislodgement, thus maintaining a cement seal between the coping and the tooth. The technician will upright and parallel the abutment by waxing and casting his gold coping parallel to all the others for seating of the bridge and correct path of insertion.

Uses

One of the major advantages of this style of bridgework is the flexibility it brings to a restoration. In theory, the bridge can be removed by untapping (and unscrewing) so that problems with abutment teeth and periodontal disease can be treated.

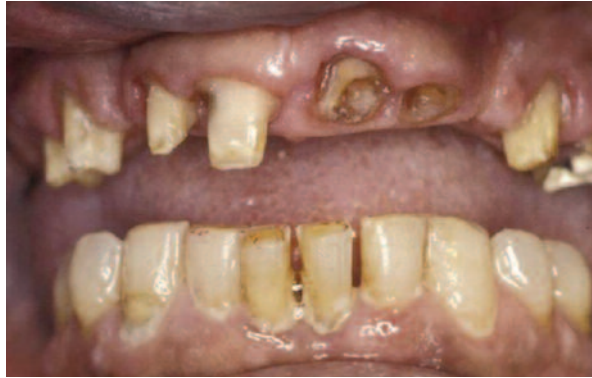

Figure 7: Combined complex perio/endo case.

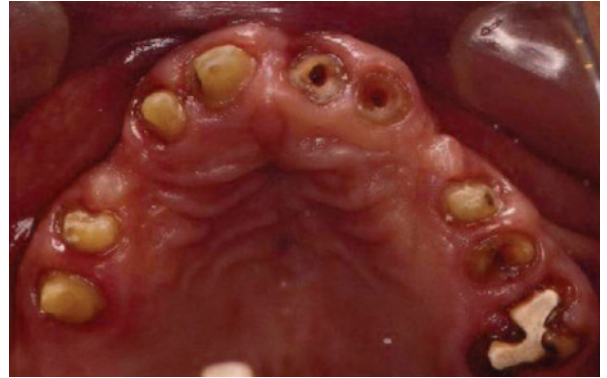

Figure 8: Occlusal view showing remaining compromised abutments.

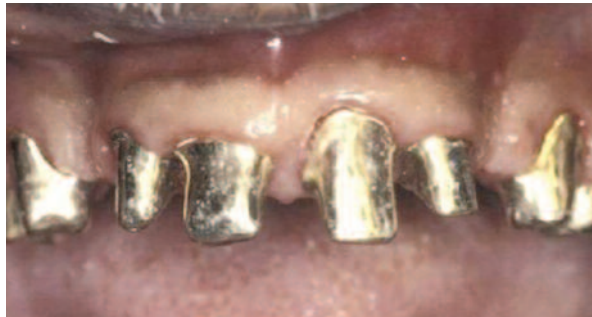

Figure 9: Gold copings cemented in place with zinc phosphate.

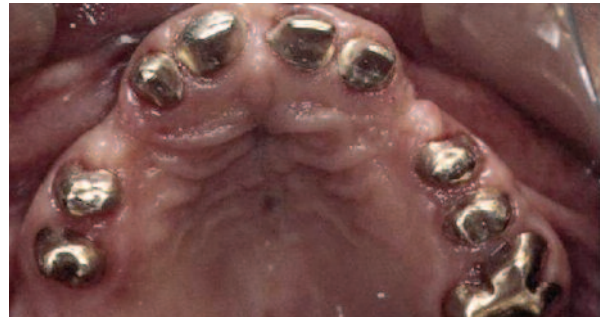

Figure 10: Occlusal view.

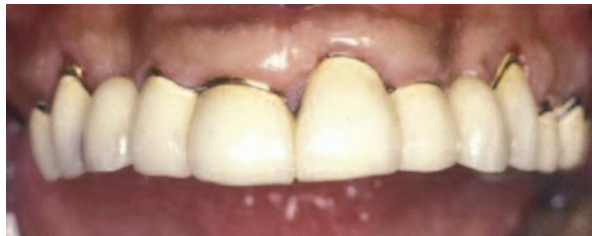

Figure 11: Full arch bridgework cemented onto copings with Temp-bond as long-term provisional prior to definitive implant treatment.

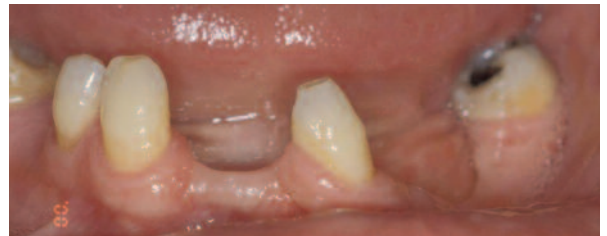

Figure 12: Patient presents with multiple tooth loss.

In this manner, periodontal maintenance is more easily achieved, root fillings and cast posts and cores can be fabricated without drilling through the superstructure and teeth can be removed, roots resected and the bridge modified prior to re-cementation (Figures 7 to 11).

Further abutments may be added by soldering new retainers or attachments and anticipating future modifications (Kaldahl, 1985). Be aware, however, that this type of bridge cannot then be removed for porcelain addition without the increased risk of porcelain fracture while in the furnace due to saliva contamination.

Multiple unit bridgework when cemented on mobile abutments often fails to seat adequately unless venting is performed. An alternative is the use of copings where an

incomplete seal and seat is less detrimental (Faucher, 1983). This type of bridge is often used as an interim prosthesis while implants are placed around the tooth abutments to take the patient from a tooth-supported bridge to an implant-supported bridge without the need for a removable prosthesis.

Aesthetics

Aesthetics can be compromised by this type of bridge because – as previously mentioned – extra tooth preparation is required (which may not always be possible) and there are also two finish lines. Although advantageous in an aesthetic restoration (Figures 12 to 23), it may not always be possible to keep both of these metal margins

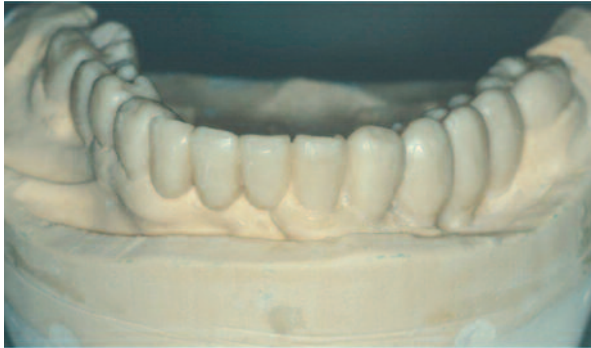


Figure 13: Diagnostic waxing performed.

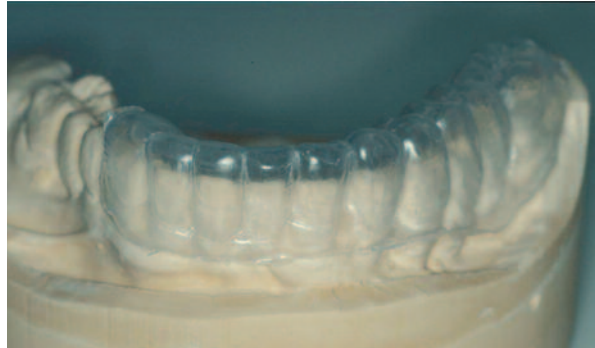

Figure 14: Tooth preparation guide.

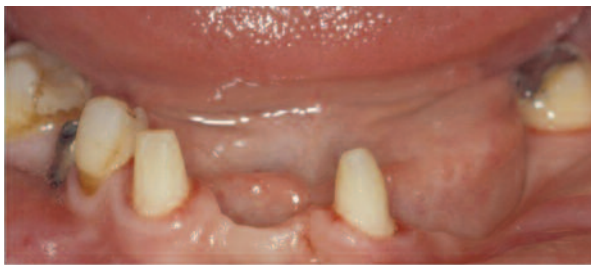

Figure 15: Preparation of the three teeth for the coping bridge.



Figure 16: Silver dies anterior view.



Figure 17: Silver dies left hand side view.



Figure 18: Coping and implant abutments right hand side view.

sub-gingival. Should extra tooth preparation not be completed then an over-contoured bridge or one that shows excess opaque porcelain on the labial surface may result.

Conclusions

Gold copings can be an excellent long-term, or provisional restoration as the coping can protect the tooth from caries and cementation failure. Maintenance is made easier by the ability to remove the superstructure at will. Aesthetics can often be compromised by the need for greater tooth reduction and often two visible metal margins.

Acknowledgements

I would like to thank Martin Fletcher, Bradley Moore and John Wibberley for their technical help in these cases.

References

- Amsterdam M (1974) Periodontal prosthesis – 25 years in retrospect. *Alpha Omega* 67: 9
- Faucher R, Bryant R (1983) Bilateral fixed splints. *Int J Perio Rest Dent* 3: 9
- Kaldahl W, Becker C (1985) Prosthetic contingencies for future tooth loss. *J Prosth Dent* 53: 1
- Newburg RE Pameijer CH (1976) Retentive




Figure 19: Copings left hand side view.

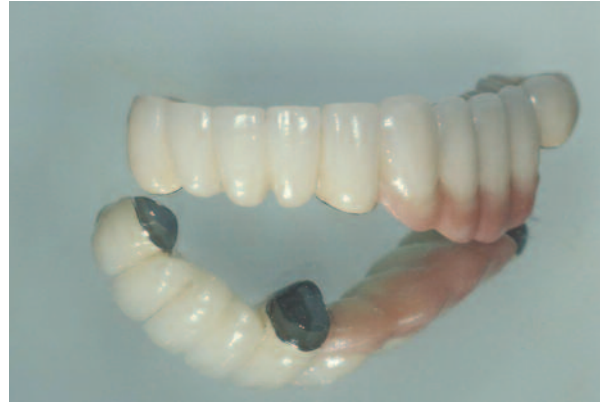

Figure 20: Completed bridge - anterior view.

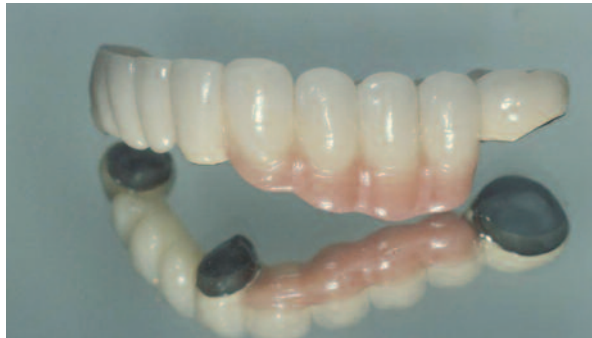

Figure 21: Completed bridge - left hand side view.

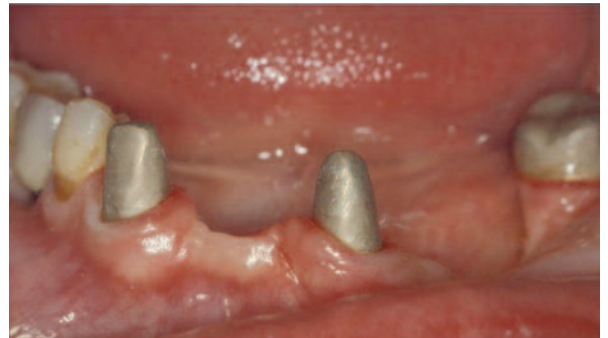

Figure 22: Copings cemented in the mouth - phosphate cement.

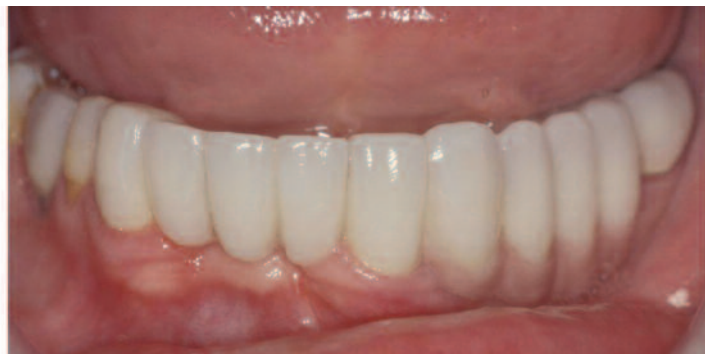

Figure 23: Bridge cemented over the copings with 'soft cement'.

properties of post and core systems. J Prosth Dent 40: 538

Nyman S et al (1975) The role of occlusion for the stability of fixed bridges in patients with reduced periodontal tissue support. J Clin Periodont 2: 53

Nyman S, Lindhe J (1976) Prosthetic rehabilitation of patients with advanced periodontal disease. J Clin Periodont 50: 163

Robertson G (1985) The role of copings in fixed bridgework. Rest Dent Oct: 160

Wise M (1995) Failure in the restored dentition management and treatment. Quintessence, Chicago. Chapter 18: 305

Reprinted with permission from Private Dentistry January 2011