

Clinical factors related to implant stability

Tiziano Testori¹

Abstract

Immediate occlusal loading of dental implants offers benefits to both patients and clinicians. Although excellent results have been reported for both early and immediately loaded implants, these protocols are technique sensitive. Success depends upon many factors, including the achievement of high primary implant stability. This article reviews some recent studies relating to initial implant stability and presents a protocol to obtain high primary stability for immediately loaded implants. A clinical case illustrating the protocol is presented.

Key Words: primary stability, immediate loading, tapered implants, implant stability

Introduction

Many factors explain the growing popularity of immediate loading protocols. Patients appreciate being able to shorten the overall length of implant treatment and reduce the number of procedures they must undergo in order to obtain fixed implant prostheses. Full-arch immediate loading enables patients to function with non-removable implant prostheses within one to two days of tooth extraction, eliminating the need to experience any period of edentulism with complete dentures. For the implant team, immediate occlusal loading offers multiple benefits including greater cost-effectiveness, fewer post-operative patient visits,¹ and higher referral rates for surgeons.

The original Brånemark protocol called for relatively long (three to six months) unloaded healing intervals because it

was thought that placing occlusal loads onto implants prior to osseointegration could lead to fibrous tissue encapsulation rather than direct bone apposition.²⁻³ Support for lengthy unloaded post-surgical periods also was bolstered by the belief that necrotic bone in implant osteotomies needed to be replaced by new bone before any loads could be tolerated.⁴

In 1979 Ledermann published results associated with successful healing for immediately loaded endosseous implants;⁵ multiple researchers and clinicians subsequently reported similar results.⁶⁻¹³ In 2007, a systematic Cochrane review of 11 randomized controlled trials that compared outcomes for early or immediately loaded implants to outcomes for conventionally loaded implants found no statistically significant differences for any of the meta-analyses.¹⁴ Histomorphometric analyses of retrieved, immediately loaded endosseous implants have demonstrated that immediate loading does not impede osteogenesis and bone remodeling.¹⁵⁻¹⁸ Peri-implant bone and soft-tissue levels around healed, immediately loaded implants also do not appear to differ from those found around traditionally loaded implants.¹⁹

Despite the broad body of evidence validating the

¹ Tiziano Testori, DDS, MD, FICD. Assistant Clinical Professor and Head of the Section of Implant Dentistry and Oral Rehabilitation, Department of Odontology, at the University of Milan, I.R.C.C.S., Galeazzi Institute (Chairman Prof. R.L. Weinstein), in Milan, Italy. He has authored numerous publications and a textbook on immediate loading. He maintains a private practice specializing in implant dentistry in Como, Italy. His website is www.implantologiaitalia.it.

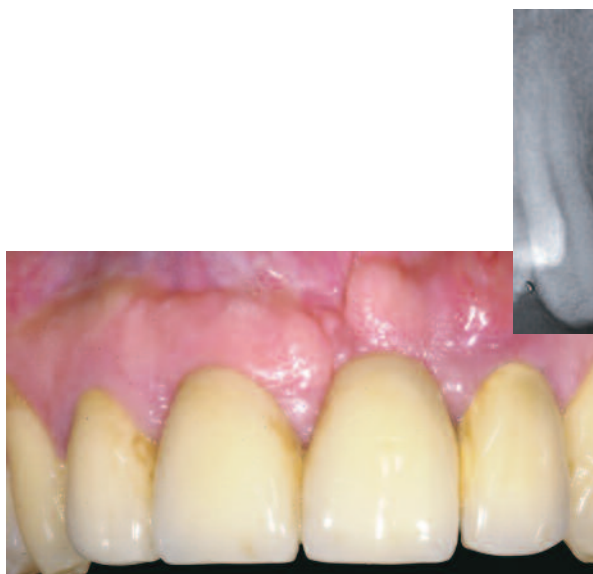

Figure 1: Pre-operative clinical photograph.

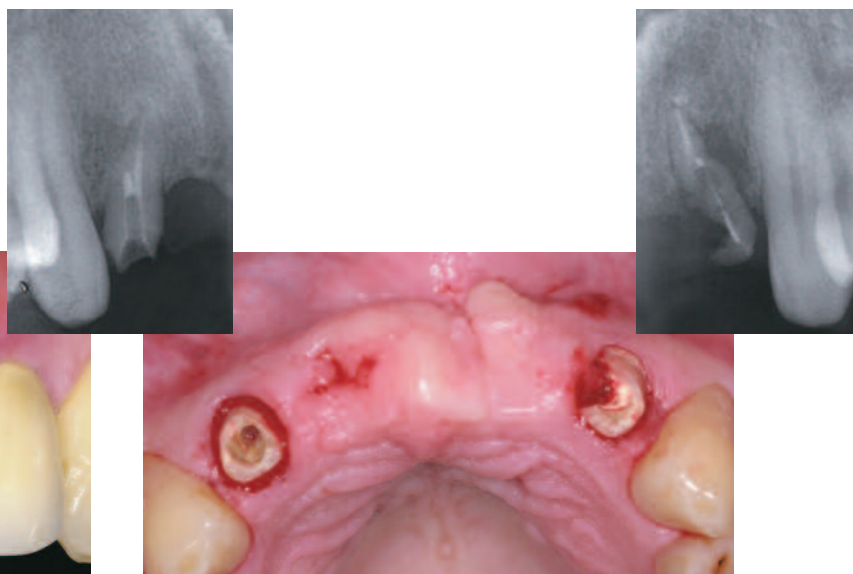


Figure 2: After removal of the patient's failing FPD, periapical radiographs (inset) revealed that one lateral incisor was fractured the other one unsalvageable from the restorative point of view.

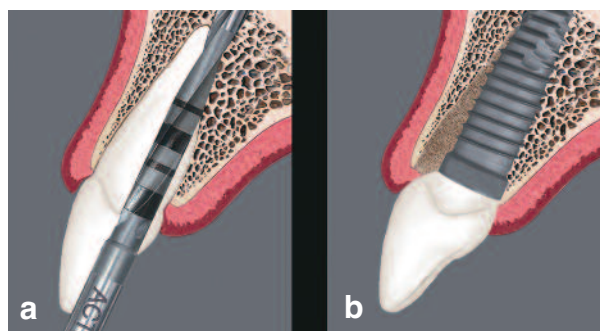


Figure 3a: A 2mm diameter twist drill was positioned against the palatal wall of the pre-existing socket.
Figure 3b: Illustration of a properly positioned tapered implant within the prepared osteotomy/socket.

predictability of immediate loading in carefully selected patients, some studies have reported higher failure rates with an immediate-loading approach, as compared to a staged approach for implant placement.^{10,20-22} However, it should be noted that some of these findings related to machine-surfaced implants^{10,20} and others related to single implants.^{21,22} This suggests that immediate loading is technique sensitive and should be applied to patients with caution.

Achieving High Primary Stability

Crucially important to immediate occlusal loading is achieving high primary implant stability. Primary stability must be sufficient to allow implants to resist micromovement until adequate biologic stability has been established.²³ For roughened implant surfaces, research has demonstrated that the tolerable range of micromotion is between 50 and 150 μm .²⁴

A number of recent studies have shed light on various aspects of initial implant stability. In 2009 Rozé et al,²⁵ investigating a possible correlation between bone micro-architecture and primary implant stability, placed 22 implants in human cadaver maxillae and mandibles for which the bone structure had been determined pre-operatively by computed tomography (CT). Primary implant stability was measured by resonance frequency analysis; Ostell ISQ values ranged from 50 to 70. No correlation was found between the ISQ values and the trabecular bone histomorphometrical parameters. Instead, the authors concluded that primary implant stability is correlated to the cortical thickness around implants, which can be assessed with standard clinical CT scans.

O'Sullivan et al²⁶ compared the primary implant stability of five implants: Nobel Biocare's Standard threaded, Mark II self-tapping, and Mark IV tapered self-tapping implants (Nobel Biocare AB, Gothenburg Sweden), the Astra

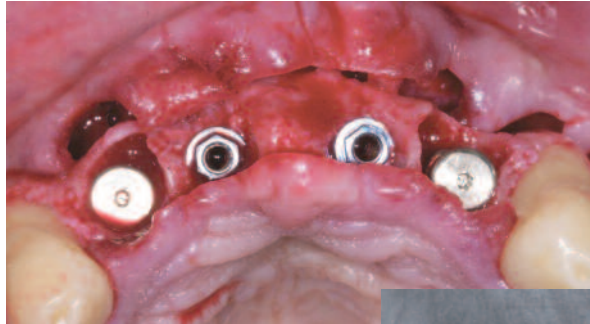

Figure 4: *Implants were placed in the central and lateral incisor positions.*

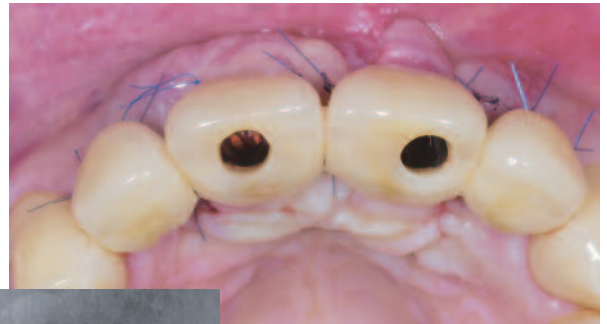

Figure 5: *Occlusal view of the laboratory-fabricated screw-retained provisional restoration placed one day after implant placement.*

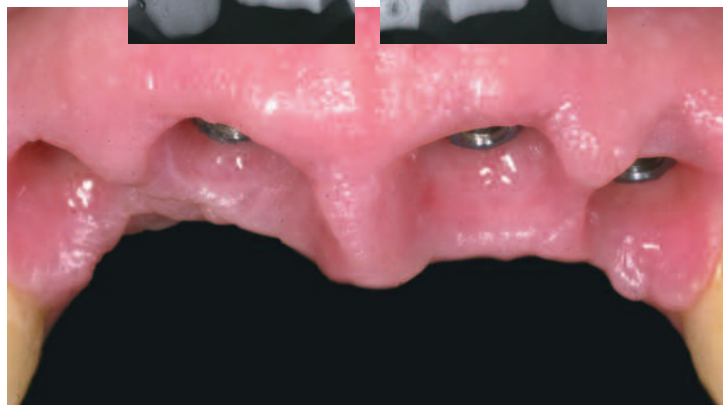
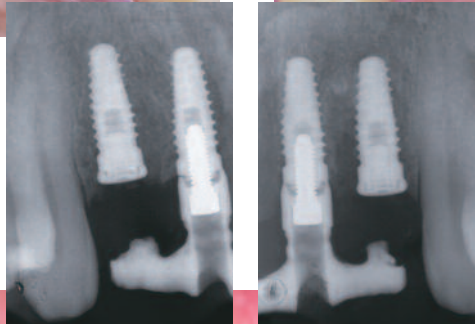


Figure 6: *Six months later, the lateral incisor implants were uncovered. Soft-tissue healing occurred, and the patient presented for impressions.*

Tioblast (AstraTech AB, Mölndahl, Sweden), and the BIOMET 3i OSSEOTITE® (BIOMET 3i, Palm Beach Gardens, FL, USA) Implant. Fifty-two implants were placed into maxillary bones of nine unembalmed human cadavers; peak-insertion-torque, resonance-frequency, and removal-torque values were recorded at each implant placement site. Qualitative assessments of bone quality at each site were also made. The authors found that all implants demonstrated good primary stability in Type II and III bone, but the Standard, Mark II, OSSEOTITE, and Tioblast implants were less stable when placed into Type IV bone. The authors concluded that tapered implants exhibited higher insertion torques than cylindrical implants, as well as significantly higher resonance-frequency values, which indicated a higher interfacial stiffness at the implant-bone interface.

Turkylmaz et al,²⁷ using smaller-diameter drills to enhance primary implant stability, placed 60 implants into

the posterior maxillae of 22 patients and recorded bone densities (as determined with computerized tomography), maximum insertion torque, and resonance-frequency analysis results. Strong correlations were observed between bone density, insertion torque, and implant stability values at implant placement. The authors concluded that using smaller diameter drills for implant placement in posterior maxillae, where bone quality is generally poor, may improve primary implant stability.

Ottoni et al²⁸ placed 46 Frialit-2 implants into 23 patients and restored these within a 24-hour period with provisional crowns designed to receive occlusal masticatory loads. A minimum insertion torque of 20Ncm was achieved. This approach was compared to a control group of implants restored after a healing period. After a 24-month data-collection period, the experimental group included 10 failed implants, nine of which had been placed with an insertion torque of 20Ncm. Only one implant from the

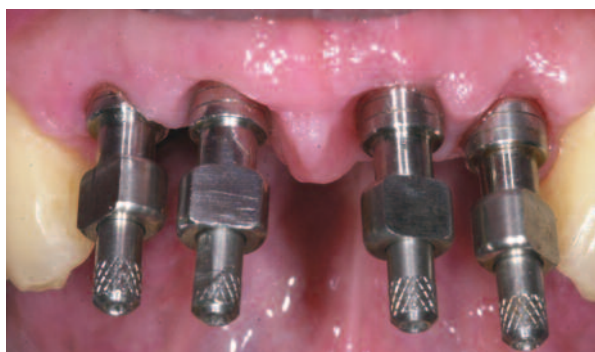

Figure 7: Eight weeks after uncovering, implant pick-up impression copings were placed onto the implants.

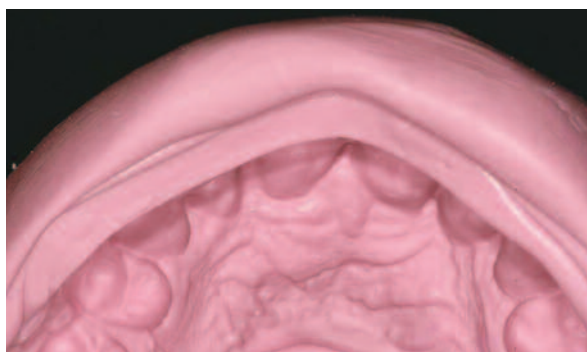


Figure 8: A silicone mold of the provisional restoration was used to create the second provisional restoration as well as the definitive restorations.

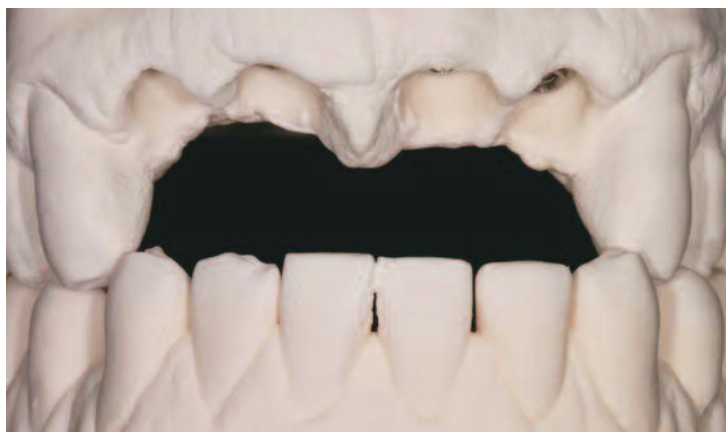

Figure 9: Anterior view of the mounted master casts.

control group failed during the same period. The survival rate was independent of implant length, site position, and bone quality and quantity. Relative risk for implant failure was associated with insertion torque in the experimental group but was not significant for the control group. To achieve osseointegration, it was found that an insertion torque above 32Ncm was necessary. The authors' low insertion torque (20Ncm) was associated with increased potential for loss, which could be decreased by 20% per every additional 9.8Ncm of insertion torque.

In 2009, Neugebauer et al²⁹ investigated seven different surgical motors, measuring torque during typical surgical and prosthetic procedures using a special load-transfer mechanism for a torque gauge. For each setting, 30 measurements were made and means were calculated. The authors concluded that the highest percentage shortfall was 20.5% at a set torque of 11.4Ncm (absolute deviation, 2.4Ncm). The highest percentage by which a torque was exceeded was 54.6% (absolute deviation, 5.5Ncm). The

lowest value for absolute shortfall was found to be -5.6Ncm at a set torque of 45Ncm. The highest absolute value exceeded was 15Ncm at a set torque of 40Ncm. Potentially problematic torque values were identified in the low torque-value setting, as the implant position may be changed if a drilling unit applies excessive torque to a healing abutment or cover screw. In addition, torque values above the critical value of 50Ncm may be applied unwittingly while working with a set torque of 40Ncm. The authors concluded that although surgical motors for implant treatment demonstrated acceptable torque measurements for implant procedures, annual or chairside calibration with a standard handpiece is recommended in order to apply consistent quantities of torque and reduce implant failure rates.

Trisi et al³⁰ in 2009 designed a study to determine whether micromotion at the implant/bone interface was related to primary implant stability achieved with increasing insertion torque values. A total of 120 Ti-Bone implants



Figure 10a: The silicone mold was fitted onto the land area of the cast (over the ZiReal® Posts). This identified the amount of reduction needed.

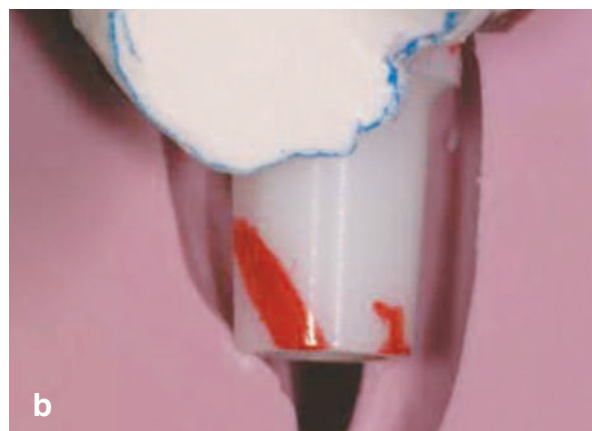

Figure 10b: A red marking pen was used to indicate the locations of the planned reductions on the abutment.

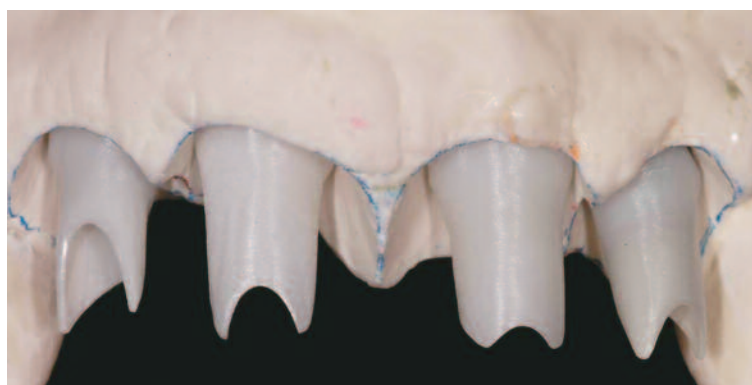

Figure 11: The prepared abutments in place on the master cast. These were prepared consistent with the contours of the provisional restoration.

were placed into three categories of fresh bovine bone samples: hard, normal, and soft. Five groups of peak insertion torque values (20, 35, 45, 70 and 100Ncm) were evaluated in each bone density category. A loading device consisting of a digital force gauge and a digital micrometer was used to measure the implants' micromovement during the application of 20, 25, and 30Ncm lateral forces. The authors found a statistically significant difference between implant micro-mobility placed with different levels of torque and in different bone densities. In soft bone, it was not possible to achieve more than 35Ncm of peak insertion torque. The authors concluded that increasing peak insertion-torque values reduced implant micromotion within the osteotomies. In addition, micromotion in soft bone was found to be consistently high, which could lead to failures relative to osseointegration.

In light of such research and the author's 21 years of

clinical experience in implantology and 30 years in practice, the author has developed a protocol for achieving high primary stability for immediately loaded implants.

The protocol includes:

- Identifying the quality and quantity of available bone
- Using an implant with optimal macro- and micro-geometry
- Paying attention to biology and biomechanics
- Undersizing osteotomies and preparing these precisely for placement of tapered implants
- Matching the drilling sequence to the bone type
- Understanding the surgical instrumentation
- Understanding the instruments available for determining primary stability at the time of implant placement
- Performing the surgical procedure accurately; paying attention to details

Additionally, the author considers two-handed guidance of the handpiece to be critical for successful implant

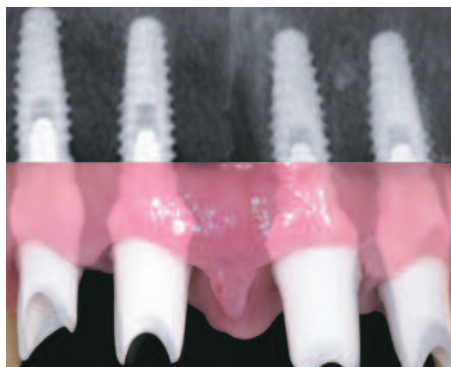

Figure 12: Composite image of the prepared ZiReal® Posts in place on the implants. Note that the margins of the abutments were subgingival.

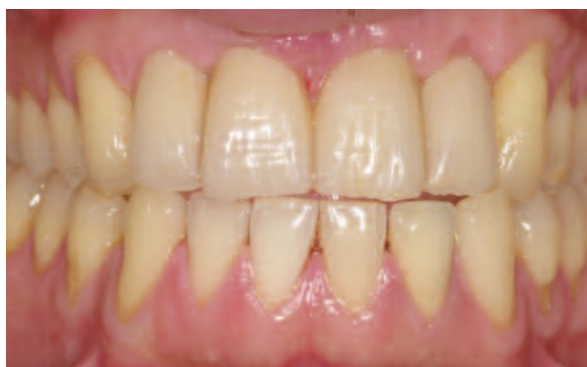

Figure 13: Clinical photograph of the definitive restorations in place.

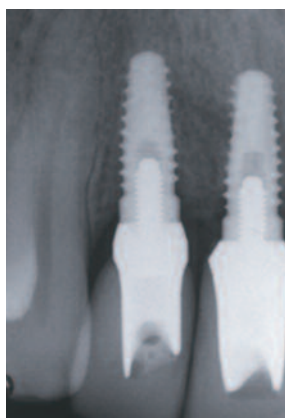
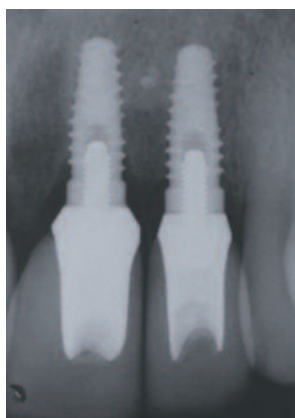
Figure 14: Post-restorative periapical radiographs show minimal bone remodeling around the implants, more than one year after placement.

osteotomy preparation and implant placement in difficult cases. One hand should be maintained on the head of the handpiece and significant apical force should be used to maintain control of the drills. The angulation of the handpiece and drill should be monitored continually during both guided and non-guided surgeries. The author always uses a bone tap in dense bone prior to placing an implant into an osteotomy.

Clinical Case Presentation

The following case illustrates an application of this protocol. The patient, a 35-year-old male, presented with a failing maxillary anterior fixed partial denture that had replaced his central incisors in the wake of their traumatic evulsion (Figure 1). Clinical examination of the two lateral incisors, which supported the prosthesis, found that the right one had a vertical root fracture, while the left one had

suffered a major endodontic failure (Figure 2). Intraoral radiographs (insets) and a CT scan of the edentulous ridge revealed that the bone quality was Type II, and the vertical and buccolingual dimensions were adequate to accommodate placement of implants. Moreover, approximately 33mm of intercuspid prosthetic space was available – more than enough to allow for an optimal inter-implant distance.

The patient provided informed consent for a treatment plan that called for immediate loading of two implants to be placed in the central incisor positions and delayed loading for two implants placed in the lateral incisor positions. Impressions were made, and a wax-up was obtained for fabrication of a fixed provisional restoration and a surgical template.

The two lateral incisors were atraumatically extracted, and a full-thickness mucoperiosteal flap was elevated.

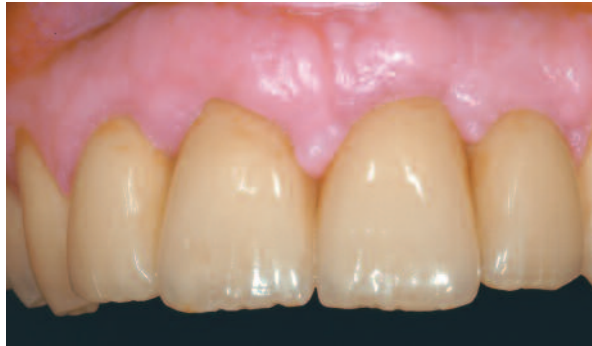

Figure 15: Clinical photograph of the definitive restoration after more than eight years follow-up. Note the stability of the peri-implant soft tissues.

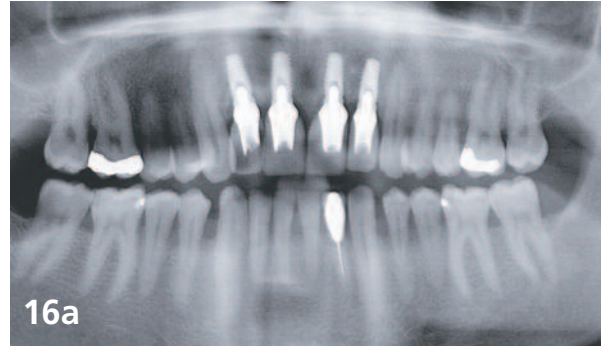
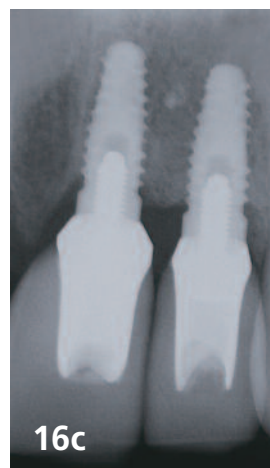
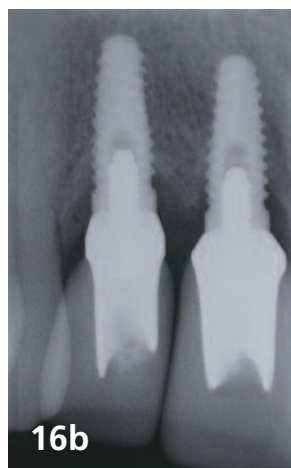


Figure 16a-b-c: Orthopantomograph and periapical radiographs eight years and five months post loading (implant placement January 2002) of the peri-implant soft tissues.



Osteotomies were created in the positions indicated by the surgical guide. At the two extraction sites, instead of following the long axis of each socket, the bur was positioned against the palatal wall and aligned with the cingulum of the future restoration. Following these directions, the initial osteotomy began 5mm to 7mm more apically from the soft-tissue contour on the palatal side (Figures 3a and 3b).

Four 4.0mm x 11.5mm OSSEOTITE® Natural Tapered Implants (BIOMET 3i) were placed, and cover screws were placed on the two lateral implants (Figure 4). Positioning the two lateral incisor implants into the bone on the palatal wall of the extraction sites resulted in a small gap between each implant and the labial plate. In order to establish a thicker, more stable labial wall that would better resist bone resorption, the gaps were filled with autogenous bone collected from the flutes of the shaping drills.

Transfer assemblies were connected to the two central incisor implants. After temporarily suturing the flap, an

impression was made. The sutures were then removed around the two central incisor implants, and a bone dehiscence on the buccal plate of the right implant was grafted. A resorbable collagen membrane was placed on that implant, and a connective tissue graft harvested from the palatal area was also used to cover the expanded buccal contours.

To prevent collapse of the soft tissue until delivery of the provisional prosthesis the following day, wide healing abutments were placed on the two central incisor implants and tightened to 10Ncm. These were removed the next day, and a metal-reinforced provisional restoration with cantilevered lateral incisors was screw-retained to the two central incisor implants and checked to ensure the absence of centric and eccentric contacts (Figure 5). The patient was instructed not to masticate on the provisional restoration for at least eight weeks.

Six months later, the two lateral incisor implants were exposed in a flapless procedure. Measurement of the

implant-stability quotient by resonance frequency analysis confirmed secondary osseointegration of all four implants. After a gingivoplastic procedure was carried out to smooth the soft-tissue contours, the provisional restoration was reconnected to the two central incisor implants.

The soft tissue was allowed to heal for an additional eight weeks, and then the patient presented for implant-level impressions (Figure 6). The soft-tissue contours were established by the contours of the provisional restoration. Implant-level impressions were made (Figure 7); the diagnostic cast of the provisional restoration was to be used as a reference in fabricating the definitive restoration (Figure 8). A master cast was created and mounted in the correct jaw relationship (Figure 9). Teeth were waxed, and ZiReal® Posts (BIOMET 3i) were placed onto the master cast (Figures 10a and b) and modified to conform to the shape of the desired restoration emergence profiles (Fig. 11). The prepared modified posts were placed onto the implants and secured with retaining screws tightened to 32Ncm (Fig. 12), and the provisional restoration was cemented to the posts. Six months later, after maturation of the soft tissues, the second provisional restoration was removed, and four definitive all-ceramic crowns (IPS Empress 2, Ivoclar Vivadent, Amherst, New York, USA) were cemented in place (Fig. 13). Periapical radiographs taken during this visit, more than a year after implant placement, showed minimal peri-implant bone remodeling (Fig. 14).

After more than eight years of follow-up, the peri-implant soft tissues and the bone levels remain stable (Figs. 15 and 16a-c).

Clinical Relevance

Among the conditions necessary to enable successful immediate occlusal loading, one of the most crucial is high primary stability for newly placed implants. Adherence to the following recommendations is suggested:

- Identify the quality and quantity of available bone for each implant site.
- Use an implant with optimal macro- and microgeometry.
- Pay attention to biology and biomechanics.
- Undersize osteotomies and prepare them precisely for placement of tapered implants.
- Match the drilling sequence to the bone type.
- Understand the surgical instrumentation.
- Understand the instruments available for determining primary stability at the time of implant placement.
- Perform the surgical procedure accurately;
- Pay attention to details.

References

1. Chee W, Jivraj S. Efficiency of immediately loaded mandibular full-arch implant restorations. *Clin Oral Impl Dent* 2003;5:52-56.
2. Albrektsson T, Brånemark P-I, Hansson HA et al. Osseointegrated titanium implants: Requirements for ensuring a long-lasting direct bone to implant anchorage in man. *Acta Orthop Scand* 1981;52:155-170.
3. Albrektsson T, Hansson HA, Lekholm U. Osseointegrated dental implants. *Dent Clin North Am* 1986;30:151-174.
4. Brånemark P-I, Hansson BO, Adell R et al. Osseointegrated implants in the treatment of the edentulous jaw. Experience from a 10-year period. *Scand J Plast Reconstr Surg Suppl* 1977;16:1-132.
5. Ledermann PD. Stegprothetische Versorgung des zahnlosen Unterkiefers mit Hilfe plasmabeschichteten Titanschraubimplantaten. *Deutsche Zahnärztliche Zeitung* 1979;34:907-911.
6. Schroeder A, Maeglin B, Sutter F. Das ITI-Hohlzylinderimplantat Typ F zur Prothesenretention beim zahnlosen Kiefer. *Schweizerische Monatschrift für Zahnheilkunde* 1983;93:720-733.
7. Babbush CA, Kent J, Misick D. Titanium plasma-sprayed (TPS) screw implants for the reconstruction of the edentulous mandible. *J Oral Maxillofac Surg* 1986;44:274-282.
8. Schnitman P, Wöhrle PS, Rubenstein JE. Immediate fixed interim prostheses supported by two-stage threaded implants: methodology and results. *J Oral Implantol* 1990;2:96-105.
9. Balshi TJ, Wolfinger GH. Immediate loading of Brånemark implants in edentulous mandibles: a preliminary report. *Implant Dent* 1997;6:83-88.
10. Schnitman P, Wöhrle PS, Rubenstein JE et al. Ten years results for Brånemark implants immediately loaded with fixed prostheses at implant placement. *Int J Oral Maxillofac Implants* 1997;12:495-503.
11. Tarnow DP, Emtiaz S, Classi A. Immediate loading of threaded implants at stage 1 surgery in edentulous arches: ten consecutive case reports with 1- to 5-year data. *Int J Oral Maxillofac Implants* 1997;12:319-324.
12. Wöhrle PS. Single-tooth replacement in the aesthetic zone with immediate provisionalization: fourteen consecutive case reports. *Pract Periodont Aesthet Dent* 1998;10:1107-1114.
13. Brånemark P-I, Engstrand P, Öhrnell L-O et al. Brånemark Novum: A new treatment concept for rehabilitation of the edentulous mandible. Preliminary results from a prospective clinical follow-up study. *Clin Implant Dent Relat Res* 1999;1:2-16.
14. Esposito M, Grusovin MG, Willings M et al. Interventions for replacing missing teeth: different times or loading dental implants. *Cochrane Database Syst Rev* 2007 Apr 18;(2):CD003878.
15. Linkow LI. Retrieved analysis of a blade implant after 231 months of clinical function. *Implant Dent* 1992;1:37-43.
16. Piatelli A, Corigliano M, Scarano A et al. Bone reactions of early occlusal loading of two-stage titanium plasma-sprayed implants: A pilot study in monkeys. *Int J Periodont Restorative Dent* 1997;17:163-169.
17. Piatelli A, Paoloanonio M, Corigliano M et al. Immediate loading of titanium plasma-sprayed screw-shaped implants in man: A clinical and histological report of 2 cases. *J Periodontol* 1997;68:591-597.
18. Testori T, Szmukler-Moncler S, Francetti L et al. Immediate loading of Osseotite implants: A case report and histologic analysis after 4 months of occlusal loading. *Int J Periodontics Restorative Dent* 2001;21:451-459.
19. Galli F, Capell M, Zuffetti F et al. Immediate non-occlusal vs.

early loading of dental implants in partially edentulous patients: a multicentre randomized clinical trial. Peri-implant bone and soft-tissue levels. Clin Oral Impl Res 2008;19:546-552.

20. Ericsson I, Nilson H, Lindhe J et al. Immediate functional loading of Brånemark single tooth implants. An 18-months' follow-up study. Clin Oral Impl Res 2000;11:26-33.

21. Jaffin RA, Kumar A, Berman CL. Immediate loading of implants in partially and fully edentulous jaws: a series of 27 case reports. J Periodontol 2000;71:833-838.

22. Chaushu G, Chaushu S, Tzohar A et al. Immediate loading of singletooth implants: immediate versus non-immediate implantation. A clinical report. Int J Oral Maxillofac Implants 2001;16:267-272.

23. Szmukler-Moncler S, Salama H, Ringewirtz Y et al. Timing of loading and effect of micro-motion on bone-implant interface: A review of experimental literature. J Biomed Mat Res 1998;43:192-203.

24. Szmukler-Moncler S, Piattelli A, Favero G et al. Considerations preliminary to the application of early and immediate loading protocols in dental implantology. Clin Oral Impl Res 2000;11:12-25.

25. Rozé J, Babu S, Saffarzadeh A et al. Correlating implant stability to bone structure. Clin Oral Implants Res 2009;20(10):1140-5.

26. O'Sullivan D, Sennerby L, Meredith N. Measurements comparing the initial stability of five designs of dental implants: a human cadaver study. Clin Implant Dent Relat Res 2000;2(2):85-92.

27. Turkyilmaz I, Aksoy U, McGlumphy EA. Two alternative surgical techniques for enhancing primary implant stability in the posterior maxilla: a clinical study including bone density, insertion torque, and resonance frequency analysis data. Clin Implant Dent Relat Res 2008;10(4):231-237.

28. Ottoni JMP, Oliveira ZFL, Mansini R et al. Correlation between placement torque and survival of single-tooth implants. Int J Oral Maxillofac Implants 2005;20:769-776.

29. Neugebauer J, Scheer M, Mischkowski RA et al. Comparison of torque measurements and clinical handling of various surgical motors. Int J Oral Maxillofac Implants 2009;24(3):469-476.

30. Trisi P, Perfetti G, Baldoni E et al. Implant micromotion is related to peak insertion torque and bone density. Clin Oral Implants Res 2009;20(5):467-471. Laboratory Colleague: Marco Cossu, MDT, Lugano, Switzerland.

Acknowledgements

We would like to thank the Restorative Colleague Jorg M. Ritzmann, DDS, Milano, Italy, and Anita Daniels and Carl Drago, DDS for editing this paper.

Reprinted with permission from JOURNAL OF IMPLANT AND RECONSTRUCTIVE DENTISTRY® 2010 Vol. 2 No. 1