

# Implant-supported overdenture options for the edentulous patient

Lyndon Cooper,<sup>1</sup> Arnold Rosen,<sup>2</sup> Ibrahim Duqum<sup>3</sup>

## Abstract

**Patients:** Three cases demonstrating three different approaches for the treatment of fully edentulous patients.

**Challenge:** The treatment of the fully edentulous patient can be a challenging one due to the diversity of the group in terms of initial clinical, medical and anatomical pre-condition, economic situation and overall expectation of the treatment outcome.

**Treatment:** There is a wide range of approaches that can be utilized for the treatment of edentulous patients, which are dramatically different from a technical and economic standpoint. Each is able to successfully address the need of the individual patient and positively impact their health and quality of life.

## Introduction

Edentulous patients are a diverse group comprised of those who are anatomically deficient, medically compromised, economically depressed, geriatric, congenitally deformed, genetically affected, as well as the general population that, for a number of other reasons, have been rendered edentulous.

With the continued advancements in dental implant therapy, it is becoming increasingly easier for the clinician to provide treatment solutions that can effectively meet functional, economic and social expectations of each individual patient.

## Case I: Mandibular, two implants with Locator™ Abutments

An elderly, female patient presents with a recently-made, complete lower denture. Her chief complaints included difficulty with denture stability and chronic sores as a result. In consideration of her expectation of improved stability and the need for an economically-feasible treatment option, a retro-fitted denture on two implants option was presented and accepted.

<sup>1</sup> Lyndon Cooper, DDS, PhD; Stallings Distinguished Professor of Dentistry, Department of Prosthodontics, University of North Carolina at Chapel Hill, USA

<sup>2</sup> Arnold Rosen, DDS, Private Practice, Boston, MA, USA

<sup>3</sup> Ibrahim Duqum, BDS, MS, Assistant Professor, Department of Prosthodontics, University of North Carolina at Chapel Hill, USA

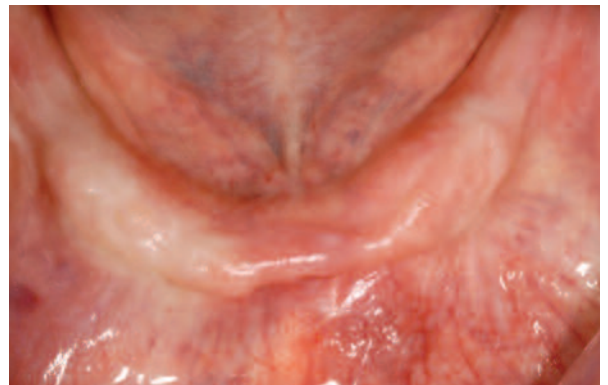


Figure 1A: Edentulous patient presents with complaints of chronic sores and difficulty eating.

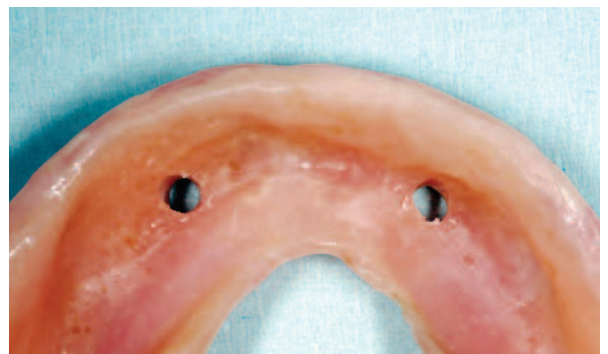
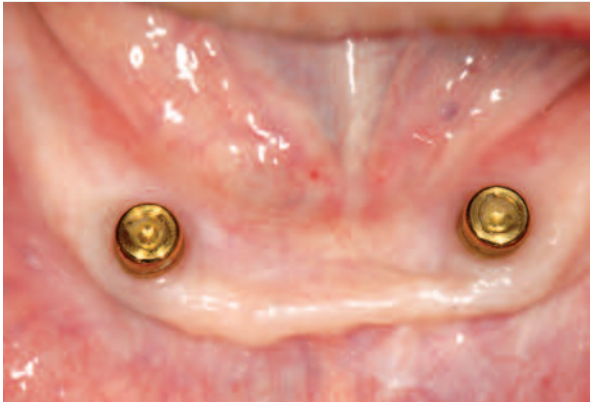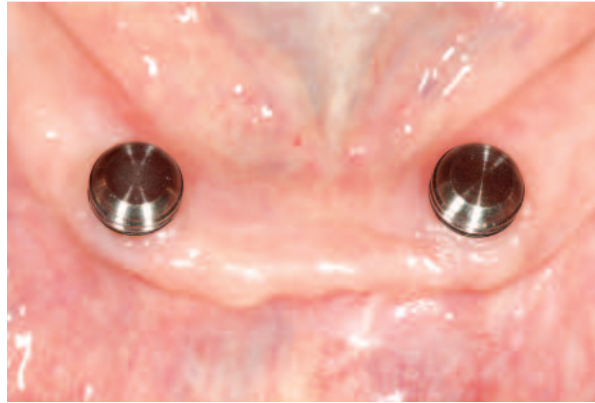


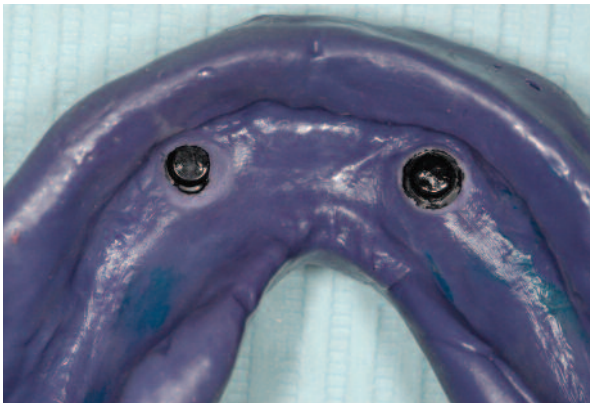Figure 1B: The complete denture is used as a surgical guide and then retro-fitted to provide an economical implant-supported overdenture.



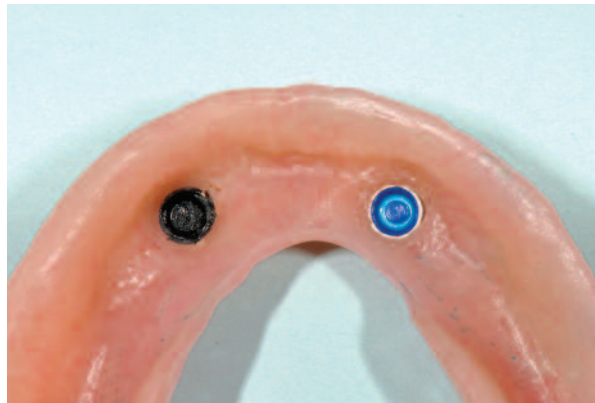*Figure 1C: Following implant placement, Locator Abutments are selected for an abutment finish line of 1 to 2 mm above the crest.*



*Figure 1D: Locator Processing Cap in place.*



*Figure 1E: An impression is made with the denture in occlusion to reline the complete lower denture and to capture the Locator Processing Cap.*

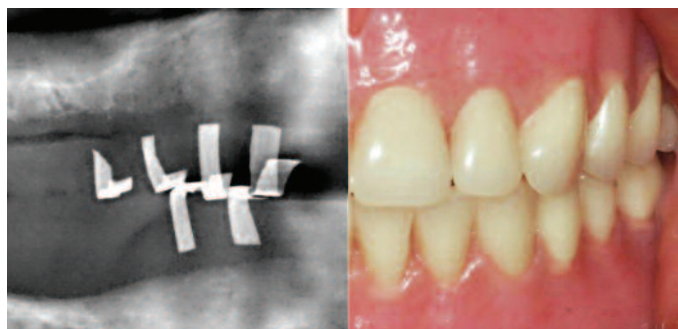


*Figure 1F: The processing elements are replaced with retentive Locator Inserts to provide the patient with a comfortable and stable prosthesis that provides improved function.*

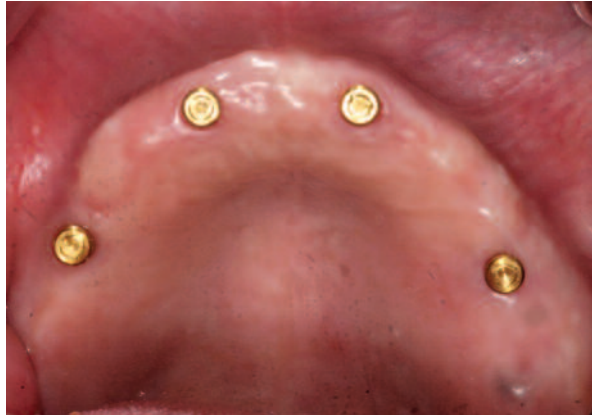The complete original denture is used as a surgical guide. Following implant placement, two Locator Abutments are placed. An impression is made to reline the complete lower denture and to capture the Locator™ Processing Cap with the denture in occlusion. Care is taken to ensure that the denture is not in contact with the Processing Cap. The processing elements are replaced with Locator™ Inserts.

### **Case II: Maxillary, four implants with Locator™ Abutments**

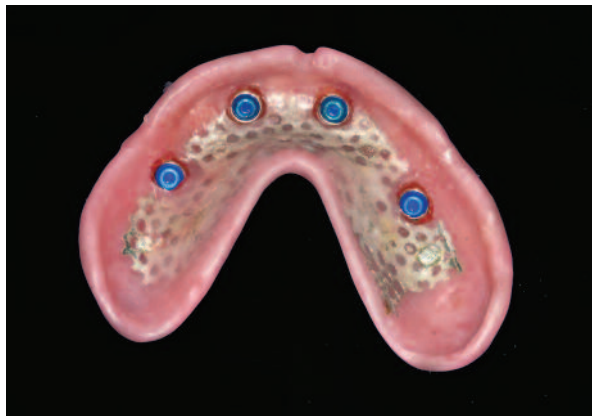Middle-aged, male patient presents for the treatment of an edentulous maxillary arch. The position of the implants are determined by using lead foil strips adherent to overlying teeth within the new prosthesis. The use of a surgical guide is also critical to ensure accuracy. Following



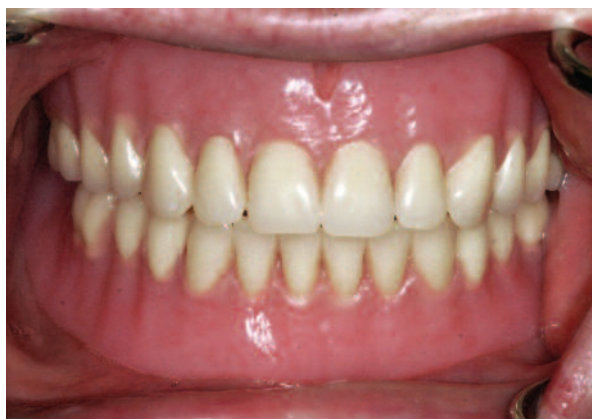*Figure 2A: Panoramic radiograph taken to identify the position of the implants by using lead foil strips adherent to overlying teeth within the prosthesis and the related denture.*



**Figure 2B:** After healing, four Locator Abutments of the appropriate height are inserted at 20 Ncm.



**Figure 2C:** The intaglio surface of the processed maxillary overdenture reveals the Locator abutments and the blue Locator Inserts in place.



**Figure 2D:** Final maxillary overdenture in place meets the functional and esthetic expectations of the patient.

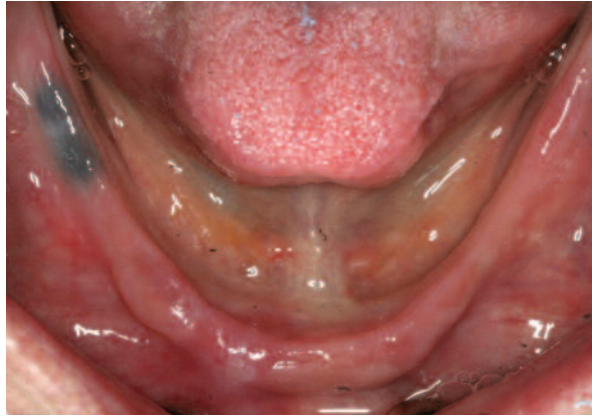a one-stage surgery, four UniAbutments are placed. The new denture is relieved and relined with a soft liner as no contact of the acrylic denture to the abutments should occur during the healing phase. After healing, four Locator Abutments of the appropriate height are inserted at 20 Ncm. A four-implant supported removable overdenture provides ideal stability and allows for easy removal and cleaning of the prosthesis.

### **Case III: Mandibular, fixed solution on four implants**

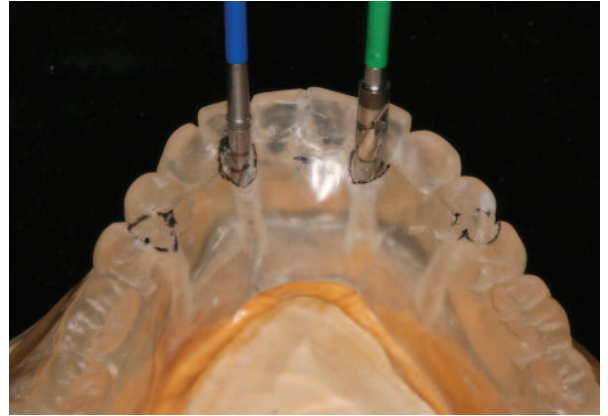
Pre-operative examination revealed a resorbed edentulous mandible of a long-term denture wearer. The patient was dissatisfied with difficulty in eating and discomfort due to the lack of stability of his dentures.

Following creation of a new mandibular denture and duplication of the denture in a radioopaque resin (Biocryl-X; Great Lakes Orthodontics), the patient undergoes a CBCT evaluation and the radioopaque template is subsequently used as a surgical guide. The implants are strategically placed behind incisors and through the mesial aspect of the second pre-molars to assure sufficient anterior-posterior displacement. The full thickness flap approach is commonly employed for these type of cases because alveolectomies are frequently required to account for restorative dimension or to gain adequate ridge thickness. For this particular case, 4.0 mm, 20 degree UniAbutments are used to provide at least 2mm of dimension for formation of biological width in a suprcrestal position and an additional 1.5-2 mm of clearance for adequate hygiene. The abutments also accommodate distal displacement of the implants to gain anterior-posterior spread and contributes to optimizes stability and ensured longevity of the prosthesis.

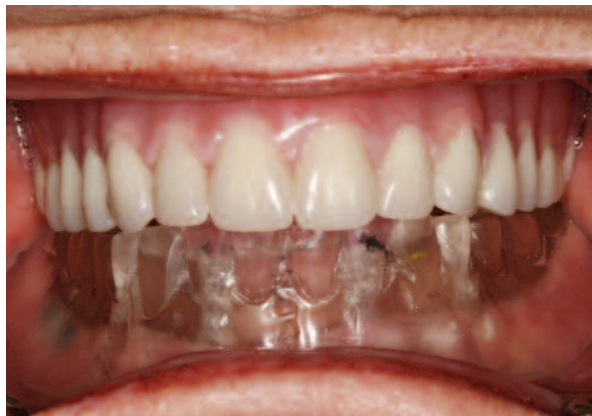*Reprinted with permission from 1/2010 INSIGHT magazine.*



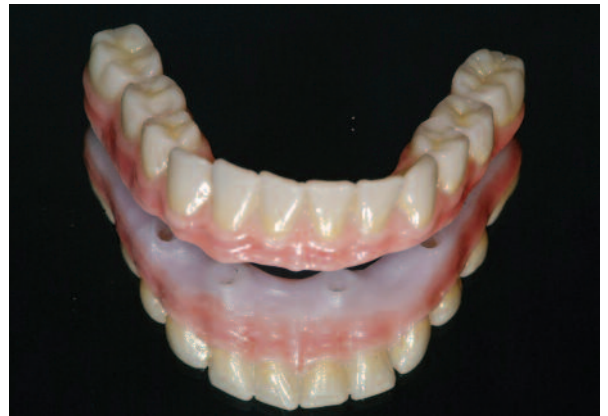**Figure 3A:** Pre-operative clinical presentation reveals a resorbed edentulous mandible.



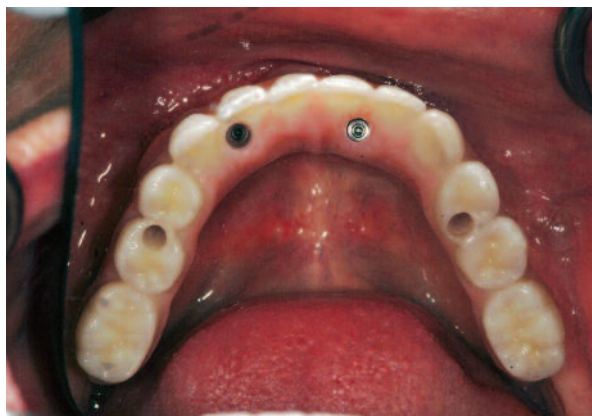**Figure 3B:** A new mandibular denture is duplicated in a radioopaque resin (Biocryl-X; Great Lakes Orthodontics). The radioopaque template is subsequently used as a surgical guide.



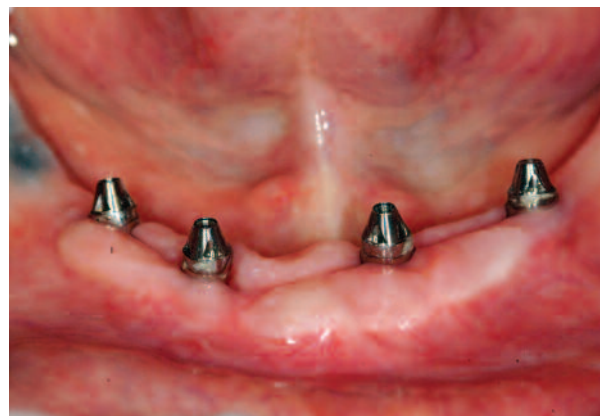**Figure 3C:** The prepared surgical guide should fit accurately on the residual alveolar ridge. The transparent guide must be oriented to the maxillary denture in centric relation.



**Figure 3D:** A monolithic zirconia prosthesis is milled from a copy of the denture (Zircon Zahn).



**Figure 3E:** An occlusal view of the prosthesis immediately following delivery reveals the planned orientation of the implants has been preserved and supports the design of the prosthesis.



**Figure 3F:** The screw access enables periodic removal for hygiene and evaluation of the implants and UniAbutments.