

WaveOne® Gold reciprocating instruments: clinical application in the private practice: Part 2

Peet van der Vyver¹ and Martin Vorster²

Introduction

Recently, the WaveOne® Gold system (Dentsply Sirona) was launched into the dental market. In part one of this series, published in *International Dentistry – African Edition Vol. 7, No. 4*, the authors outlined the clinical guidelines for the use of the Primary WaveOne® Gold instrument for a single-file technique.

The WaveOne® Gold single-file reciprocating system is available in four different file tip sizes in lengths of 21 mm, 25 mm, and 31 mm. The **WaveOne® Gold Small File** has a size ISO 20 tip size and the first 3 mm of the file (D1-D3) has a continuous taper of 7%. **WaveOne® Gold Primary File** has a size ISO 25 tip and the first 3 mm of the file (D1-D3) has a continuous taper of 7%. The **WaveOne® Gold Medium File** has an ISO 35 tip size and the first 3 mm of the file (D1-D3) has a continuous taper of 6%. The last instrument, the **WaveOne® Gold Large File** has an ISO 45 tip size and the first 3 mm of the file (D1-D3) has a continuous taper of 5%.

From D4-D16 each file demonstrates a progressively decreasing percentage tapered design to ensure more flexibility and to preserve more dentin in the body of the prepared root canal to ensure more conservative root canal preparations. (Ruddle, 2015; Webber, 2015).

According to Van der Vyver and Vorster (2017), other benefits of this design characteristic include:

1. The instruments are manufactured using a post-manufacturing thermal process whereby a new phase-transition point between martensite and austenite is identified to produce a file with super-elastic NiTi metal properties. This process gives the file a gold finish with improved mechanical characteristics.
2. The WaveOne® Gold Primary file is 50% more resistant to cyclic fatigue, 80% more flexible and 23% more efficient than the conventional WaveOne® Primary instrument (Dentsply/Maillefer, 2014; Ruddle, 2016; Webber, 2015).
3. WaveOne® Gold files are characterized with a parallelogram off-centered, cross-section. This design limits the engagement between the file and the dentin to only one or two contact points at any given cross-section. This will subsequently reduce taper lock and the screw-effect, improves safety and cutting efficiency and provides more space around the instrument to remove debris coronally during canal preparation (Dentsply/Maillefer, 2014; Ruddle, 2016).
4. The WaveOne® Gold files have shortened 11 mm handles that improve straightline access into the posterior region of the mouth.

The aim of this article is to illustrate the use of WaveOne® Gold instruments in larger diameter root canals, complex and challenging endodontic cases.

¹ Department of Odontology, School of Dentistry, University of Pretoria, Pretoria, South Africa and Private Practice, Sandton, South Africa

² Department of Odontology, School of Dentistry, University of Pretoria, Pretoria, South Africa

Corresponding author

PJ van der Vyver: PO Box 2609, Cresta, 2118. Tel: 011 781 1020. Cell: 082 4104 293. Email: peetv@iafrica.com

Copyright Prohibited

Indications for the use of the WaveOne® Gold Small file (20/07)

The small WaveOne® Gold file is mainly used when the Primary 25/07 file does not passively progress apically or when the operator feels unsecure with the Primary file, after the canal was negotiated to patency and a glide path prepared. It can also be used to start root canal preparation with more safety in certain cases. For example in canals with severe apical curvatures, 'S'-shaped canal configurations, very long root canals or in canals where the glide path preparation was very challenging. When this file reaches working length, the clinician may again accept the canal preparation or alternatively, if more deep shape is required, the canal can be enlarged thereafter with the use of the Primary 25/07 file. The Small file is then considered as a "bridge file" between the Small and Primary file (Ruddle, 2016). Another indication for completing root canal preparation with the Small WaveOne® Gold instrument is in single roots that present with multiple canals in order to eliminate excessive removal of tooth structure with larger instruments.

Case Report 1

The patient, a 35 year old female was referred for a root canal treatment on her mandibular left second molar. The

pulp was exposed after her dentist removed caries under an existing crown. Figure 1 shows a pre-operative periapical radiograph of the tooth.

After access cavity preparation, the canals were negotiated to working length using size 08 and 10 K-files and working length was determined using a Propex Pixi™ electronic apex locator (Dentsply Sirona) and confirmed radiographically. The length determination radiograph revealed that all three root canals have an 'S'-shaped canal configuration (Figure 2). A reproducible micro glide path was prepared in each root canal, before the glide paths were expanded using a ProGlider® (Dentsply Sirona) instrument (Figure 3).

Root canal preparation was initiated with the WaveOne® Gold Primary file in the presence of an irrigation solution (sodium hypochlorite). A brushing motion was utilised to remove coronal interferences and the file was allowed to passively advance inwards and to progress down the canals. As the Primary file reached the first curvature point in each canal resistance was felt. A brushing motion was initiated with the file to create more lateral space, hoping that the file will advance further down the canals. Despite this brushing motion the Primary file still resisted advancing down the canals (Figure 4a). This was a clear indication to use the "bridge file" as the Primary file did not want to progress down the secured glide paths.

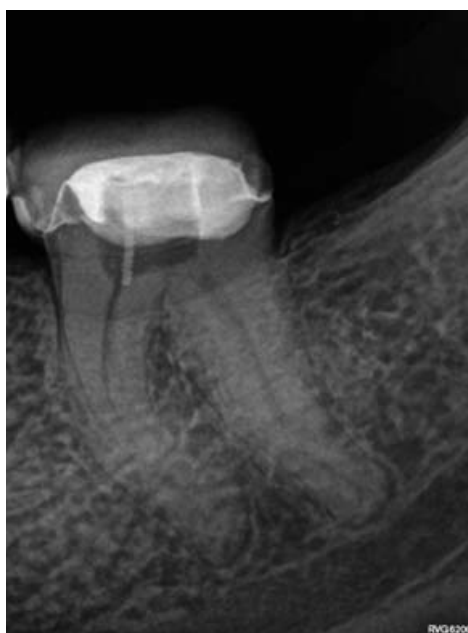

Figure 1. Preoperative periapical radiograph.

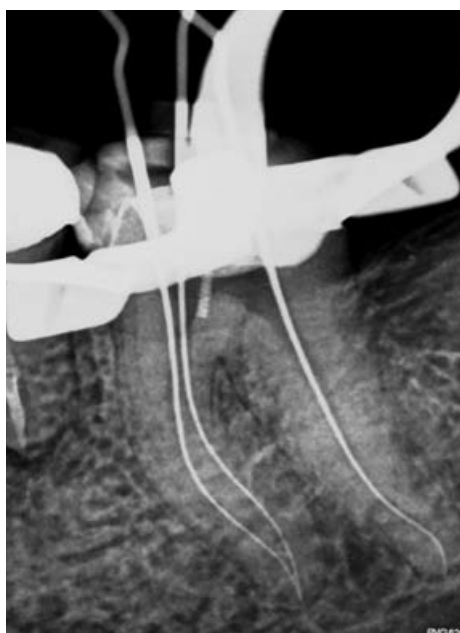


Figure 2: Length determination radiograph. Note the "s"-shaped canal configurations in all three root canals.

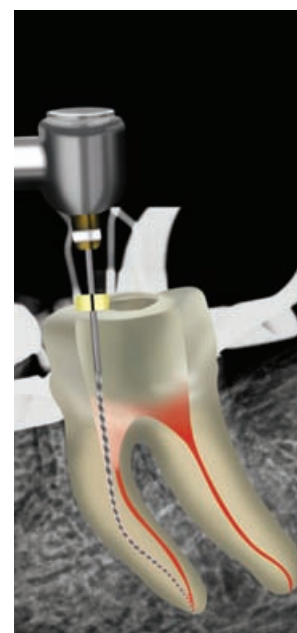


Figure 3: Glide paths were expanded with the ProGlider® instrument.

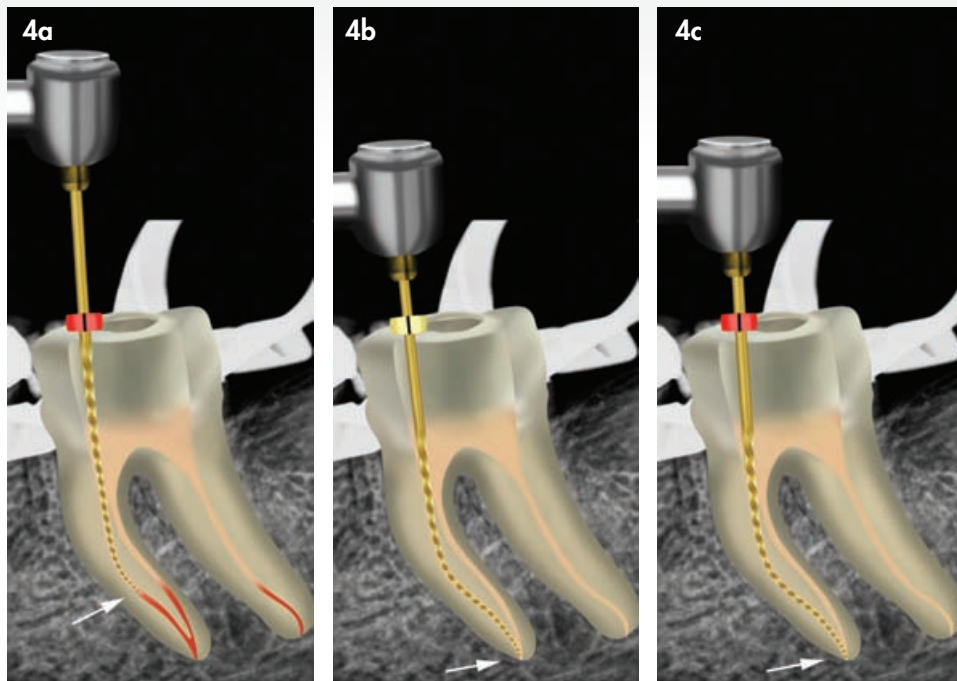


Figure 4: (a) WaveOne® Gold Primary file prepared the canals up to the first curvature point, in each canal before resistance was felt (b) WaveOne® Gold Small file was used to prepare the canals up to working length; (c) The WaveOne® Gold Primary file was used to create more deep shape in the root canals.

A WaveOne® Gold Small file was selected to continue root canal preparation. The file progressed easily without resistance down the canals, through the second curvatures to full working length in all three canals (Figure 4b). In cases where the Small file (20/07) reached working length, the

preparation might be regarded as complete or the if the clinician desire more deep shape, the preparations can be enlarged with the Primary file (25/07)(Figure 4c).

After root canal irrigation with 17% EDTA and 3.5% heated sodium hypochlorite, three WaveOne® Gold Primary Gutta Percha Points (Dentsply Sirona) were fitted and checked radiographically (Figure 5). All three root canals were obturated using the gutta-percha points and Pulp Canal Sealer (Kerr) using the Calamus® Dual Obturation unit (Dentsply Sirona). Figure 6 shows periapical radiograph of the postoperative result after obturation.

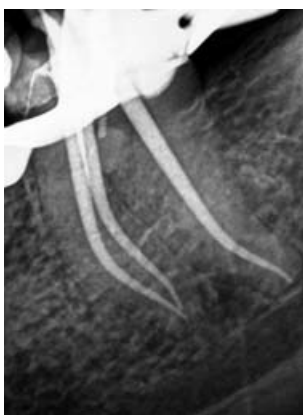

Figure 5: Cone-fit periapical radiograph.

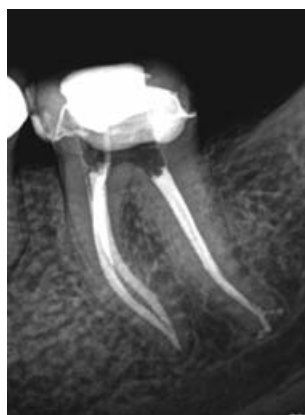

Figure 6: Postoperative periapical radiograph.

Case Report 2

The patient, a 26 year old male presented with a non-vital mandibular right first molar. A pre-operative periapical radiograph revealed a very deep, previously placed Class II composite restoration (Figure 7). After access cavity preparation three root canal systems were detected (two mesial and one distal) and length determination was done (Figure 8). Initial glide path preparation with sizes 08 and 10 K-Files was difficult and challenging due to the S-Shaped canal configuration in the apical 5mm of the two mesial root canals. The glide paths were expanded using a WaveOne®

Gold Glider instrument. Root canal preparation was initiated by taking the WaveOne® Gold Small 20/07 file, up to working length in all three root canals. The root canal preparation was enlarged in the distal root canal with a WaveOne® Gold Primary Small 25/07 file to create more deep shape. Figure 9 depicts the post-operative result after obturation with the Calamus® Dual Obturation System (Dentsply Sirona) using two Small and one Primary WaveOne® Gutta Percha points (Dentsply Sirona) and AH Plus Root canal cement (Dentsply Sirona).

Indications for the use of the WaveOne® Gold Medium file (35/06)

Any canal where a size 20 or 25 K-file fits loose in the canal and is not necessary to negotiate and prepare a glide path with smaller instruments, root canal preparation can be initiated with the WaveOne® Gold Medium file (green ring, 35/06). This will usually include larger diameter, relatively straight root canals. This file can also be used after the Primary file if more shaping is desired or if it is felt that not enough infected dentine was removed from the canal.

Case Report 3

The patient, a 49 year old male presented with a carious exposure on his mandibular left second premolar after caries removal on the bucco-gingival aspect the tooth (Figure 10).

The buccal cavity was restored with Ceram.x® SphereTEC™ one (Dentsply Sirona) composite. An occlusal access cavity was then prepared after the removal of a previously placed Class I restoration. A size 15 K-file was used to explore the canal and to determine working length (Figure 11). It was noted that the size 15 K-file felt very loose in the canal. A size 20 K-file could also be easily taken to working length and a size 25 K-file travelled to working length with resistance. The size 20 K-file confirmed a reproducible glide path in the canal as it could travel easily in the last 4-5 mm from and to working length without any resistance (Figure 12). A WaveOne® Gold Medium file was selected for root canal preparation and the first cutting cycle prepared the canal to 4mm short of working length (Figure 13).

The file was removed from the canal and cleaned, the canal was irrigated, recapitulated and re-irrigated. A second cutting cycle carried the file to full working length (Figure 14). A size Medium WaveOne® Gold Gutta Percha Point was fitted and checked radiographically (Figure 15). After irrigation, the canal was obturated and the occlusal access cavity restored with SDR® a flowable bulk fill resin (Dentsply Sirona) and Ceram.x® SphereTEC™ one composite resin (Dentsply Sirona). Figure 16 shows a post-operative periapical radiograph after obturation and restoration of the tooth, and Figure 17 depicts a clinical view of the restored tooth.

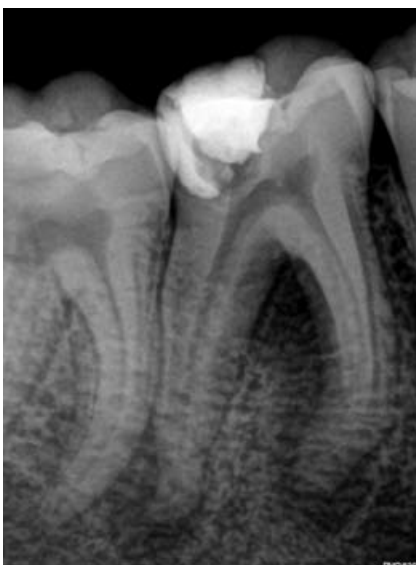

Figure 7: Preoperative periapical radiograph.

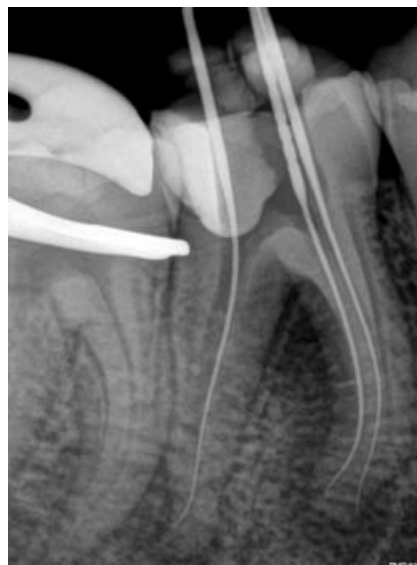

Figure 8: Length determination radiograph. Note the "S"-shaped canal configuration in the apical part of the mesio-lingual root canal system and apical curvature in the mesio-buccal root canal system.

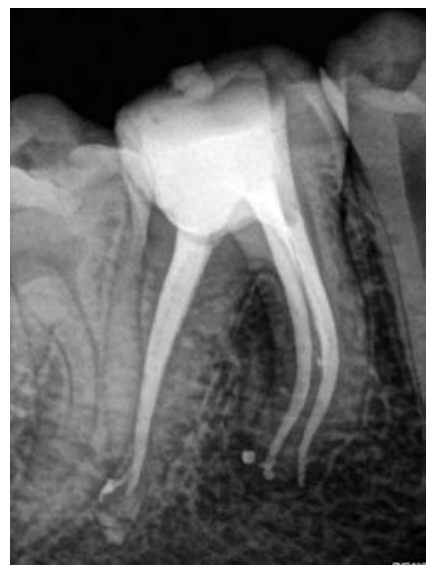

Figure 9: Postoperative periapical radiograph.

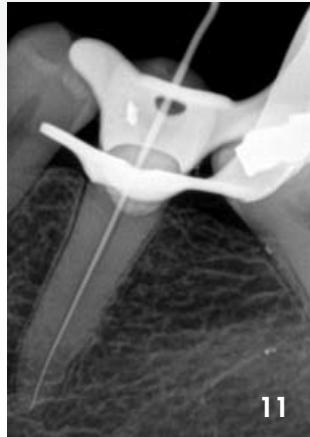
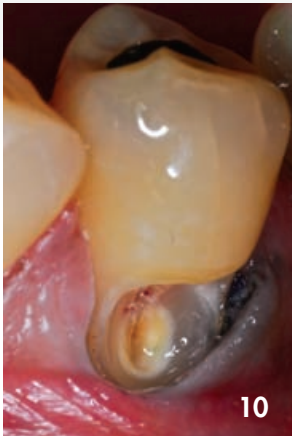
Figure 10: Mandibular left second premolar after caries removal on the bucco-gingival aspect the tooth, exposing the pulp.
Figure 11: Length determination radiograph.

Case Report 4

The patient, a 19 year old male presented with a non-vital mandibular left molar probably caused by a previously placed leaking occlusal restoration (Figure 18). A CBCT scan revealed large periapical areas around the mesial and distal roots (Figure 19). After access cavity preparation, four root canal systems were located (two mesial and two distal). It was noted that the canals were large and a size 20 K-file could be taken easily to full working length. Root canal preparation was done with a single WaveOne® Gold Medium size 35/06 instrument. The canals were irrigated and obturated before the tooth was restored with SDR® (Dentsply Sirona), a posterior bulk fill flowable base material

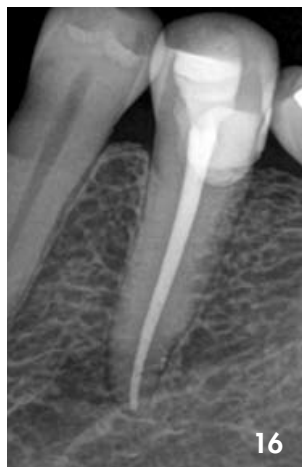
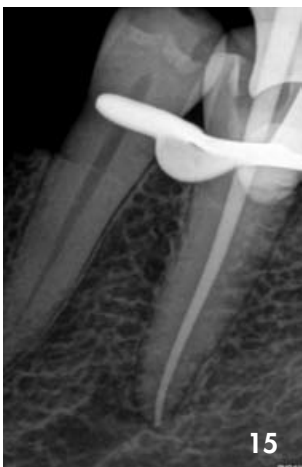
Figure 15: Cone-fit periapical radiograph.
Figure 16: Postoperative periapical radiograph.

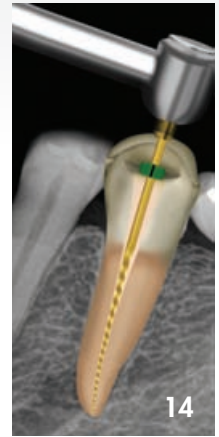
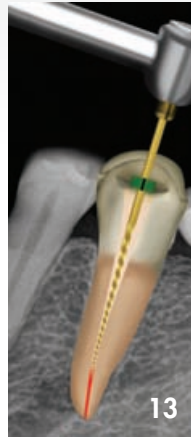
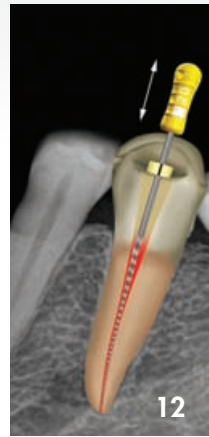Figure 12: Size 20 K-file confirmed a reproducible glide path as it could travel easily in the last 4-5 mm from and to working length without any resistance.

Figure 13: First cutting cycle with the WaveOne® Gold Medium file to 4mm short of working length.

Figure 14: Second cutting cycle with the WaveOne® Gold Medium file to working length.

and capped with a 2mm layer of Ceram.x® SphereTEC™ one composite resin (Dentsply Sirona). Figure 20 depicts the postoperative result after 6 months. A follow up CBCT scan also revealed good healing of the periapical pathology (Figure 21).

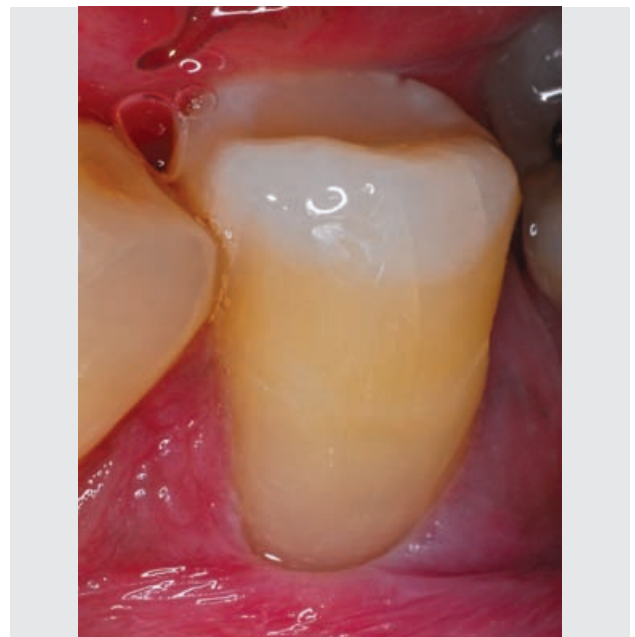


Figure 17: Postoperative view after the buccal and occlusal access cavity was restored with Ceram.x® SphereTEC™ one composite resin.

Indications for the use of the WaveOne® Gold Large file (45/05)

Any canal where a size 30 or 35 K-file fits loose in the canal it is not necessary to negotiate and prepare a glide path with smaller instruments. Root canal preparation can be initiated with the WaveOne® Large file (white ring, 45/05). This will usually include larger diameter, relatively straight root canals. This file can also be used after the Medium file if more shape is desired or if it is felt that not enough infected dentine was removed from the canal.

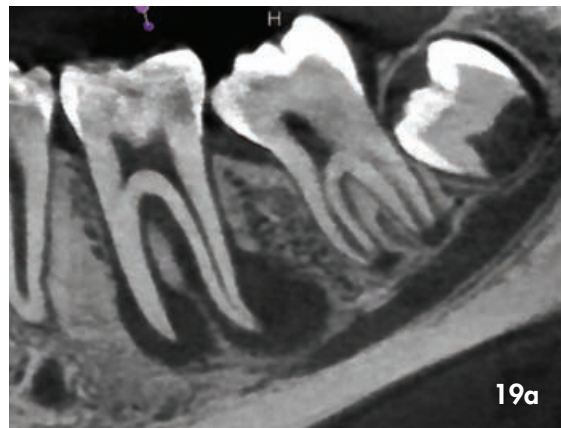
Case Report 5

The patient, a 27 year old female presented with a non-vital maxillary left canine. A size 20 K-file was used to explore the canal it was noted that the size 20 K-file felt very loose in the canal. A size 25 and 30 K-files could also be easily

taken to working length and a size 35 K-file travelled to working length with resistance. The size 30 K-file was used to determine working length (Figure 22) and confirmed a reproducible glide path in the canal as it could travel easily in the last 4-5 mm from and to working length without any resistance (Figure 23). A WaveOne® Gold Large file was selected for root canal preparation and the first cutting cycle carried the file to full working length (Figure 24), using a few backstroke brushing motions to create more lateral space. A size Large WaveOne® Gold Gutta Percha Point was fitted and checked radiographically. After irrigation, the canal was obturated and the occlusal access cavity restored with SDR®, a flowable bulk fill resin (Dentsply) and Ceram.x® SphereTEC™ one composite resin (Dentsply Sirona). Figure 25 shows a post-operative periapical radiograph after obturation and restoration of the tooth.

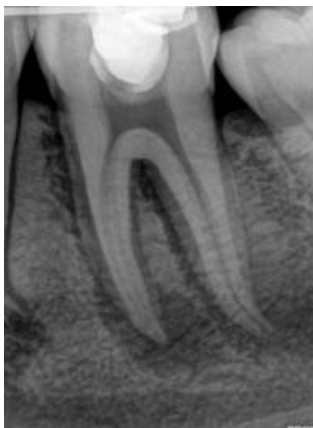

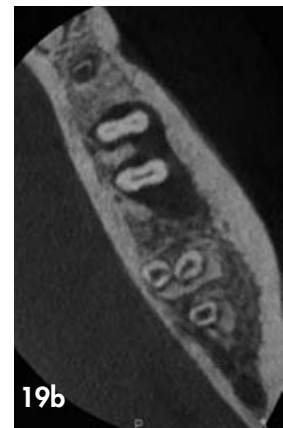Figure 18: Preoperative periapical radiograph.



19a

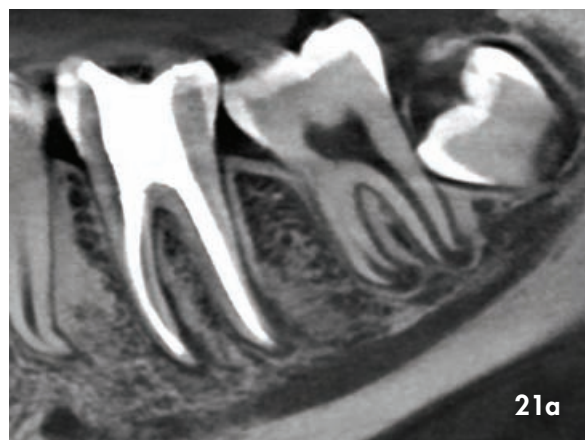


19b

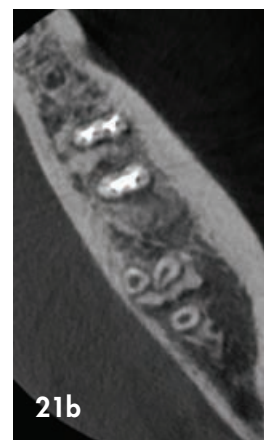
Figure 19: Preoperative CBCT scan images: (a) Axial view; (b) Sagittal view. Note the large periapical pathology around the mesial and distal roots.

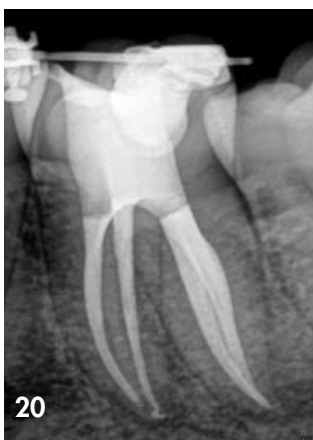

Figure 20: Postoperative periapical radiograph after 4 months.



21a



21b

Figure 21: Postoperative CBCT scan images: (a) Axial view; (b) Sagittal view. Note the healing of the periapical pathology.

Case Report 6

The patient, a 47 year old female presented with pressure sensitivity on her maxillary left lateral incisor. A periapical radiograph revealed that the tooth was previously root canal treated and obturated with a silver point before restoration with a screw-in post and core build up, followed by placement of

a porcelain crown. It was also noted that the silver point was placed 2 mm past the apex of the root canal (Figure 26).

The teeth were isolated with a split rubber dam, the porcelain crown and composite core build up material removed to expose the metal post (Figure 27). The post was ultrasonically loosened by means of vibration using a Start-X no. 3 ultrasonic tip (Dentsply Sirona). As movement was detected, the post was unscrewed by directing the vibration in an counter clockwise direction (Figure 28).

Under magnification the coronal aspect of the silver point was exposed using a straight ultrasonic tip (TFRK-S, DentalCadre) before vibration was applied to silver point itself. As movement of the silver point was detected, a size 15 Hedstrom file was carefully manipulated between the silver point and the canal wall. After the Hedstrom file progressed for approximately 5-7mm next to the silver point the file was turned clockwise to engage into the canal wall and the soft metal of the silver point. The file was pulled backwards and the silver point was retrieved from the root canal. Figures 29 and 30 show the retrieved post and silver point respectively.

A size 30 K-file was used to determine working length (Figure 31). Root canal preparation was done with a WaveOne® Gold large file. After root canal preparation, a size large WaveOne® Gold Gutta Percha Point was fitted and checked radiographically. The prepared canal was irrigated with copious amounts of heated 3.5% sodium hypochlorite and 17% EDTA before obturation (Figure 32).

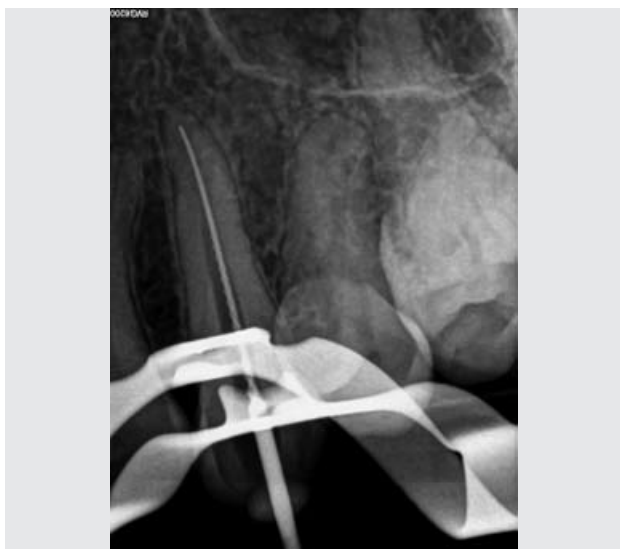

Figure 22: Length determination radiograph with a size 30 K-file.

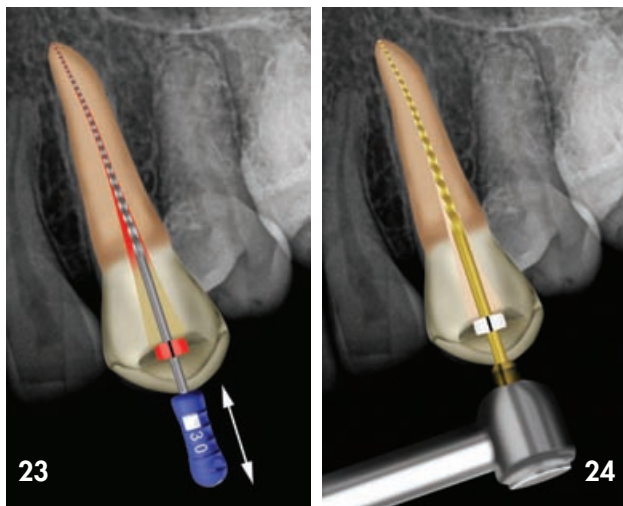


Figure 23: Size 30 K-file confirmed a reproducible glide path as it could travel easily in the last 4-5 mm from and to working length without any resistance.

Figure 24: First cutting cycle with the WaveOne® Gold Large file to working length.

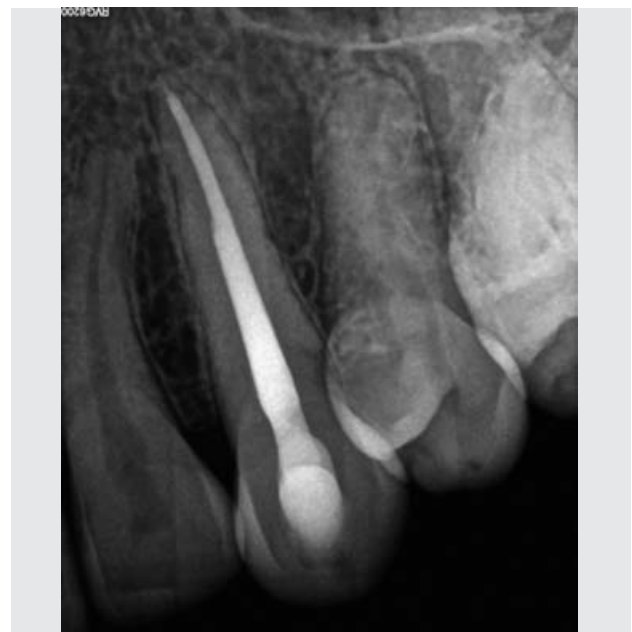

Figure 25: Postoperative periapical radiograph.

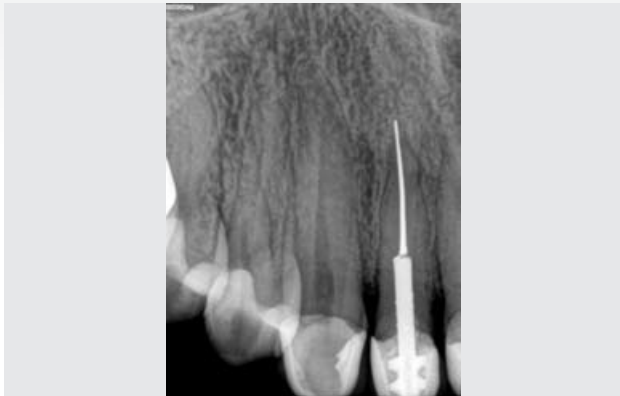

Figure 26: Preoperative periapical radiograph. Note the screw in metal post and silverpoint that was placed past the apex of the tooth.

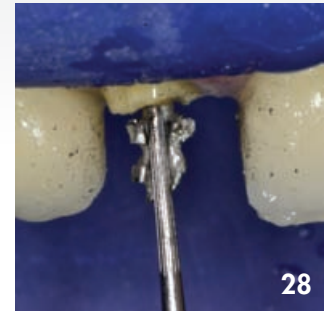
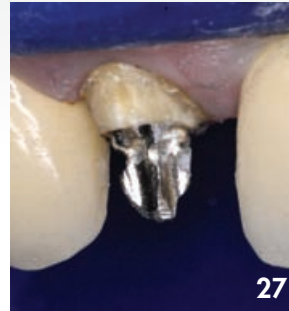

Figure 27: After rubber dam isolation, the porcelain crown and composite core build up material was removed to expose the metal post.

Figure 28: The metal post was unscrewed by means of ultrasonic vibration directed in an counter clockwise direction.



Figure 29: Metal post that was removed from the root canal.



Figure 30: Silver point that was retrieved from the root canal.

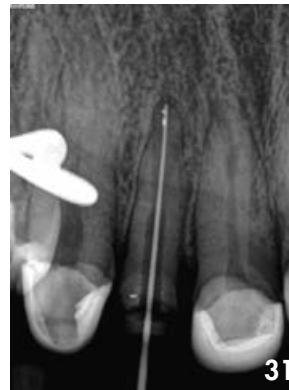

Figure 31: Length determination radiograph with a size 30 K-file.

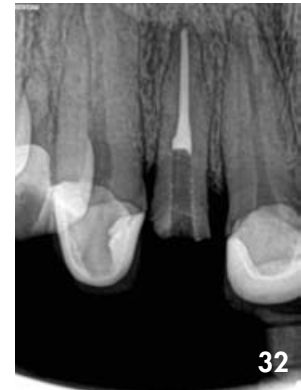

Figure 32: Postoperative periapical radiograph after obturation.

Conclusions

1. In canals with severe apical curvatures, 'S'-shaped canal configurations, very long root canals or in canals where the glide path preparation was very challenging the clinician will need two files in some cases, the Primary and Small WaveOne® Gold files to complete canal instrumentation.
2. In Larger diameter root canals the clinician will only need a single Medium or Large WaveOne® Gold file to complete canal instrumentation.

References

- Dentsply Maillefer Engineering and testing. Ballaigues, Switzerland (2014)
- Ruddle, CJ (2016) Single-file shaping technique achieving a gold medal result. Dent Today
- Van der Vyver PJ, Vorster M (2017) WaveOne® Gold reciprocating instruments: Clinical application in the private practice: Part 1. In press
- Webber, J (2015) Shaping canals with confidence: WaveOne® Gold single-file reciprocating system. Roots, 1, 34-40